



Royaume du Maroc المملكة المغربية

كلية الطب والصيدلة
FACULTÉ DE MÉDECINE ET DE PHARMACIE

Year 2018

Thesis N° 206/18

INCONTINENT URINARY DIVERSION IN CHILDREN (about 40 cases)

THESIS

SUPPORTED AND PRESENTED PUBLICLY ON 18/10/2018

BY

Mrs. ELMALKI Chaymae

Born on April 16th, 1993 in FEZ

TO OBTAIN MEDICAL DOCTORATE

KEYWORDS

Urinary diversion - Cutaneous vesicostomy- Ureterostomy-Nephrostomy-Bladder injuries-urethral injuries

JURY

Mr. BOUABDALLAH YOUSSEF.....	PRESIDENT
Professor of pediatric surgery	
Mr. KHATTALA KHALID.....	PROTRACTOR
Professor of pediatric surgery	
Mr. MELLAS Soufiane	} JUDGES
Professor of Anatomy	
Mrs. SOUILMI FATIMA ZOHRA	
Professor of Pediatrics	
Mrs. BOUBBOU MERYEM	
Professor of Radiology	

TABLE OF CONTENTS

TABLE OF CONTENTS	1
LIST OF ABBREVIATIONS	6
LIST OF FIGURES	8
LIST OF TABLES	10
LIST OF CHARTS	12
INTRODUCTION	14
MATERIALS AND METHODS	17
I. PATIENTS	18
II. STUDY FRAMEWORK	18
A. Data extraction.....	18
B. Population studied.....	18
III. RESULTS	19
STATISTICAL RESULTS	26
I. EPIDEMIOLOGICAL DATA	27
A. Distribution by age of the first consultation.....	28
B. Sex.....	28
C. Consanguinity	29
D. The geographical origin	29
E. The socio-economic level	29
F. The recruitment method	29
II. CLINICAL STUDY	30
A. Malformative uropathy.....	30
1. Backgrounds	30
a. Pregnancy:	30
b. Antenatal diagnosis:	30
c. Similar cases in the family:	30
2. The reason of consultation.....	31
3. Clinical signs	32
B. Traumatic pathology.....	33
1. The reason of consultation.....	32
2. Clinical signs	33
3. Clinical signs	33
III. BIOLOGICAL STUDY	34
A. Malformative uropathy.....	34
1. Renal function	34
2. Hydro-electrolytic disorders	35
3. Biological Infectious syndrome	35
4. Cytobacteriological examination of urine	36
B. Traumatic pathology.....	37

1. Renal function.....	37
2. Hydro–electrolytic disorders	37
3. Biological Infectious syndrome	37
4. Cytobacteriological examination of urine.....	37
IV. RADIOLOGICAL STUDY	38
A. Malformative uropathy	38
1. Renal and bladder ultrasonography	38
2. Retrograde urethrocytography	40
3. Intravenous urography	43
4. Renal scintigraphy DMSA/MAG	44
5. Computed tomography of the kidneys	45
B. Traumatic pathology.....	47
V. RETAINED DIAGNOSES	47
A. Malformative uropathy	47
B. Traumatic pathology	54
VI. THERAPEUTIC CONDUCT	54
A. Malformative uropathy.....	54
1. Medical management	54
a. Antibiotherapy:	54
b. Rehydration and correction of hydro electrolytic disorders:	55
2. Surgical management.....	55
a. The types of incontinent urinary diversion:	55
b. Cutaneous vesicostomy :	56
c. Cutaneous ureterostomy :	60
d. Nephrostomy :	63
B. Traumatic pathology	64
1. Medical management	64
2. Surgical management.....	64
VII. FOLLOW UP OF PATIENTS.....	65
A. Malformative uropathy.....	65
1. Evolution under urinary diversion	65
a. Clinical evolution :	65
b. Biological evolution :	66
c. Radiological evolution :	68
2. Complications of urinary diversion	71
a. Immediate complications :	71
b. Late complications :	71
B. Traumatic pathology.....	71
1. Evolution under urinary diversion	71

2. Complications of urinary diversion	72
DISCUSSION.....	73
I. MALFORMATIVE UROPATHY	74
A. Reminder	74
1. Pathology.....	74
a. Posterior urethral valve :.....	74
b. Megaureters :.....	78
c. Vesicoureteral reflux :.....	79
d. Double Ureter or Ureteral Duplication :.....	81
e. Neurogenic bladder :.....	83
2. Surgical technics	83
a. Cutaneous vesicostomy :.....	83
b. Cutaneous Ureterostomy :.....	85
c. Nephrostomy :.....	91
B. Diagnosis conduct in front of malformative uropathy	92
1. Antenatal diagnosis	92
2. Postnatal diagnosis	93
a. Clinical approach of MU :.....	93
b. Biological and radiological approach of malformative uropathy	94
C. Therapeutic management of malformative uropathy	99
1. Cutaneous vesicostomy.....	99
a. Achievement age :.....	99
b. Indications of cutaneous vesicostomy :.....	99
c. Closure of cutaneous vesicostomy :.....	104
d. Duration of cutaneous vesicostomy :.....	105
e. Complications of CV :.....	105
2. Cutaneous ureterostomy	107
a. Achievement age :.....	107
b. Drained side:	108
c. Types of cutaneous ureterostomy :.....	108
d. Indications of Cutaneous ureterostomy :.....	110
e. Duration of ureterostomy and age of closure:	112
f. Complications of ureterostomy :.....	113
II. TRAUMATIC PATHOLOGY	114
A. Reminder	114
1. Urethral injuries	114
a. Classification of traumatic urethral injuries:.....	114
b. Management of traumatic urethral injuries:	121
2. Bladder injuries.....	122

a. Clinical presentation and diagnosis of bladder injuries:.....	123
b. Mechanism and classification :	124
c. Complications :	127
3. Initial management	127
CONCLUSION.....	129
ABSTRACT	131
BIBLIOGRAPHY	138

LIST OF ABBREVIATIONS

ARU	Acute Retention Of Urine.
BAPU	British Association Of Pediatric Urologists.
CAKUT	Congenital Anomalies Of Kidney Urinary Tract.
CBEU	Cytobacteriological Examination Of Urine.
CIC	Clean Intermittent Catheterization.
CRF	Chronic Renal Failure.
CRP	C-Reactive Protein.
CT	Computed Tomography.
CU	Cutaneous Ureterostomy.
CV	Cutaneous Vesicostomy.
DMSA	Dimercaptosuccinic Acid.
ECU	End Cutaneous Ureterostomy.
ESRD	End Stage Renal Disease.
HUN	Hydroureteronephrosis.
IUD	Incontinent Urinary Diversion.
IVU	Intravenous Urography.
KU	Kidney Unit.
LCU	Loop Cutaneous Ureterostomy.
MU	Malformative Uropathy.
POM	Primary Obstructive Megaureter.
PUV	Posterior Urethral Valve.
RUCG	Retrograde Urethrocytography.
SB	Spina Bifida.
SIR	Society Of Interventional Radiology.

UPJ	Uretro Pelvic Junction.
URO-MRI	Urologic Magnetic Resonance Imaging.
UTD	Urinary Tract Deterioration.
UTI	Urinary Tract Infection.
VUR	Vesico Ureteral Reflux.

LIST OF FIGURES

<u>FIGURE 1.</u> BILATERAL HUN ON RENAL ULTRASOUND	39
<u>FIGURE 2.</u> GRADE V BILATERAL VUR ON RUCG	41
<u>FIGURE 3.</u> RUCG OF A 14-MONTH-OLD PATIENT WITH PUV	42
<u>FIGURE 4.</u> BLADDER WALL THICKENING ON RUCG.....	43
<u>FIGURE 5.</u> IVU SHOWS A LARGE BILATERAL UHN, EVOKING EITHER A BILATERAL MGU OR A BILATERAL VUR.	44
<u>FIGURE 6.</u> CT OF THE KIDNEYS ON A PATIENT WITH RIGHT REFLUXING MEGAURETER.	46
<u>FIGURE 7.</u> CONTROL RUCG: COMPLETE STENOSIS OF THE BULBAR URETHRA.	72
<u>FIGURE 8.</u> TYPE I PUV: SUB MONTANAL VALVES	75
<u>FIGURE 9.</u> TYPE 2 PUV: SUS-MONTANAL VALVES.....	76
<u>FIGURE 10.</u> TYPE 3 PUV: SUB-MONTANAL DIAPHRAGM	76
<u>FIGURE 11.</u> KEYHOLE SIGN	77
<u>FIGURE 12.</u> INTERNATIONAL CLASSIFICATION OF REFLUX	80
<u>FIGURE 13.</u> COMPLETE URETERAL DUPLICATION	82
<u>FIGURE 14.</u> BLOCKSOM VESICOSTOMY.....	84
<u>FIGURE 15.</u> SAGITTAL VIEW OF LAPIDES-TYPE CUTANEOUS VESICOSTOMY	84
<u>FIGURE 16.</u> SURGERY STEPS OF LOOP URETEROSTOMY:.....	86
<u>FIGURE 17.</u> SOBER URETEROSTOMY	87
<u>FIGURE 18.</u> RING URETEROSTOMY	89
<u>FIGURE 19.</u> END CUTANEOUS URETEROSTOMY	90
<u>FIGURE 20.</u> TYPE I URETHRAL INJURY.....	116
<u>FIGURE 21.</u> TYPE II URETHRAL INJURY	116
<u>FIGURE 22.</u> TYPE III URETHRAL INJURY	117

FIGURE 23. TYPE IV URETHRAL INJURY 118

FIGURE 24. TYPE IVA 119

FIGURE 25. ANTERIOR URETHRAL INJURY..... 120

LIST OF TABLES

<u>TABLE 1.</u> RESULTS OF RENO-VESICAL ULTRASOUND	38
<u>TABLE 2.</u> SUMMARY TABLE OF RETAINED DIAGNOSES OF MALFORMATIVE UROPATHY.	48
<u>TABLE 3.</u> SUMMARY TABLE OF RETAINED DIAGNOSES OF TRAUMATIC PATHOLOGY.	54
<u>TABLE 4.</u> DIAGNOSES AND NUMBER OF PATIENTS WITH CV	59
<u>TABLE 5.</u> INDICATIONS OF CUTANEOUS URETEROSTOMY	62
<u>TABLE 6.</u> CONCOMITANT INTERVENTIONS AT CLOSURE OF CUTANEOUS URETEROSTOMY	63
<u>TABLE 7.</u> PARENTAL EVALUATION OF THE CHILDREN'S GENERAL HEALTH BEFORE AND DURING URINARY DIVERSION.	66
<u>TABLE 8.</u> COMPARISON OF PATIENTS WITH ANTENATAL DIAGNOSIS BETWEEN OUR SERIES AND SERIES OF LITERATURE.	93
<u>TABLE 9.</u> COMPARISON OF PATIENTS WITH UTIS	94
<u>TABLE 10.</u> COMPARISON OF PERCENTAGE OF PATIENTS HAVING FEVER.....	94
<u>TABLE 11.</u> COMPARISON OF PERCENTAGE OF ACHIEVING RENO-VESICAL US	95
<u>TABLE 12.</u> COMPARISON OF THE RESULTS OF THE RUCG BETWEEN OUR SERIES AND THE SERIES OF LITERATURE.	97
<u>TABLE 13.</u> TABLE COMPARING THE DIAGNOSES FOUND IN OUR SERIES WITH THE SERIES OF LITERATURE.....	98
<u>TABLE 14.</u> COMPARISON OF THE PATIENT'S AGE AT THE TIME OF THE REALIZATION OF THE VESICOSTOMY.	99
<u>TABLE 15.</u> COMPARISON OF CV INDICATIONS.....	100
<u>TABLE 16.</u> COMPARISON OF PATIENTS WITH PUV TREATED WITH VESICOSTOMY OR PRIMARY VALVE ABLATION.	102

<u>TABLE 17.</u> COMPARISON OF PATIENTS WITH NEUROGENIC BLADDER/SB TREATED WITH VESICOSTOMY.	103
<u>TABLE 18.</u> COMPARISON OF PATIENTS WITH CLOSURE VESICOSTOMY	104
<u>TABLE 19.</u> COMPARISON OF DURATION OF CV IN PATIENTS.....	105
<u>TABLE 20.</u> COMPARISON OF COMPLICATIONS OF VESICOSTOMY WITH DIFFERENT SERIES.	106
<u>TABLE 21.</u> TABLE COMPARING THE AGE OF PATIENTS AT THE TIME OF ACHIEVING URETEROSTOMY	107
<u>TABLE 22.</u> TABLE COMPARING THE DRAINED SIDES.....	108
<u>TABLE 23.</u> TABLE COMPARING TYPES OF URETEROSTOMY	109
<u>TABLE 24.</u> COMPARATIVE TABLE OF INDICATIONS OF URETEROSTOMY.....	111
<u>TABLE 25.</u> COMPARISON OF DURATIONS OF URETEROSTOMY AND AGE AT CLOSURE.	112
<u>TABLE 26.</u> COMPARISON OF COMPLICATIONS OF URETEROSTOMY	113
<u>TABLE 27.</u> OBSERVATIONS OF PATIENTS WITH TRAUMATIC URETHRAL AND BLADDER.....	126

LIST OF CHARTS

<u>CHART 1.</u> DISTRIBUTION OF PATIENTS BY AGE GROUP.	27
<u>CHART 2.</u> DISTRIBUTION OF PATIENTS ACCORDING TO SEX.	28
<u>CHART 3.</u> DISTRIBUTION OF PATIENTS ACCORDING TO CONSANGUINITY.....	29
<u>CHART 4.</u> DISTRIBUTION OF MOTHER'S PATIENTS ACCORDING PREGNANCY MONITORING.....	30
<u>CHART 5.</u> DISTRIBUTION OF PATIENTS ACCORDING SIMILAR CASES IN FAMILY.	31
<u>CHART 6.</u> DISTRIBUTION OF PATIENTS ACCORDING TO THEIR REASONS FOR CONSULTATION.....	31
<u>CHART 7.</u> DISTRIBUTION OF PATIENTS ACCORDING CLINICAL SIGNS	32
<u>CHART 8.</u> DISTRIBUTION OF PATIENTS ACCORDING TO SERUM UREA LEVEL.	34
<u>CHART 9.</u> DISTRIBUTION OF PATIENTS ACCORDING THE SERUM CREATININE VALUE	35
<u>CHART 10.</u> GERMS FOUND ON CBEU.....	36
<u>CHART 11.</u> TOPOGRAPHY OF VUR ON RUCG.....	40
<u>CHART 12.</u> DISTRIBUTION OF PATIENTS ACCORDING ANTIBIOTHERAPY.....	54
<u>CHART 13.</u> THE TYPES OF INCONTINENT URINARY DIVERSION IN PATIENTS <i>WITH MU</i>	55
<u>CHART 14.</u> DISTRIBUTION OF PATIENTS ACCORDING CV.....	56
<u>CHART 15.</u> DISTRIBUTION OF PATIENTS ACCORDING TO ACHIEVEMENT AGE OF CV.	57
<u>CHART 16.</u> DISTRIBUTION OF PATIENTS WITH CLOSURE CV.....	57
<u>CHART 17.</u> DISTRIBUTION OF PATIENTS STAYS WITH OPEN CV UNTIL 31/12/2017.	58
<u>CHART 18.</u> DISTRIBUTION OF PATIENTS ACCORDING THE AGE OF REALIZATION OF URETEROSTOMY	60
<u>CHART 19.</u> DISTRIBUTION OF PATIENTS ACCORDING THE DURATION OF URETEROSTOMY.	61

CHART 20. EVOLUTION OF SERUM CREATININE VALUES DURING URINARY DIVERSION 67

CHART 21. THE MOST RESPONSIBLE GERMS OF RECURRENT URINARY TRACT INFECTIONS..... 68

CHART 22. DISTRIBUTION OF PATIENTS ACCORDING TO THE EVOLUTION OF THE UHN UNDER IUD. 69

INTRODUCTION

Urinary diversion is defined as the surgical diversion of urine from the urinary tract.

The primary indication for surgical invention and urinary diversion in paediatric patients is the preservation of renal function and prevention of upper tract deterioration secondary to a hostile lower urinary tract [1].

This kind of surgery can be subdivided into 2 categories: continent and incontinent [1].

WITH Continent urinary diversion, the urinary reservoir is emptied by CIC; this allows for urinary dryness or “continence.” Classically, a reservoir made entirely of gastrointestinal segments is referred to as a continent urinary reservoir. This procedure is less commonly used in paediatric patients, however, because most diagnoses that require urinary reconstruction do not necessitate cystectomy [2].

Incontinent urinary diversion allows for the free flow of urine outside of the body; urine can be collected into either a diaper or an external ostomy device. It is an extremely valuable tool for the protection of the upper urinary tract because it is a very effective means of reducing elevated intravesical and intrarenal storage pressures. There are numerous means of achieving this, and complexity ranges from a temporary urethral catheter to a permanent incontinent ileovesicostomy.

Incontinent urinary diversion can be performed at all levels in the urinary tract:

- Kidney: Percutaneous nephrostomy.
- Ureter: Cutaneous ureterostomy.
- Bladder: Cutaneous vesicostomy.

The simple and rapid realization of these urinary diversion should not estimate their risks and complications, hence the need to ask the right indication and advocate regular monitoring.

The aim of this thesis is to justify the interest and importance of urinary tract

diversions in malformative uropathy, and traumatic pathology.

Problematic

Incontinent urinary diversion is an emergency treatment, remains the problem of subsequent management especially for ureterostomy that pose difficulty in reprise.

MATERIALS AND METHODS

I. PATIENTS

All patients who have incur incontinent urinary diversion, from January 1st, 2013 to December 31st, 2017 (4 years) were eligible.

Number: 40 patients.

II. STUDY FRAMEWORK

Data have been collected from the department of Pediatric surgery in HASSAN II University Hospital–FEZ.

This study is a retrospective, descriptive, involving cases who did an incontinent urinary diversion from January 2013 to December 2017.

A. Data extraction

Data have been collected from:

–Archived medical records of hospitalized patients in the department of Pediatric surgery in HASSAN II University Hospital–FEZ.

–A computer search of cases was achieved on the data collection system "HOSIX" using patient's identification.

–Register of the pediatric surgery operating room.

–Medical records of patients who were followed at the nephrology unit of pediatric department.

At the same time, a questionnaire on the experience of the family before and during incontinent urinary diversion is established and completed by the families at the appointment of consultation or by telephone contact.

B. Population studied

➤ Inclusion criteria:

All cases with malformative uropathy or traumatic pathology who underwent incontinent urinary diversion and hospitalized in the department of pediatric surgery

were included.

➤ Exclusion criteria:

Patients whose files were lost or incomplete were excluded.

Patients followed for a tumor pathology who underwent an incontinent urinary diversion.

III. RESULTS

All patients data were coded and imported into MS Excel®2013 worksheets.

EXPLOITATION SHEET❖ **Identity:**

- First and last name:
- Sex:
- Phone number:
- Age of first consultation: months
- Consanguinity: yes/no

❖ **Antecedent:**

- Pregnancy: followed / not followed
- Similar cases in family: yes / no

❖ **Diagnosis:**

- Antenatal diagnosis:
- Antenatal ultrasound: yes / no
- Gestational Age:
- Result:

❖ **Reason for consultation:**

- First episode of urinary tract infection:
- Several episode of urinary tract infections:
- Acute urinary retention:
- Abdominal distension:
- Followed chronic renal failure:
- Others:

❖ **Clinique:**

- | | | |
|-------------------|-------------|-------------------------|
| - Fever: | - Burning: | - Pyuria: |
| - Diarrheic: | - Vomiting: | |
| - Abdominal pain: | - Lumbago | - Abdominal distension: |

+ CT urography: done / not done

- Results:

+ URO-MRI: done / not done

-Results:

+ Renal scintigraphy: done / not done

-Technique: DMSA / MAG3

-Results:

❖ **Therapeutic management:**

+Medical management :

-Antibiotic: yes / no

molecules:

-Prophylactic antibiotic: yes / no

molecules:

+Surgical management:

Cutaneous vesicostomy:

- Achievement age: months

- Closure of vesicostomy: - deadlines after CV:

Cutaneous ureterostomy:

- Unilateral / Bilateral

- Achievement age: months

- Surgical technique:

- Closure of ureterostomy: -deadlines after ureterostomy:

- Ureteral reimplantation:

-Achievement age: months

-Technic:

-Nephrectomy:

-Other gestures:

Nephrostomy:

-Unilateral / Bilateral

-Achievement age: months

Concomitant repair gesture at closing:

❖ Follow up of patients:

+Post-operative complications:

- Post obstructive diuresis: yes / no

- Stenosis: yes / no delay:

- Prolapse: yes / no delay:

- Fistula: yes / no delay:

- Others:

+Biology:

➤ Recurrent UTI:

-Number:

-Germs:

➤ Renal function:

Date				
Urea				
Creatinine				

+Radiology:

➤ Ultrasonography:

Date				
Result				

➤ Renal scintigraphy (DTPA / DMSA):

Date		
Technic		
Results		

➤ RUCG:

Date		
Results		

+Questionnaire on the experience of families:

➤ Clinical evolution: before and during incontinent urinary diversion.

	Ordinary	Particular
Orifice care		
Hygiene measures		
Clothing changes		

➤ Orifice management:

	Before IUD					During IUD				
	1	2	3	4	5	1	2	3	4	5
Nourishment										
Weight										
Rest										
Activities										

1

1: Very altered

2: Altered

3: Medium

4: Pretty good

5: Good

STATISTICAL RESULTS

I. EPIDEMIOLOGICAL DATA

A. Distribution by age of the first consultation

The age of our patients at the first consultation varied between 1 day of life and 14 years, which is a minimum of 1 day and a maximum of 168 months.

We divided our patients according to age groups (Chart 1).

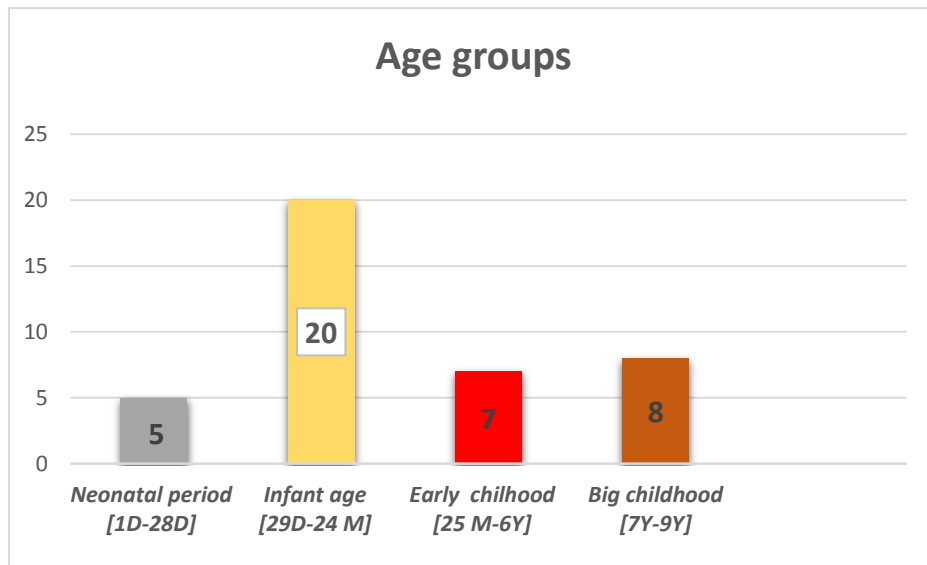


Chart 1. Distribution of patients by age groups.

B. Sex

In our series, 35 patients are boys (88%) and 5 are girls (12%). A masculine predominance is noted (Chart 2).

The sex ratio is 7.

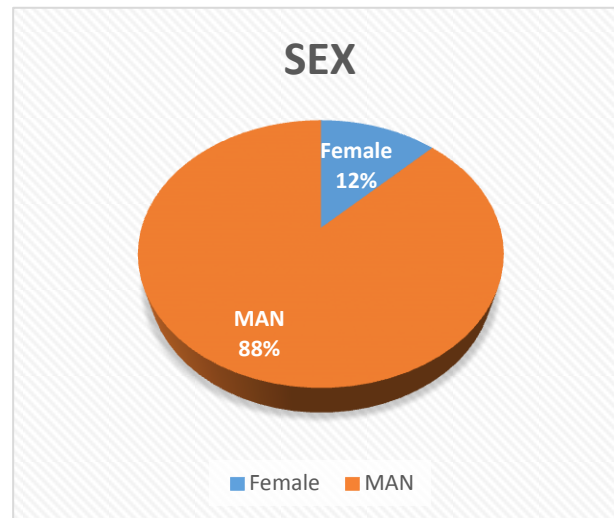


Chart 2. Distribution of patients according to sex.

C. Consanguinity

Eleven children have a notion of parental consanguinity:

–1st degree in 6 children.

–2nd degree in 5 children.

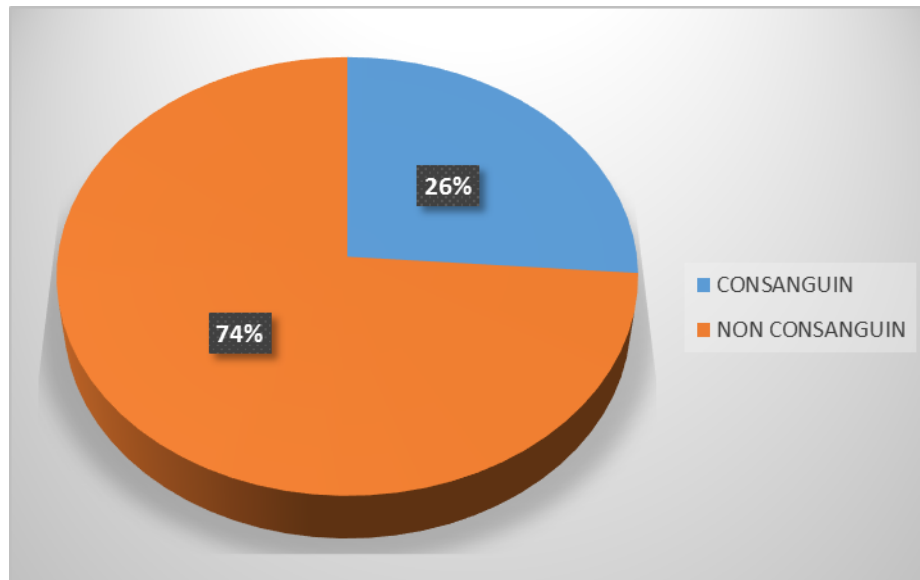


Chart 3. Distribution of patients according to consanguinity.

D. The geographical origin

Most patients in our study are from FEZ city and the Taounate region.

E. The socio-economic level

Families of low socioeconomic level are predominant, with a percentage of 74% versus 26% for families of average socio-economic level.

F. The recruitment method

Twenty-three patients were transferred to the pediatric surgery department: ten from the pediatric department and two from the neonatology department. Other patients were referred to pediatric emergencies either from a provincial hospital center or from a private doctor (pediatrician, urologist, general practitioner).

II. CLINICAL STUDY

A. Malformative uropathy

1. Backgrounds

a. Pregnancy:

The mothers of only 5 patients were followed by pregnancy monitoring with a gynecologist while 18 were followed only in health center (Chart 4).

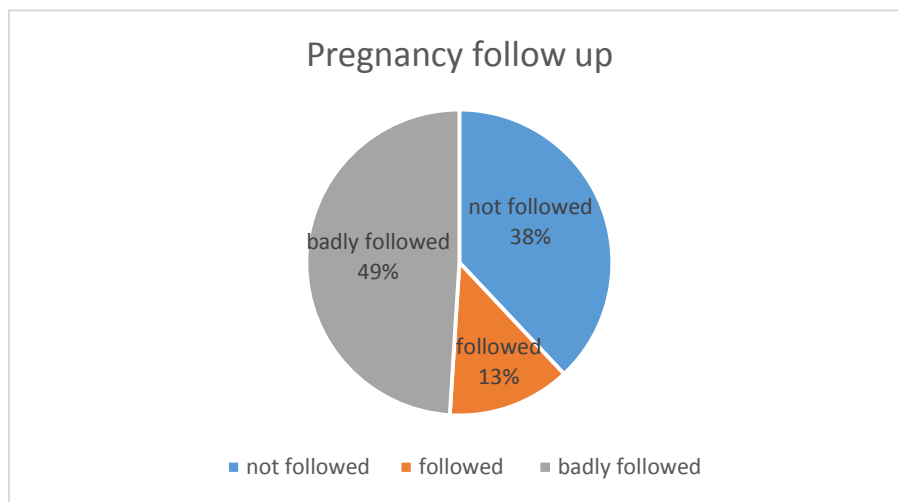


Chart 4. Distribution of mother's patients according pregnancy monitoring.

b. Antenatal diagnosis:

During pregnancy follow-up, the diagnosis of MU was suspected in only 5 patients (13% of cases).

Those patients have been diagnosed with multiple bilateral renal cysts and HUN at the 2nd and 3rd trimester of pregnancy.

c. Similar cases in the family:

A malformative uropathy is found in only 1 case (3% of cases).

One patient with a posterior urethral valve, in whom the older brother is operated on for PUV with secondary refluxing Megaureters (Chart 5).

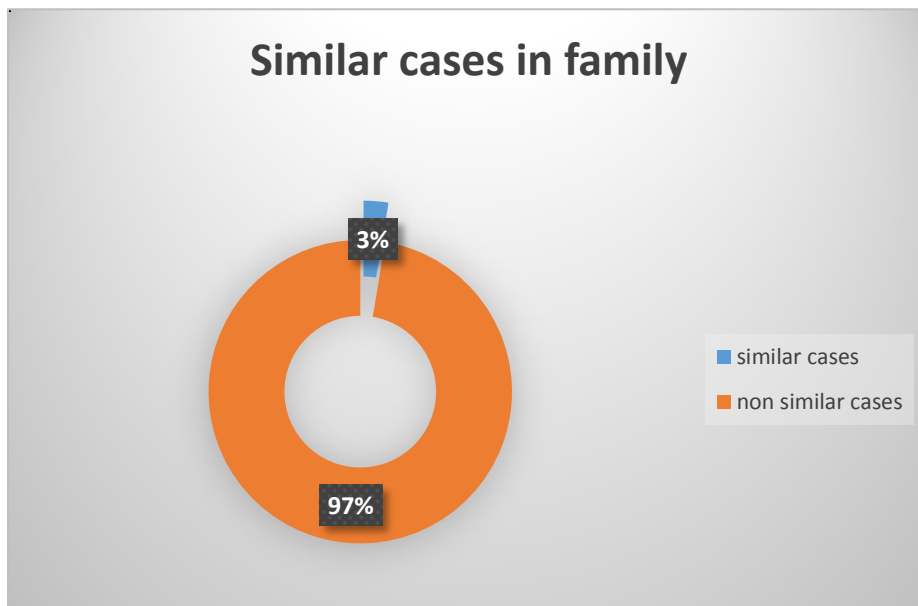


Chart 5. Distribution of patients according similar cases in family.

2. The reason of consultation

In our series, the urinary tract infection is the most frequent sign of revelation of MU at 27 cases, either as first episode in 12 patients (32.5% of cases), or after several episodes in 14 patients (40.5% of cases).

Abdominal distention in 3 patients (8%), acute retention of urine in 5 patients (13.5% of cases) and chronic renal failure in 2 patients (5.5% of cases).

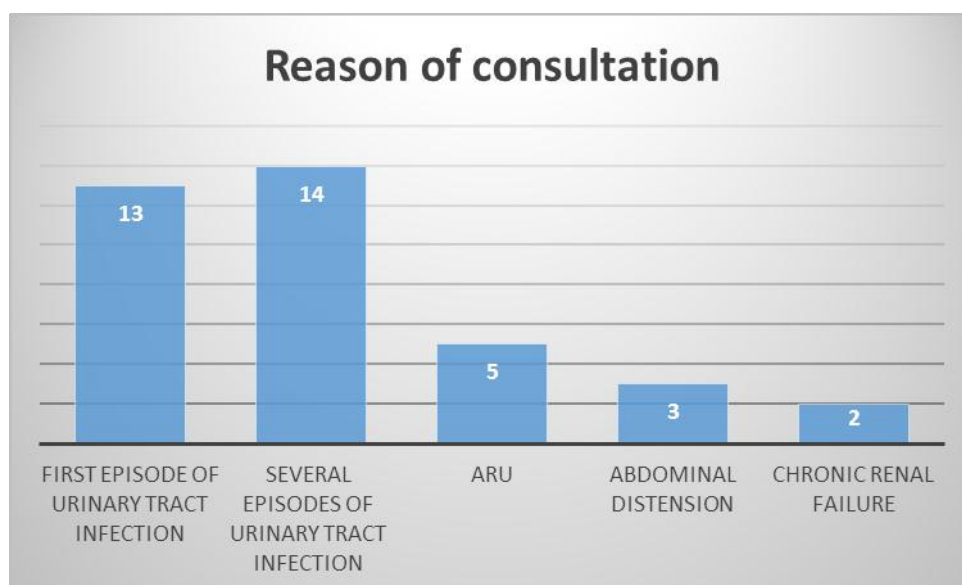


Chart 6. Distribution of patients according to their reasons for consultation.

3. Clinical signs

Infectious signs were in the first plan (fever), followed by urinary signs (urinary flow disorder, clinical distended bladder, oliguria), then the abdominal signs (abdominal distension, abdominal pain) followed by general signs (deterioration of general condition, dehydration, undernutrition, growth retardation) (Chart 7).

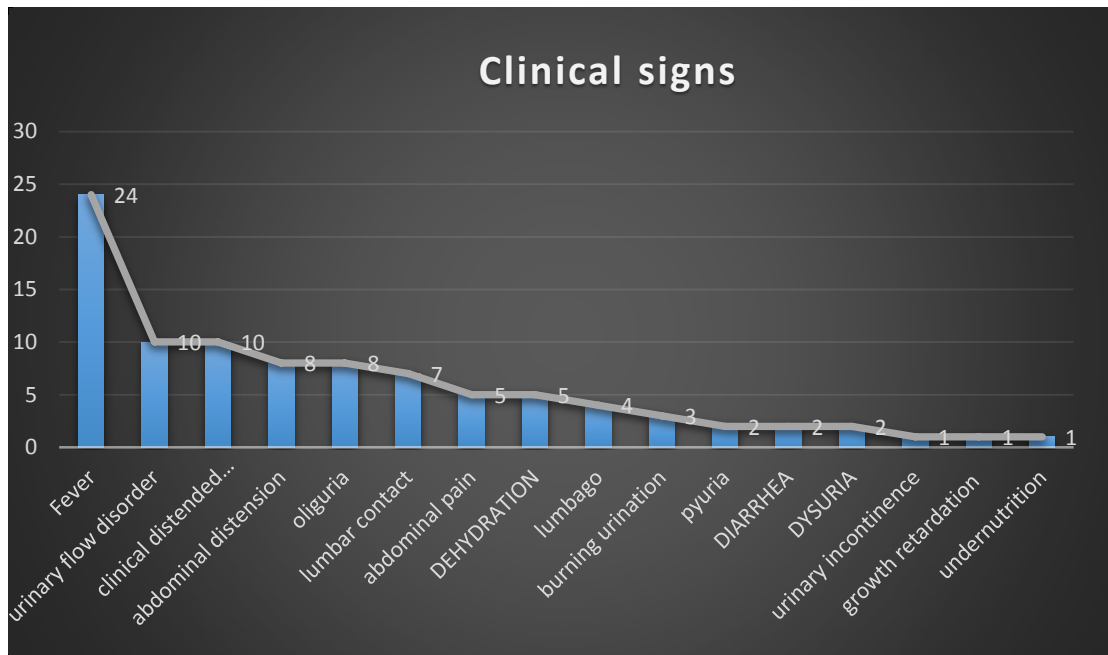


Chart 7. Distribution of patients according clinical signs.

B. Traumatic pathology**1. The reason of consultation:**

3 male children with urethral and bladder trauma caused by motor vehicles accidents were admitted urgently.

2. Clinical signs:

The 3 patients were received with an acute urine retention.

3. Clinical signs:

The 3 patients came in a table of acute urine retention made of abdominal pain and clinical distended bladder.

III. BIOLOGICAL STUDY

A. Malformative uropathy

1. Renal function

Renal function was assessed by serum urea and creatinine, interpreted according to age and sex.

- ❖ Serum urea values ranged from 0.14g / l to 3.85g / l. Before the urinary diversion, 20 patients had a high serum urea (54% of cases), and 17 had a normal urea (46% of cases) (Chart 8).

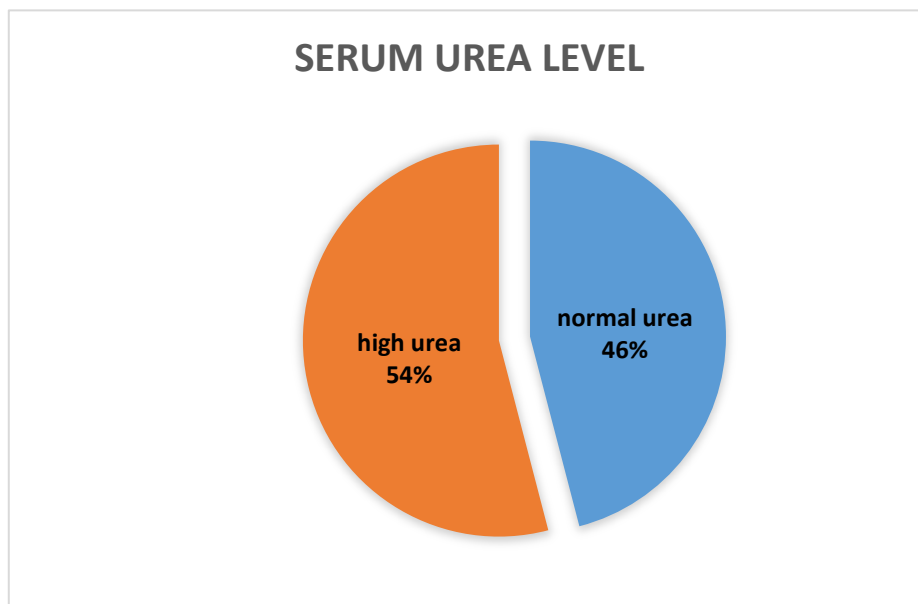


Chart 8. Distribution of patients according to serum urea level.

- ❖ Serum Creatinine values ranged from 3 to 161 mg / l. 16 children had high serum creatinine (43% of cases), two of which were followed for renal failure (pre-terminal and terminal) at pediatric department before performing the urinary diversion (Chart9).

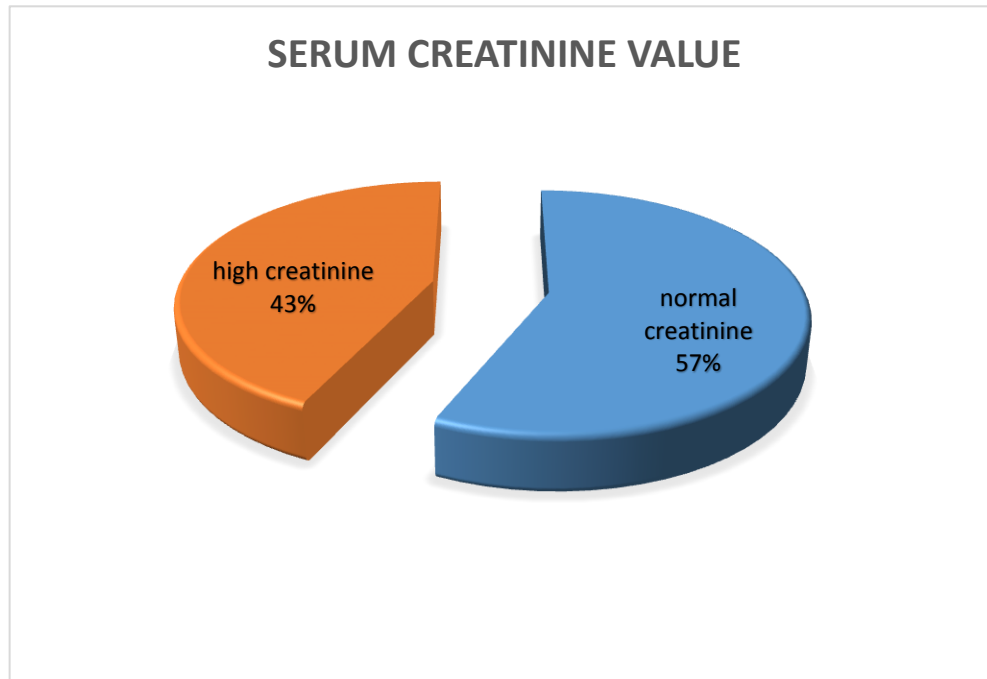


Chart 9. Distribution of patients according the serum creatinine value.

2. Hydro-electrolytic disorders

Few patients had hydro-electrolytic disorders:

- Hyperkalemia in 7 patients (19% of cases).
- Hyponatremia in 10 patients (27% of cases).

3. biological Infectious syndrome

From the 29 children with clinical signs of infection, high biological markers (leukocytosis and CRP levels) are found in 23 patients (54% of cases).

CRP ranged from 18 to 286 mg / l and leukocytes ranged from 10700 to 160000 ele/ml before performing the urinary diversion.

4. Cytobacteriological examination of urine

CBEU was done in 30 patients:

- The culture was negative in 9 patients, positive in 20 patients: *Escherichia coli* (54% of cases), *Klebsiella pneumoniae* (16.21%) comes in the first plane, then in descending order: *Pseudomonas aeruginosa*, *Staphylococcus aureus* and *Candida albicans*.
- The 1 remaining patient had a polymorphic culture.

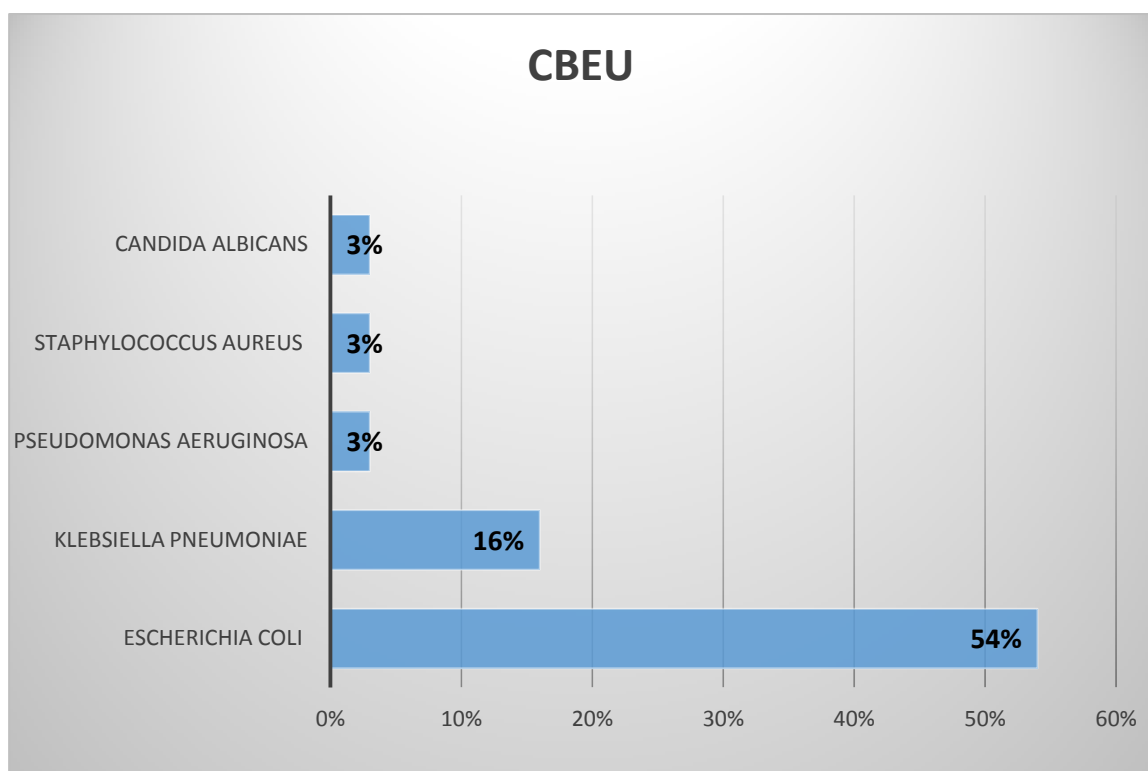


Chart 10. Germs found on CBEU.

B. Traumatic pathology

1. Renal function

Renal function was assessed by serum urea and creatinine, interpreted according to age and sex.

The 3 patients had a correct renal function.

2. Hydroelectrolytic disorders

No patient had an hydroelectrolytic disorders.

3. biological Infectious syndrome

From the three children, high biological markers (leukocytosis and CRP levels) are found in 2 patients.

CRP ranged from 18 to 44 mg / l and leukocytes ranged from 10910 to 11620 ele/ml at pediatric department before performing the urinary diversion.

4. Cytobacteriological examination of urine

CBEU was done in 1 patient and its culture was negative.

IV. RADIOLOGICAL STUDY

A. Malformative uropathy

1. Renal and bladder ultrasonography

The reno-vesical ultrasound was performed in all patients (100% of cases). It was indicated for infectious urinary or abdominal symptoms (Table 1).

In the 37 patients whether 74 kidney units.

The hydroureteronephrosis was bilateral in 32 patients (87%), unilateral in 5 patients: right in 4 patients (10.5%) and left in 1 patient (2.5%) (Figure1).

The diameter of the dilated upper excretory cavities and renal parenchyma is not always mentioned on the ultrasound reports.

The renal parenchyma is preserved on 14 KU. It is reduced on 20 KU and laminated on 40 KU.

Pyonephrosis was present in 2 patients (5% of cases).

The exploration of the bladder has objectified a bladder wall enlargement in 17 patients (46% of cases), normal in 6 patients (16% of cases), for the rest of patients, the bladder was difficult to characterize given the present of bladder catheter.

Table 1. Results of reno-vesical ultrasound.

		Patients	Percentage
HUN	Unilateral	5	13%
	Bilateral	32	87%
Pyonephrosis		2	5%
Bladder wall enlargement		17	46%

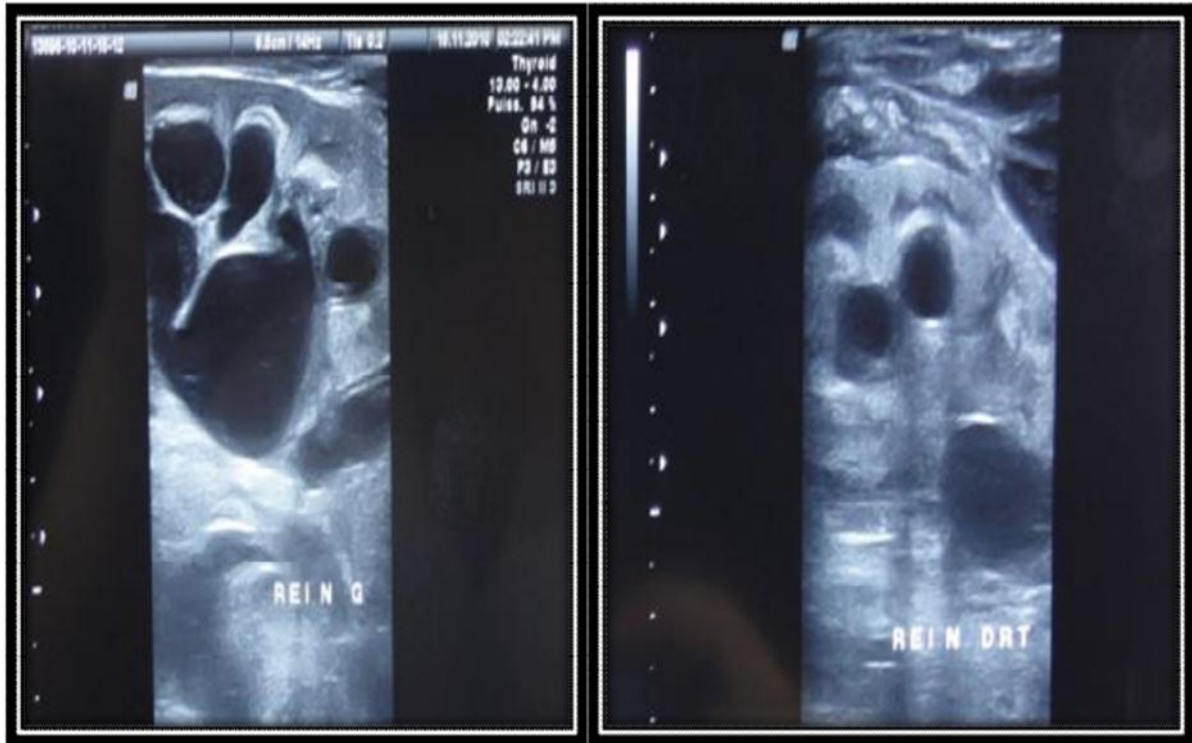

Figure1. Bilateral HUN on renal ultrasound.
[Department of paediatric surgery, CHU Hassan II, FEZ]

2. Retrograde urethrocytography

The RUCG was performed in 26 patients before the realization of incontinent urinary diversion.

A VUR is found on 17 patients (45.9% of cases). It is bilateral in 8 cases (21.6% of cases), unilateral (24.3% of cases): Right in 6 patients (16.2% of cases) and Left in 3 patients (8.1% of cases) with a slight predominance of the right side (Chart 11).

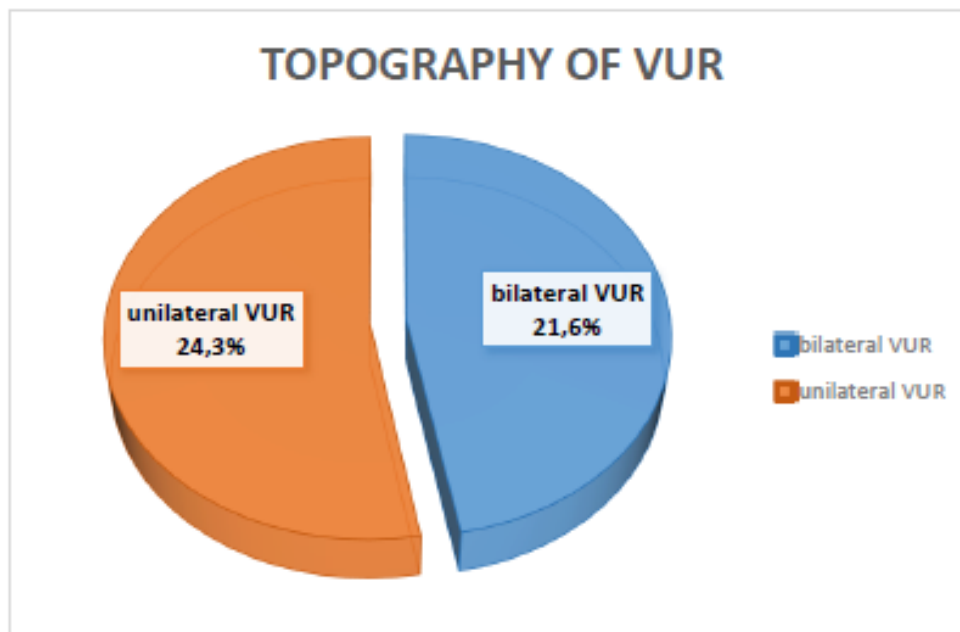


Chart 11. Topography of VUR on RUCG.

Grade: In our series, the total number of refluxing ureters is 25. The majority of VUR is high grade 59% (IV; V) versus 41% of low grade (I, II; III) (Figure 2).

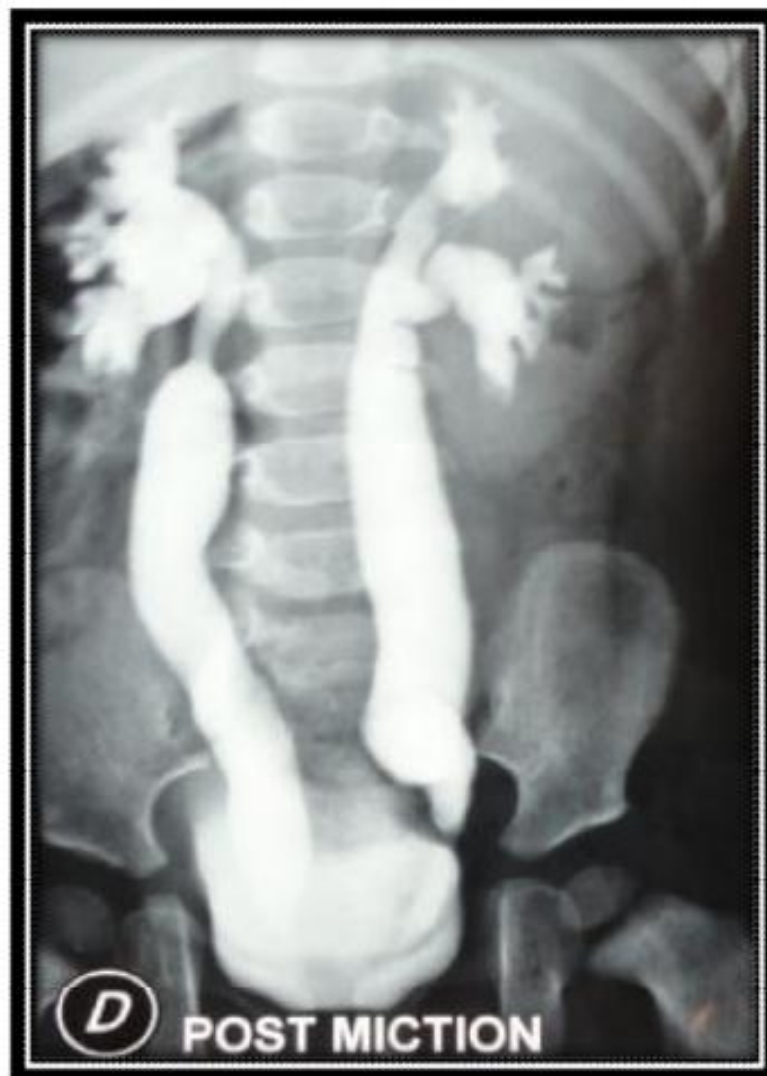

Figure 2. Grade V bilateral VUR on RUCG.
(Department of pediatric surgery Hassan II FEZ)

Mechanism: has been specified in 11 RUCG: 8 times passive, once active and 2 times mixed.

Other abnormalities: The RUCG has identified in our patients other abnormalities associated with VUR: 5 cases of PUV (13.5% of cases) (Figure 3).

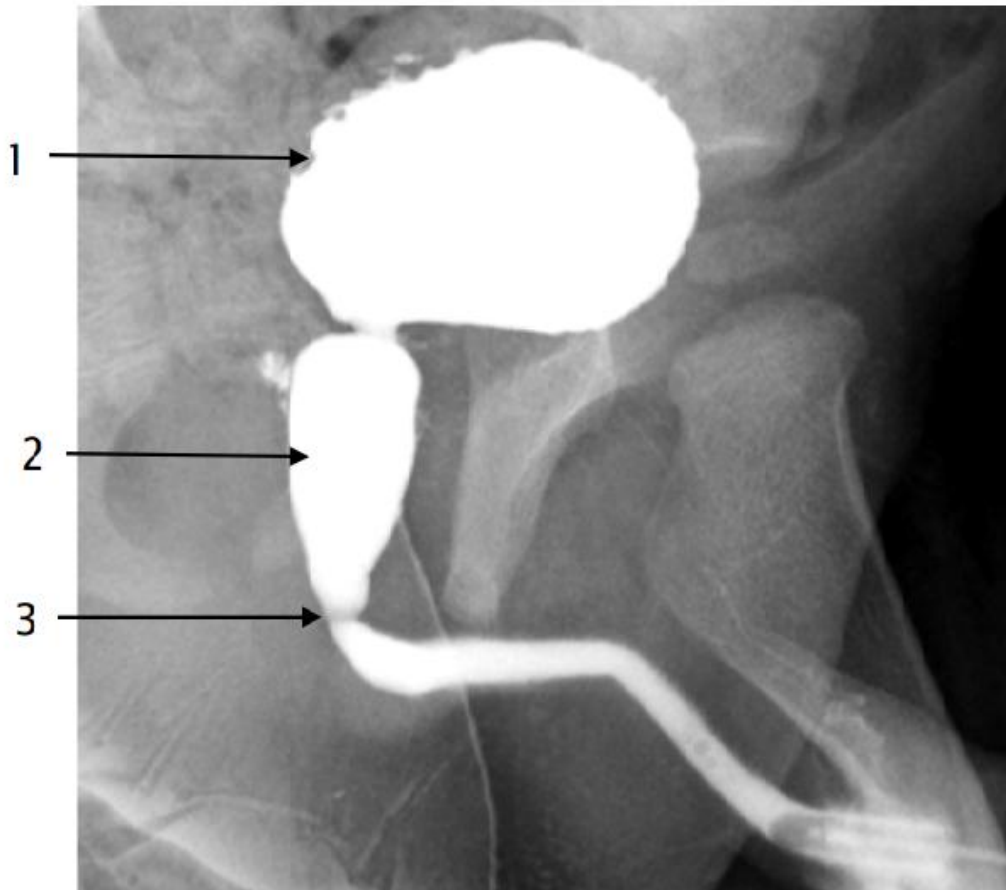


Figure 3. RUCG of a 14-month-old patient with PUV.

(Permittional urethrocytography)

1. Diverticular bladder.
2. Dilation of the prostatic urethra.
3. Stenosis image at the junction bulbo-prostatic.

RUCG showed also a bladder wall thickening in 9 patients (24.3% of cases) (Figure 4).

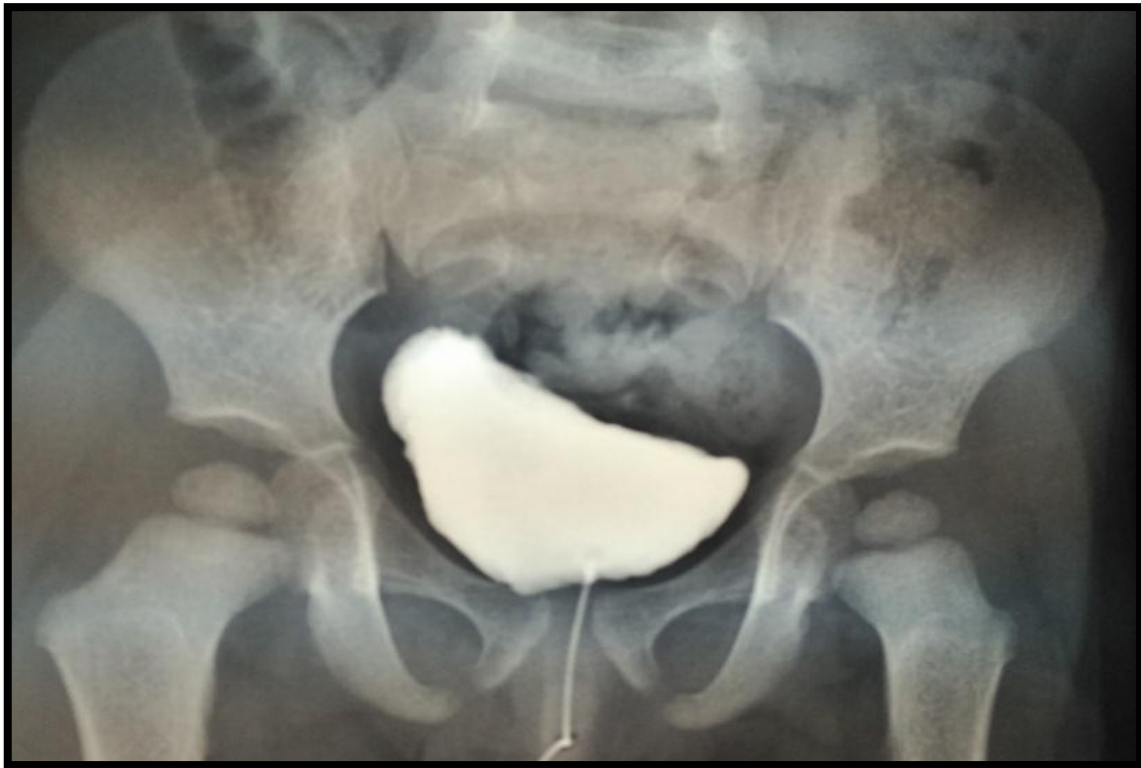


Figure 4. Bladder wall thickening on RUCG.

(Department of pediatric surgery Hassan II FEZ)

3. Intravenous urography

IVU is performed in 4 patients. He objectified:

- Patient 1: Significant bilateral hydroureteronephrosis without visible distal ureteral stenosis.
- Patient 2: Significant bilateral hydroureteronephrosis recalls either a bilateral megaureter or a bilateral VUR (Figure 5).
- Patient 3: Small right kidney with radiopaque dilation of the pyelon and small left renal lithiasis.
- Patient 4: Left urinary tree fills up progressively in connection with left VUR.

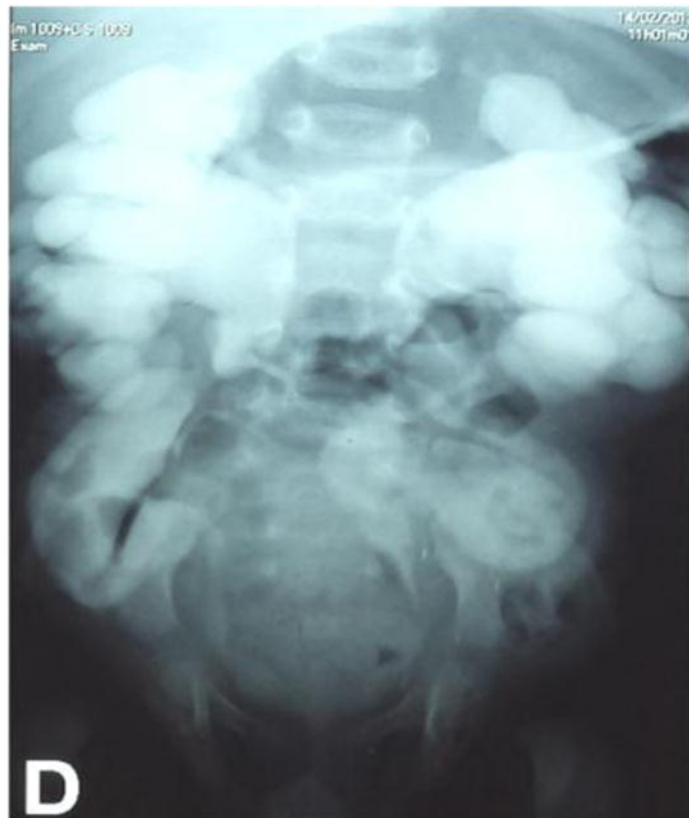


Figure 5. IVU shows a large bilateral UHN, evoking either a bilateral MGU or a bilateral VUR.

(Department of pediatric surgery Hassan II FEZ)

4. Renal scintigraphy: DMSA/MAG

Due to the unavailability of this examination initially, most of patients received renal scintigraphy only after the completion of urinary diversion.

- 7 patients received this examination before the urinary diversion (4 with DMSA+ 3 with MAG):

2 patients had a unilateral mute kidney associated with either urinary infection lesions to either a stasis nephrogram. The 5 remaining patients had an asymmetric distribution of relative renal function between the 2 kidneys with right and left stasis nephrograms.

5. Computed tomography of the kidneys

CT is done to only one patient, objectify a significant right ureterohydronephrosis with a dystrophic left kidney (Figure 6).

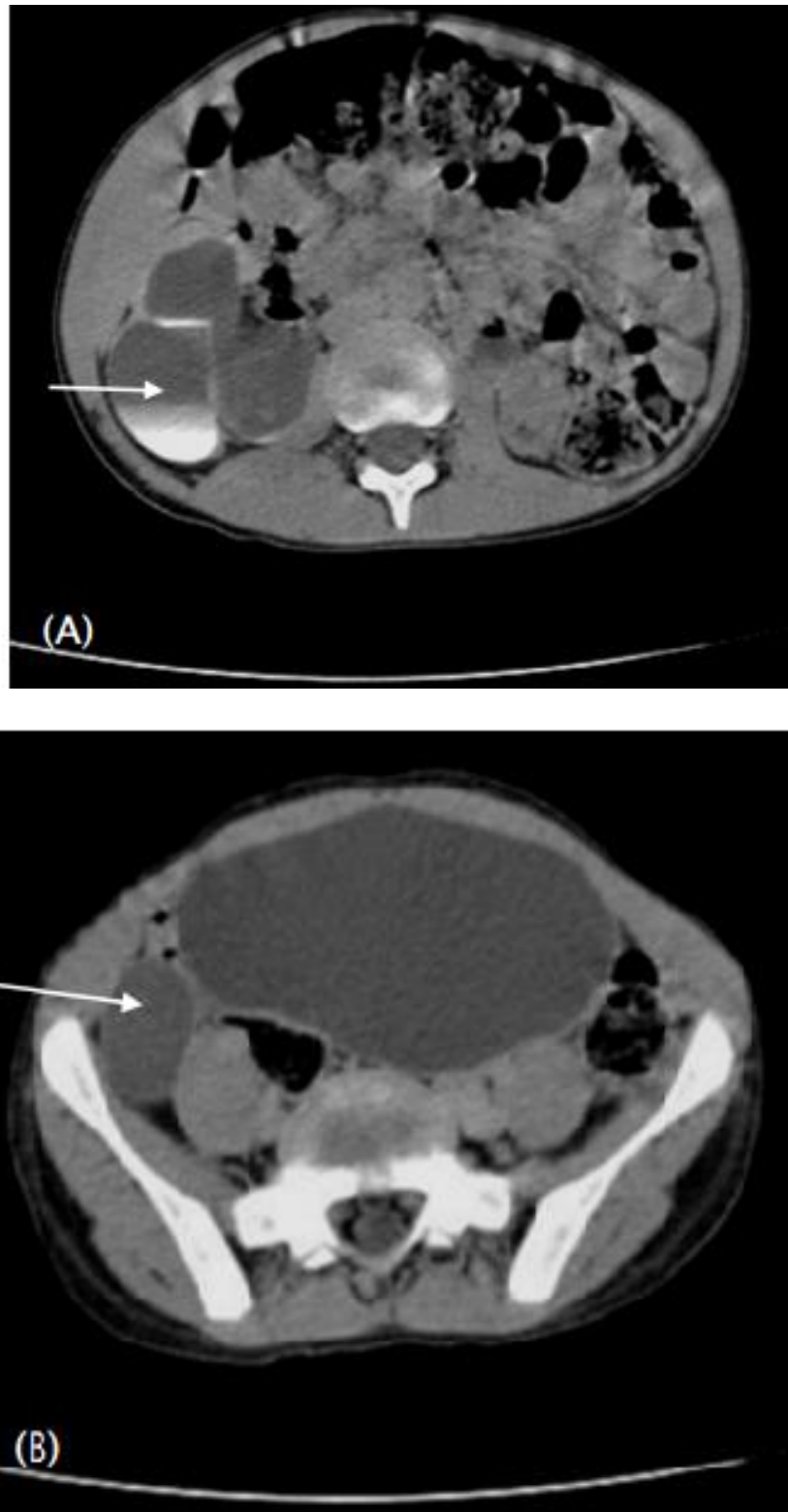


Figure 6. CT of the kidneys on a patient with right refluxing megaureter.

- A. Late time shows a level in favor of delayed urine progression the left kidney is dystrophic.
- B. Dilation of the pelvic ureter.

B. Traumatic pathology

No patient incurs radiological examination at admission.

V. RETAINED DIAGNOSES**A. Malformative uropathy**

At the end of the radiological exams, these diagnoses were retained (Table 2):

- 17 patients with PUV.
- 10 patients with refluxing megaureters.
- 8 patients with neurogenic bladder.
- 1 patient with urethral polyp.
- 1 patient with left megaureter and right ureteropelvic junction obstruction.

Table 2. Summary table of retained diagnoses of malformative uropathy.

Patient	Ultrasonography	UCGR	IVU	URO-CT	DIAGNOSIS
<u>P1</u>	Right hydronephrosis with left pyonephrosis and bladder wall thickening	VUR grade 4 + diverticular bladder	-	-	Right ureteropelvic junction obstruction + Left refluxing megaureter.
<u>P2</u>	Left unilateral HUN laminating renal parenchyma / Single kidney	Left VUR grade 4	-	-	Left refluxing megaureter on single congenital kidney
<u>P3</u>	Bilateral HUN laminating renal parenchyma	Bilateral VUR grade 4	-	-	Refluxing Megaureters
<u>P4</u>	Bilateral HUN	Bilateral VUR grade 1	Bilateral UHN without urethral stenosis	-	Refluxing Megaureters
<u>P5</u>	Bilateral HUN reducing renal parenchyma with	PUV + diverticular bladder	-	-	PUV

	bladder wall thickening				
<u>P6</u>	Bilateral HUN reducing renal parenchyma with bladder wall thickening	PUV +diverticular bladder	-	-	PUV
<u>P7</u>	Right unilateral HUN	Unilateral VUR grade 3	-	-	Refluxing megaureter
<u>P8</u>	Bilateral HUN with bladder wall thickening	-	-	-	PUV
<u>P9</u>	Bilateral HUN with bladder wall thickening+ bladder outlet obstruction	-	-	-	PUV
<u>P10</u>	Bilateral HUN with bladder wall thickening	Left unilateral VUR grade 1	-	-	PUV
<u>P11</u>	Bilateral HUN with diverticular bladder	-	-	-	Urethral polyp
<u>P12</u>	Bilateral HUN with bilateral pyonephrosis +	Right unilateral VUR grade 4	-	-	Refluxing megaureter

	right renal abscess				
<u>P13</u>	Bilateral HUN laminating renal parenchyma+ double right excretory system	PUV + diverticular bladder	-	-	PUV + double right excretory system
<u>P14</u>	Bilateral HUN	-	-	-	Neurogenic bladder /SB
<u>P15</u>	Bilateral HUN laminating renal parenchyma + multiple renal cysts	-	-	-	Neurogenic bladder
<u>P16</u>	Bilateral HUN preserving renal parenchyma	PUV + diverticular bladder	-	-	PUV
<u>P17</u>	Bilateral HUN	Left VUR grade 5	-	-	Refluxing megaureter
<u>P18</u>	Bilateral UHN and bladder wall thickening + right duplication of the collecting system	-	-	-	Neurogenic bladder / SB
<u>P19</u>	Bilateral HUN reducing renal parenchyma + PUV	-	-	-	PUV

<u>P20</u>	Bilateral HUN laminating renal parenchyma + bladder wall thickening	Bilateral VUR grade 1 +diverticular bladder	-	-	Neurogenic bladder
<u>P21</u>	Bilateral HUN laminating renal parenchyma + bladder wall thickening	Diverticular bladder	-	-	Neurogenic bladder
<u>P22</u>	Bilateral HUN laminating renal parenchyma + PUV	-	-	-	PUV
<u>P23</u>	Bilateral HUN + Bladder wall thickening + PUV	Diverticular bladder	-	-	PUV
<u>P24</u>	Bilateral HUN	PUV	-	-	PUV
<u>P25</u>	Bilateral HUN preserving renal parenchyma + bladder wall thickening	-	-	-	PUV
<u>P26</u>	Bilateral HUN preserving renal parenchyma	-	-	-	Neurogenic bladder / SB

<u>P27</u>	Bilateral HUN reducing renal parenchyma	Diverticular bladder	-	-	Neurogenic bladder / SB
<u>P28</u>	Bilateral HUN + bladder wall thickening	Right VUR s grade 4 + PUV	-	-	PUV+ right RVU
<u>P29</u>	Right HUN laminating renal parenchyma + dystrophic left kidney	Right VUR grade 5	-	Important Right UHN + dystrophic left kidney	Refluxing right megaureter+ dystrophic left kidney
<u>P30</u>	Important Bilateral HUN	Diverticular bladder	Important bilateral UHN	-	PUV
<u>P31</u>	Bilateral HUN + diverticular bladder	-	-	-	PUV
<u>P32</u>	Bilateral HUN + bladder wall thickening	-	-	-	PUV
<u>P33</u>	Bilateral HUN	-	-	-	Neurogenic bladder / SB
<u>P34</u>	Bilateral HUN laminating renal parenchyma in right	Right VUR grade 4	-	-	Refluxing megaureter

<u>P35</u>	Bilateral HUN preserving renal parenchyma with normal bladder	Bilateral VUR grade 3	-	-	Refluxing megaureters
<u>P36</u>	Bilateral HUN reducing renal parenchyma	Bilateral VUR: grade 1 on the right and 4 on the left	-	-	Refluxing megaureters
<u>P37</u>	Bilateral HUN + diverticular bladder	-	-	-	PUV

B. Traumatic pathology

Table 3. Summary table of retained diagnoses of traumatic pathology.

<u>P38</u>	Traumatic bladder rupture
<u>P39</u>	Trauma of the bulbar urethra/ pelvic fracture
<u>P40</u>	Trauma of the posterior urethra

VI. THERAPEUTIC CONDUCT

A. Malformative uropathy

1. Medical management

a. Antibiotherapy:

Patients with documented UTI received Antibiotherapy initially with third generation cephalosporin and then adapted to the results of the antibiogram (Chart 12).

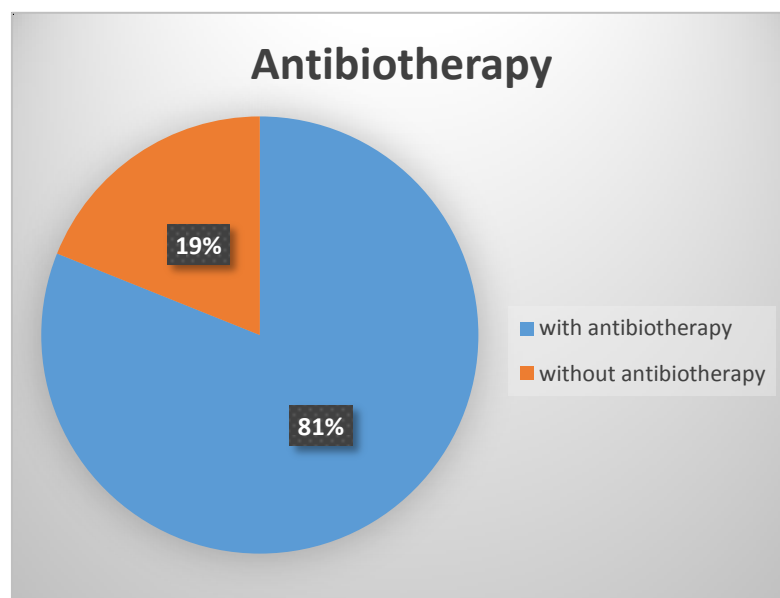


Chart 12: Distribution of patients according to antibiotherapy.

b. Rehydration and correction of hydro electrolytic disorders:

On admission, the patients received rehydration and correction of hydro electrolytic disorders, using hypokalemic measures in 8 patients and sodium supplementation in 10 patients.

2. Surgical management**a. The types of incontinent urinary diversion:**

- ☞ CV was performed in 29 patients.
- ☞ CU was performed in 5 patients.
- ☞ CV + CU was performed in 3 patients.
- ☞ Nephrostomy wasn't performed in any patient.

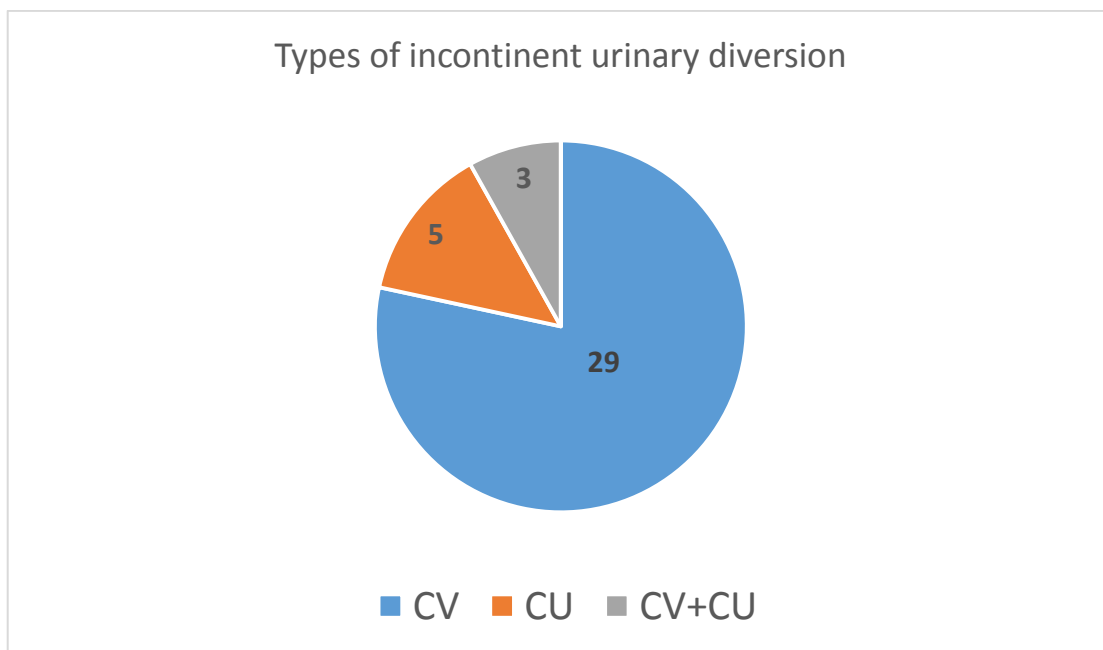


Chart 13. The types of incontinent urinary diversion in patients *with MU*.

b. Cutaneous vesicostomy:**b-1: Achievement age:**

From 37 patients 32 underwent a CV (Chart 14).

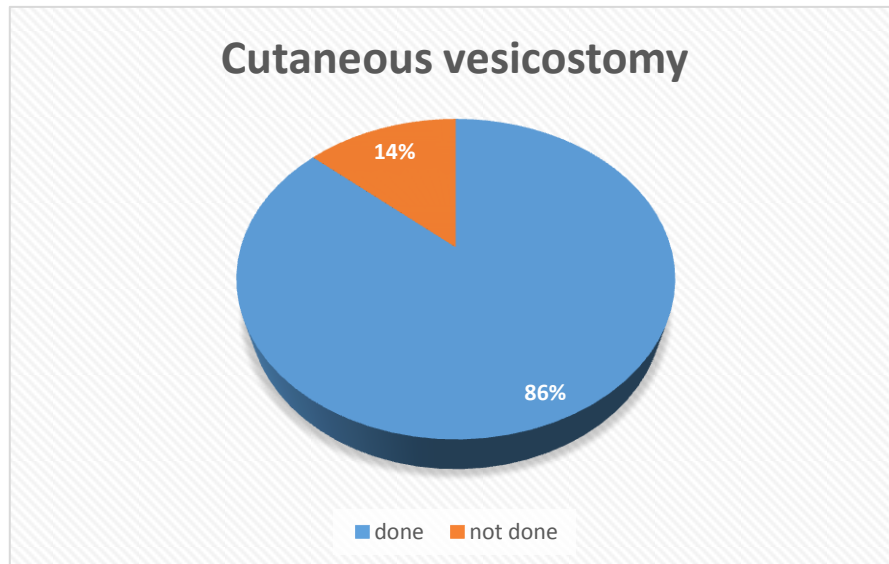


Chart 14. Distribution of patients according CV.

At the time of performing CV, the age of the patients ranged from 12 days of life up to 14 years, with an average age of 25.9 months and a standard deviation of 43.3 months, the median age of completion CV is 5 months with minimum and maximum ages of 1 and 168 months.

Twenty-three patients are drained before the age of 1 year (62% of cases), including 5 in the neonatal period (Chart 15).

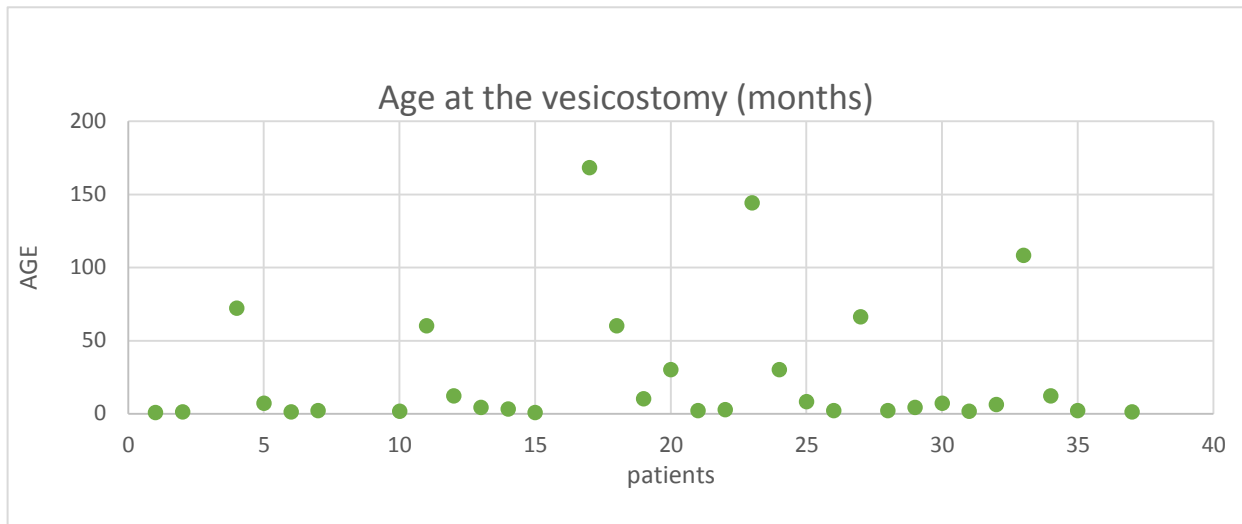


Chart 15. Distribution of patients according to achievement age of CV.

b-2: Closure of the CV:

Closure of the CV was performed in 12 patients (40% of patients under vesicostomy). At the time of closure, the age of patients varied between 1 month and 31 months with a mean delay of 22 months of diversion (CHART 16).

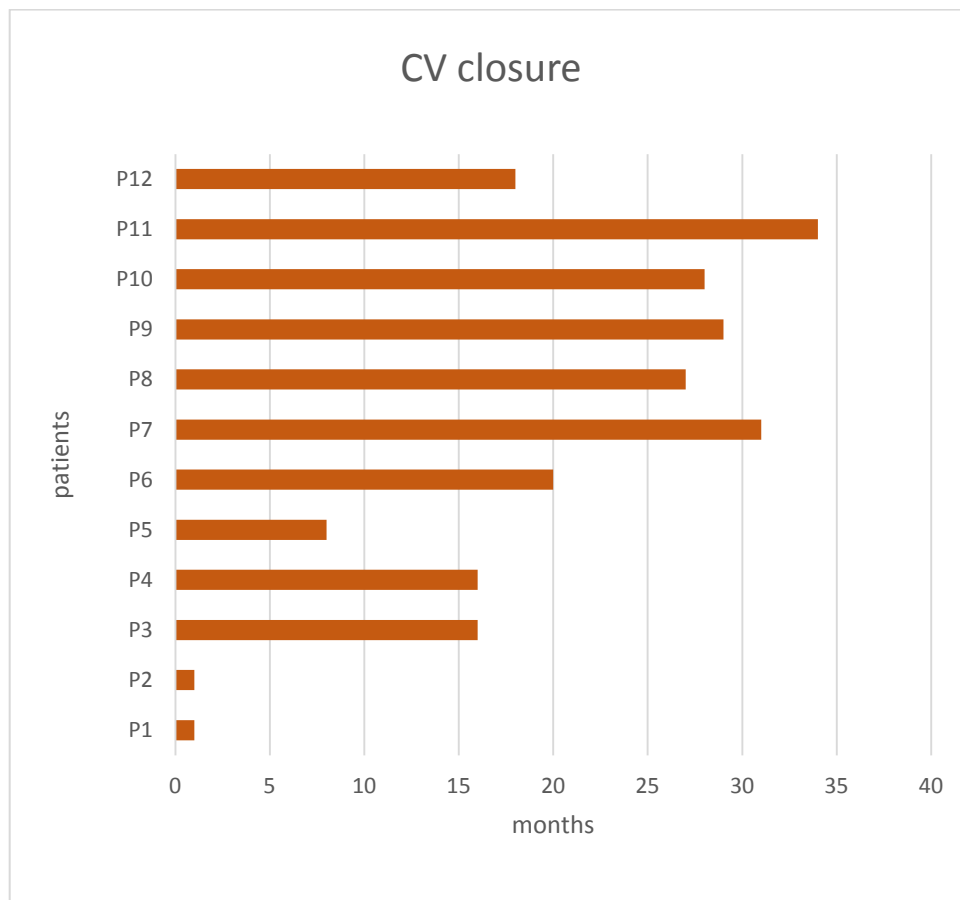


Chart 16. Distribution of patients with closure CV.

2 patients died before the closure of CV (6% of cases).

For the 18 remaining patients the CV wasn't close under the end of our work.

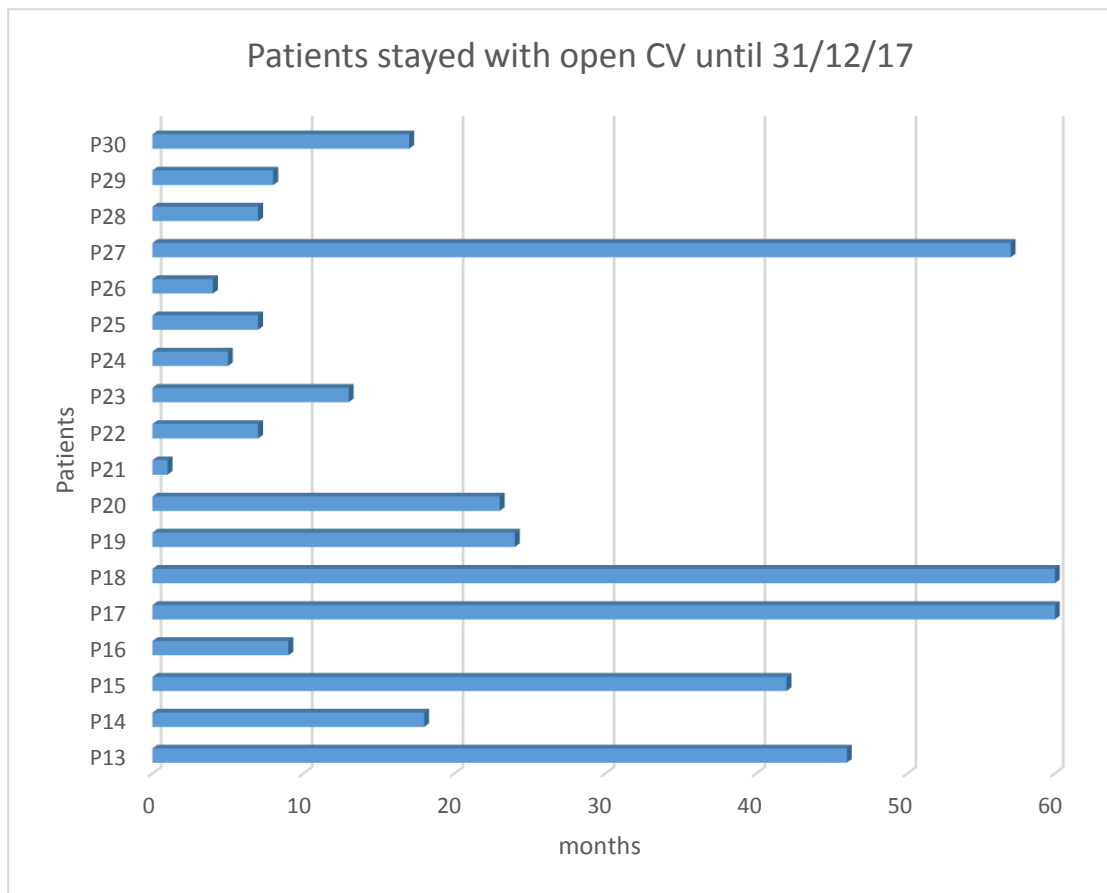


Chart 17. Distribution of patients stays with open CV until 31/12/2017.

b-3: Diagnoses and indications for CV:

- **Diagnoses**

Table 4. Diagnoses and number of patients with CV.

No. of patients	
• <u>Neurogenic bladder:</u>	
Myelomeningocele	5
Unknown etiology	2
Williams & Beuren	1
• PUV	15
• Refluxing Megaureters	8
• Urethral stenosis	1
TOTAL	32

- **Indications for CV included:**

- Hydroureteronephrosis in 19 patients.
- Bladder dysfunction in 6 patients.
- Evolved VUR in 5 patients.
- Reduction in renal function and Pyonephrosis in 1 patient.
- Urethral stenosis by urethral polyp in 1 patient.

c. **Cutaneous ureterostomy:**

Ureterostomy was performed in 8 patients (21% of cases).

c-1: **Achievement age of ureterostomy:**

At the time of performing CU, the age of the patients ranged from 1 month to 108 months, with an average age of 28 months, and a standard deviation of 37.09 months, the median age of completion of ureterostomy is 9.5 months with minimum and maximum ages of 1 and 108 months.

5 patients were drained before the age of 1 year, which is 62.5% of cases.

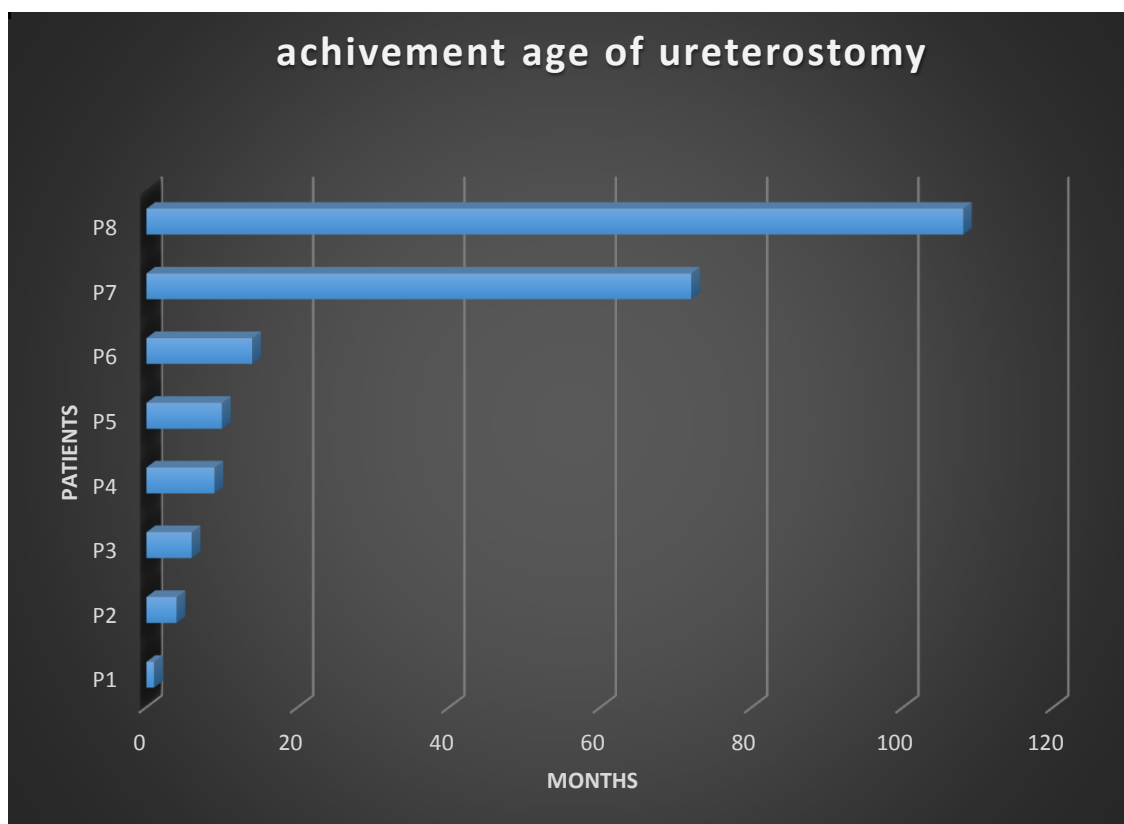


Chart 18. Distribution of patients according the age of realization of ureterostomy.

c-2: **Drained side:**

The ureterostomy was bilateral in 6 patients (75% of cases), and unilateral in 2 patients (25% of cases).

The reports of 5 patients were analyzed: 2 ureterostomies were performed according to end ureterostomy and 3 to ring ureterostomy.

c-3: Closure of ureterostomy:

The closure was performed in 6 patients.

The average age of closure was 28 months; it ranged from 34 to 120 months.

c-4: Duration of ureterostomy:

The mean duration of ureterostomy was 16 months; it has varied from 3 to 33 months.

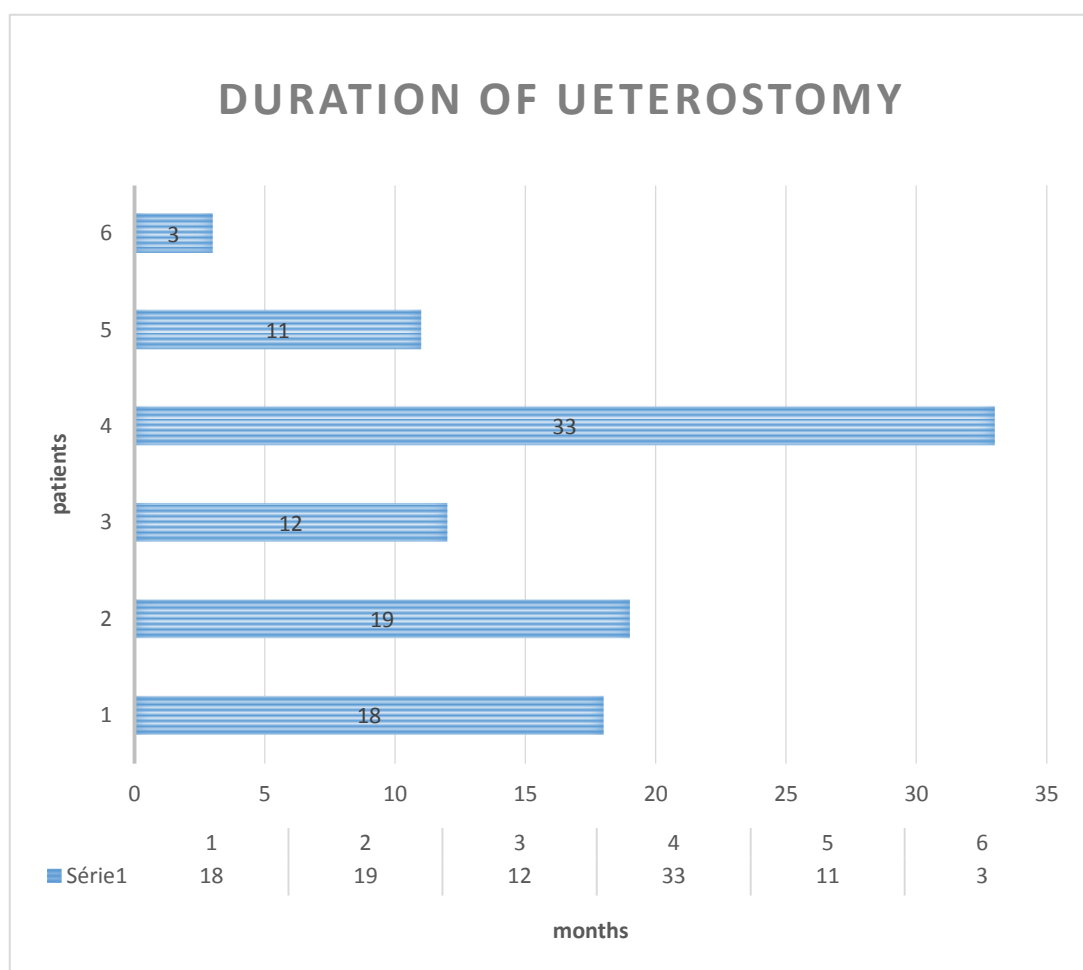


Chart 19. Distribution of patients according to the duration of ureterostomy.

c-5: Indications of ureterostomy:**Table 5. Indications of cutaneous ureterostomy.**

Patients	Diagnosis	Indication
<u>P1</u>	PUV	Renal failure + Ascites
<u>P2</u>	Left refluxing megaureter	Hydroureteronephrosis on congenital single kidney
<u>P3</u>	Right refluxing megaureter	Persistence of hydroureteronephrosis + deterioration of renal function after reimplantation
<u>P4</u>	PUV	Important hydroureteronephrosis laminating renal parenchyma + oliguria
<u>P5</u>	Bilateral Megaureters	Pyelonephritis
<u>P6</u>	Bilateral obstructive Megaureters+ neurogenic bladder	Persistence of hydroureteronephrosis +recurrent UTI and deterioration of renal function after CV
<u>P7</u>	Neurogenic bladder + bilateral obstructive Megaureters	Renal failure +recurrent UTI
<u>P8</u>	Left refluxing megaureter	Recurrent UTI & persistence of hydroureteronephrosis after CV

c-6: Concomitant interventions at closure of cutaneous ureterostomy

At the time of closing the CU, concomitant intervention was performed in 5 patients.

Table 6. Concomitant interventions at closure of cutaneous ureterostomy.

Patient	Indication	Concomitant intervention
<u>P1</u>	Mute right kidney	Right nephrectomy
<u>P2</u>	Hypoplastic left kidney	Left nephrectomy
<u>P3</u>	Refluxing megaureter on congenital single kidney	Reimplantation by COHEN procedure
<u>P4</u>	Mute left kidney	Left nephrectomy
<u>P5</u>	POM	Reimplantation by COHEN procedure

d. Nephrostomy

No patient has done nephrostomy.

B. Traumatic pathology

1. Medical management

No patient received Antibiotherapy before performing surgery.

2. Surgical management

In our 3 patients CV was performed:

At the time of performing CV, the age of the 3 patients was 10 and 11 years;
Closure of the CV was performed in our 3 patients (100% of cases) with a mean delay of 7.6 months of diversion.

VII. FOLLOW UP OF PATIENTS

A. Malformative uropathy

1. Evolution under urinary diversion

a. Clinical evolution:

a-1: Children's general health:

In order to establish this clinical evolution, a survey adapted to the intellectual level of families was proposing in order to make a comparison of the children's general health before and after urinary diversion, as well as to evaluate the additional care that incontinent urinary diversion provide.

This questionnaire was completed during the consultation of the children and their parents or by telephone contact for 20 patients (54% of cases). The other patients were unreachable on the phone.

The children's general health is assessed on a scale of 1 (very altered) to 5 (good) on the following criteria: nourishment, weight, activities and rest.

During urinary diversion the 20 parents judged these 4 criteria in score of 3 to 5.

Table 7. Parental evaluation of the children's general health before and during urinary diversion.

	BEFORE URINARY DIVERSION					DURING URINARY DIVERSION				
<u>SCORE</u>	<u>1</u>	<u>2</u>	<u>3</u>	<u>4</u>	<u>5</u>	<u>1</u>	<u>2</u>	<u>3</u>	<u>4</u>	<u>5</u>
Nourishment	4		6	6	4			2	4	14
Weight	1	3	5	7	4			4	5	11
Rest	3	3	3	6	5				6	14
Activities	3	3	3	6	5			1	6	13

a-2: Hygiene and care:

Most parents interviewed say that the urinary diversion stoma does not requires any special care except for three cases with periorificial redness requiring local treatment. However, additional hygiene measures have been used for all children (diapers or compresses on the orifice, change of clothing arriving up to 3 times a day).

b. Biological evolution:

b-1: Evolution of renal function:

For the evaluation of renal function, serum creatinine value and renal scintigraphy (DMSA or MAG3) were used.

- **Evolution of serum creatinine value**

At the time of the realization of the urinary diversion 20 patients had a normal serum creatinine level and they kept it as such throughout their evolution. In contrast, 17 patients came with elevated serum creatinine value: 9 of them decreased serum creatinine value to normal (Full line on chart), 2 died, 1 was lost to follow-up, and the 5 remaining patients developed a chronic history of renal failure: 3 kept a chronic renal failure, 1 was on chronic hemodialysis and 1 other in pre-

term renal failure (Chart 20).

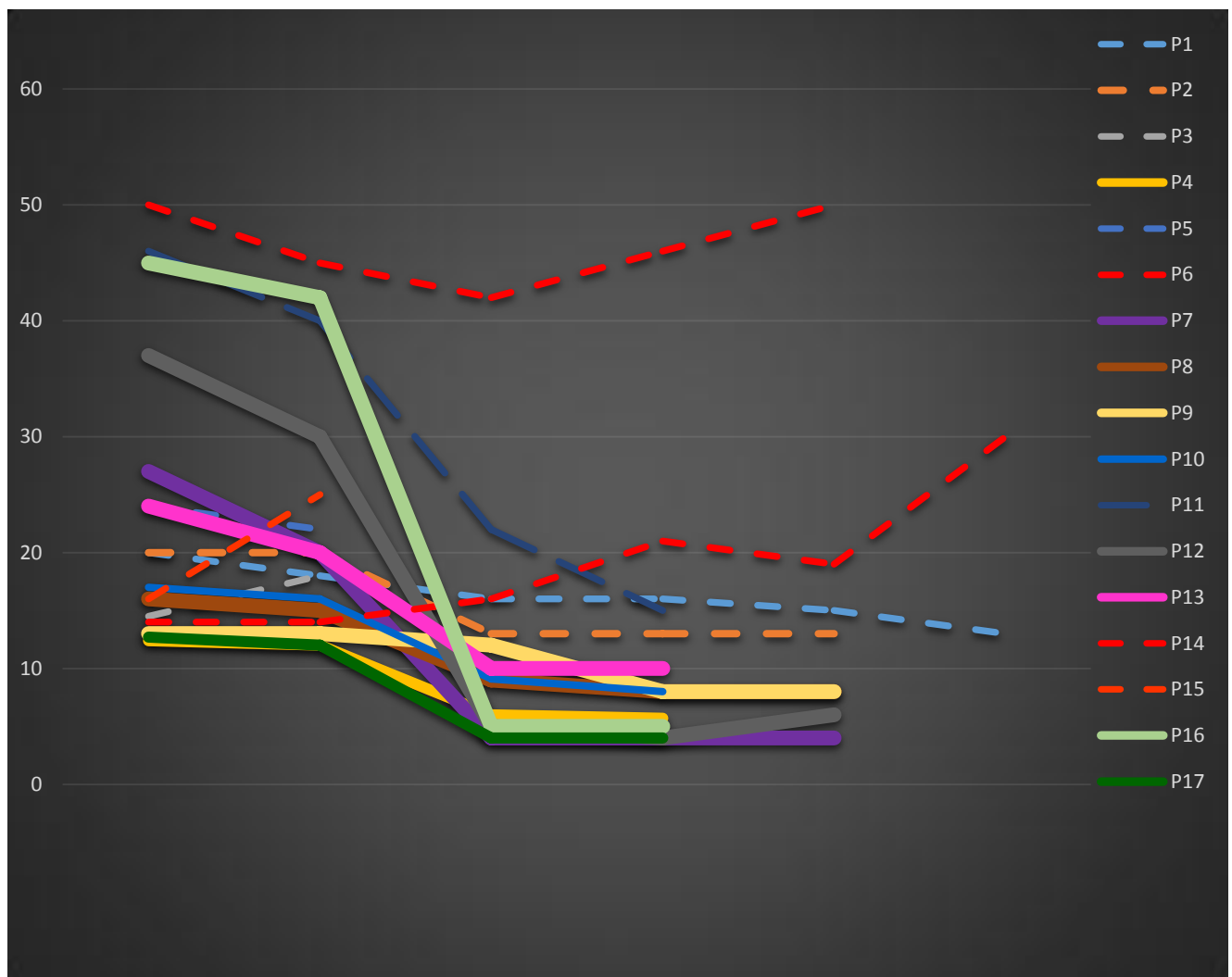


Chart 20. Evolution of serum creatinine values during urinary diversion.

b-2: Recurrent urinary tract infections:

Before performing the urinary diversion 27 patients had a urinary tract infection, 14 of them repeatedly.

After the diversion, 20 patients still have urinary tract infections, 11 of them with PUV and secondary refluxing megaureters before valve ablation.

9 patients received a correct prophylactic antibiotic, however, 6 of them still present a recurrent UTI.

Escherichia coli is the most responsible germ of recurrent UTI followed by Klebsiella pneumonia then Pseudomonas aeruginosa (Chart 21).

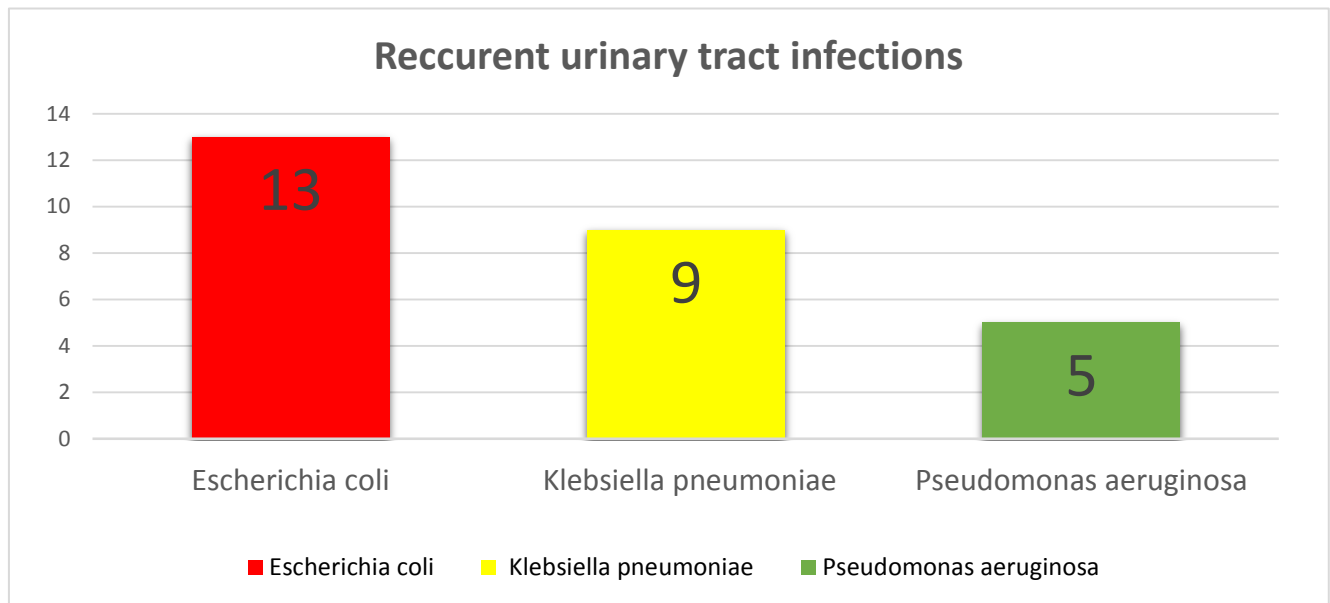


Chart 21. The most responsible germs of recurrent urinary tract infections.

c. Radiological evolution:

c-1: Ultrasonography examination:

After the realisation of urinary diversion, an ultrasonography examination was performed in order to study the morphology of the kidneys and upper urinary tract.

From the 37 patients, we found 30 ultrasound controls (Chart 22):

- There was a regression of the hydroureteronephrosis in 24 patients (65% of cases).
 - Quickly (in the first three months following surgery) in 10 patients (27% of cases).
 - Progressively (between 4 and 10 months) in 14 patients (38% of cases).
- The persistence of dilation is marked in 6 patients (16% of cases).

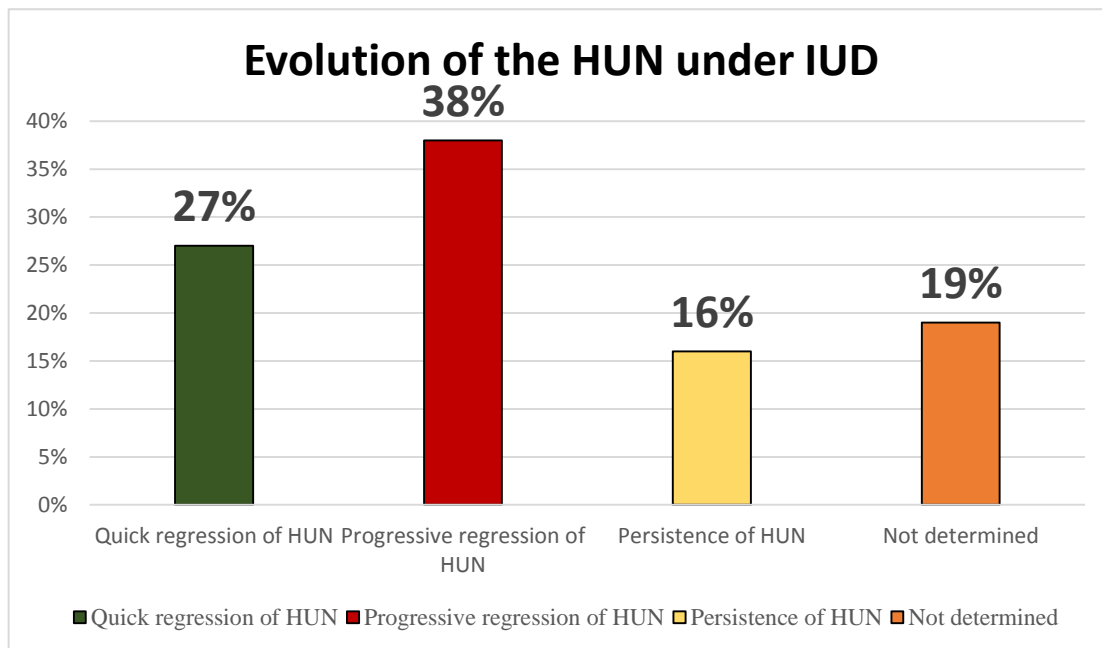


Chart 22. Distribution of patients according to the evolution of the HUN under IUD.

c-2: Retrograde urethrocytography

The RUCG was performed in 26 patients before the realization of the urinary diversion. A VUR is found on 17 patients. It is bilateral in 8 cases (47% of cases), unilateral right in 6 cases (35% of cases) and unilateral left in 3 patients (18% of cases).

After urinary diversion a control RUCG was requested for 9 patients with RVU.

We noted:

- A regression of reflux in 2 patients.
- A disappearance of reflux in 3 patients.
- A persistence of reflux in 4 patients whose:
 - ❖ Patient 1: followed since the age of 2 months for PUV with left secondary reflux grade 2. Initial management was: CV, then a valve resection at 24 months and a vesicostomy closure at 38 months. The RUCG control showed a persistence of left reflux grade 2.
 - ❖ Patient 2: followed for neurogenic bladder of unknown etiology with

secondary bilateral reflux grade 5 since the age of 12 years currently on hemodialysis for chronic end-stage renal failure under vesicostomy.

- ❖ Patient 3: Followed since the age of one month for bilateral refluxing Megaureters grade 5 under vesicostomy. The evolution was marked by the persistence of reflux.
- ❖ Patient 4: Followed since the age of one month for left refluxing megaureter grade 5 under vesicostomy. The evolution was marked by recurrent UTI and persistence of reflux hence the indication of cutaneous ureterostomy at the age of 9 months.

We didn't find the results of RUCG of 7 patients and the remaining 1 patient died.

c-3: Renal scintigraphy

Due to the unavailability of this examination initially, most patients received renal scintigraphy only after the completion of urinary diversion.

Scintigraphy was performed before urinary diversion only in 7 patients, showing a silent kidney in 2 cases, and a functional asymmetry in 5 patients.

4 of them benefited from a post drainage control scintigraphy showing:

- An equivalent distribution of relative renal function in 1 patient.
- A Persistence of mute kidney in 2 patients.
- A degradation of relative renal function with progression to a silent kidney in 1 patient.

After urinary diversion, this examination was done in 9 patients showed:

- An equivalent distribution between the two kidneys in 2 cases.
- A silent kidney in 3 cases.
- Functional asymmetry of the two kidneys in 4 cases.

2. Complications of urinary diversion

a. Immediate complications:

After urinary diversion, postoperative follow-up was free of incidents, including post-obstructive diuresis often observed during the course of decompression of dilated excretory system.

b. Late complications:

❖ Vesicostomy: complications occurred in 7 patients:

Stenosis of the vesicostomy was found in 7 patients (22% of cases). No other complications are found.

❖ Ureterostomy: complications occurred in 1 patient:

1 fistula after closure of the ureterostomy (12.5% of cases).

B. Traumatic pathology

1. Evolution under urinary diversion

For 2 patients the evolution after the closure of vesicostomy was good clinically biologically (normal renal function) and radiologically (no anomaly decelerated on the RUCG).

The 1 remaining patient presented on RUCG a complete stenosis of the bulbar urethra 4 months after performing cutaneous vesicostomy.

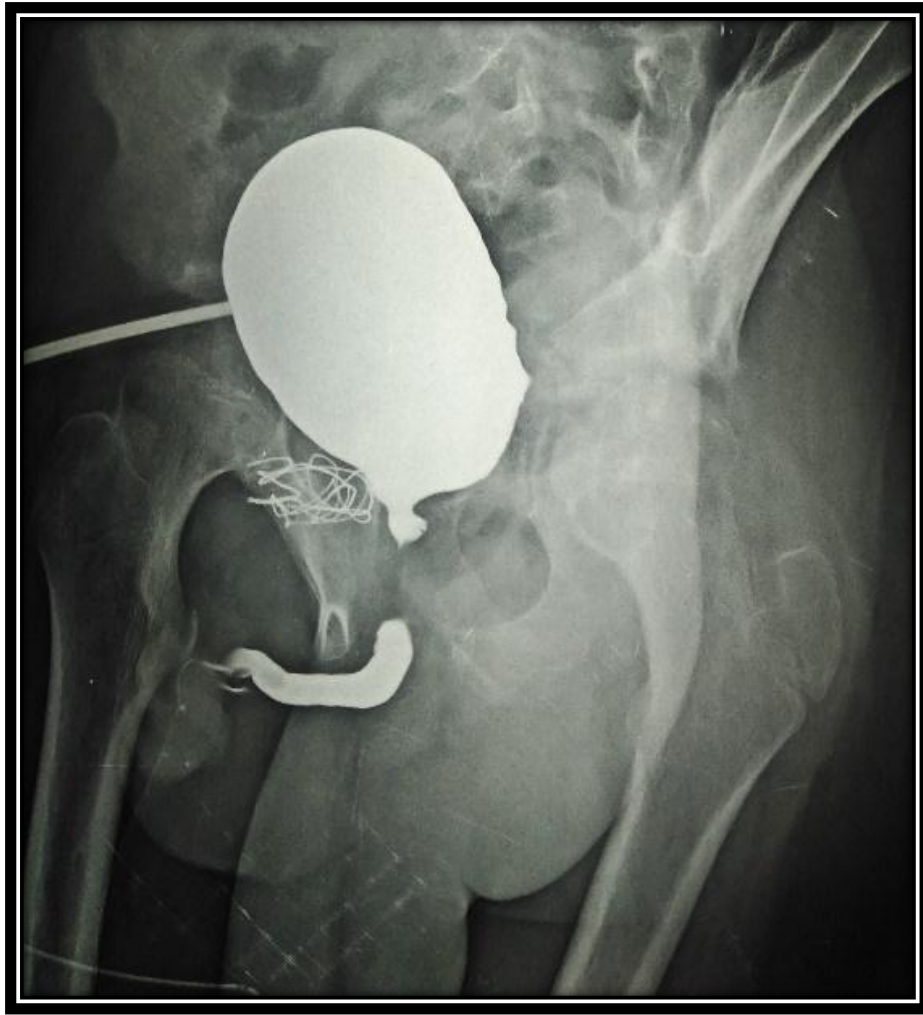

Figure 7. Control RUCG: Complete stenosis of the bulbar urethra.

(Department of pediatric surgery Hassan II FEZ)

2. Complications of urinary diversion

No immediate or late complications occurred.

DISCUSSION

I. MALFORMATIVE UROPATHY

A. Reminder

1. Pathology

CAKUT account for 20 to 30% of all congenital anomalies and are in second place after the abnormalities of the nervous system. They most often affect boys in 67% of cases.

a. Posterior urethral valve:

PUV Relate to the fetus of the male sex and it is a neonatal emergency. It is the most common low obstructive uropathy, PUV are reported in 1 / 5000–8000 live births[3],[4],[5],[6] and are a common cause of CRF and ESRD in children. Up to 43% of patients with PUV may progress to end–stage renal failure by the age of 30 years [4].

The etiology of this condition is not known, but it is believed to result from abnormal fusion of mesonephric ducts or anomalous insertion of these ducts into the cloaca during embryonic development [7].

Prognosis depends largely on the degree of obstruction, which often correlates with the presence, severity, and timing of oligohydramnios.

Young described three types of PUV [8]:

- Type 1: the most common, where the obstructing membrane radiates distally and anteriorly from the verumontanum to the urethral membrane, most often causes urinary obstruction.

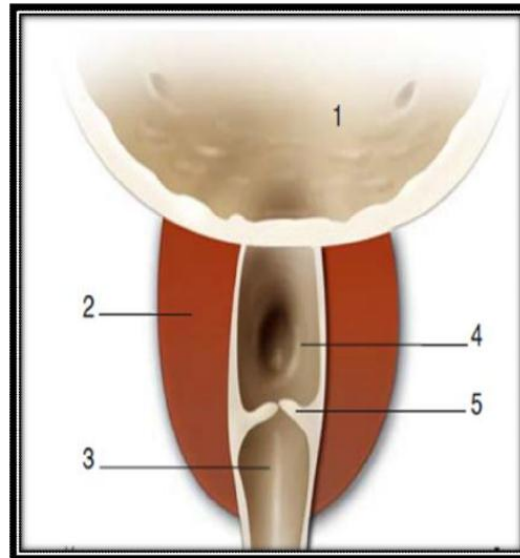


Figure 8. Type I PUV: Sub montanal valves.

1. Bladder; 2. prostate; 3. Prostatic urethra; 4. verumontanum; 5. sub-montanal valves.
- Type 2: rare, valves are prominent longitudinal folds of hypertrophied smooth muscle that radiate cranially from the verumontanum to the posterior-lateral bladder neck; these are usually non-obstructive and may be clinically insignificant.

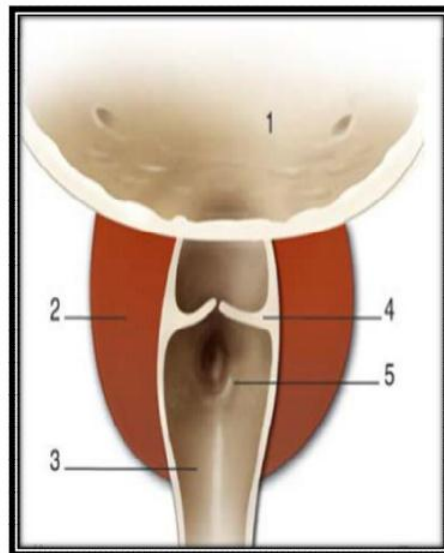


Figure 9. Type 2 PUV: sus-montanal valves.

1. Bladder 2. Prostate 3. Prostatic urethra 4. Sus-montanal valves 5. Verumontanum.
- Type 3: valves appear as a membranous diaphragm with a central aperture at the level of the verumontanum; this type of obstructive tissue has been termed congenital obstructing posterior urethral membrane.

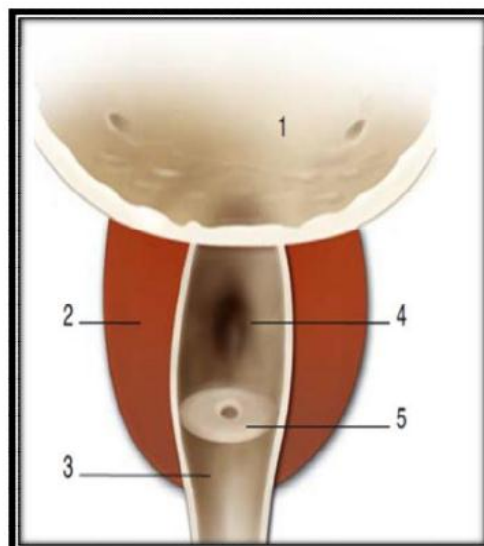


Figure 10. Type 3 PUV: sub-montanal diaphragm.

1. Bladder 2. Prostate 3. Prostatic urethra 4. Verumontanum 5. Circular diaphragm.

The diagnosis of PUV can be strongly suspected by renal ultrasound and physical exam, but a RUCG generally is diagnostic [3].

Renal ultrasound reveals varying degrees of bladder dilation with bladder wall thickening and a dilated posterior urethra the “keyhole” sign (Figure 11).

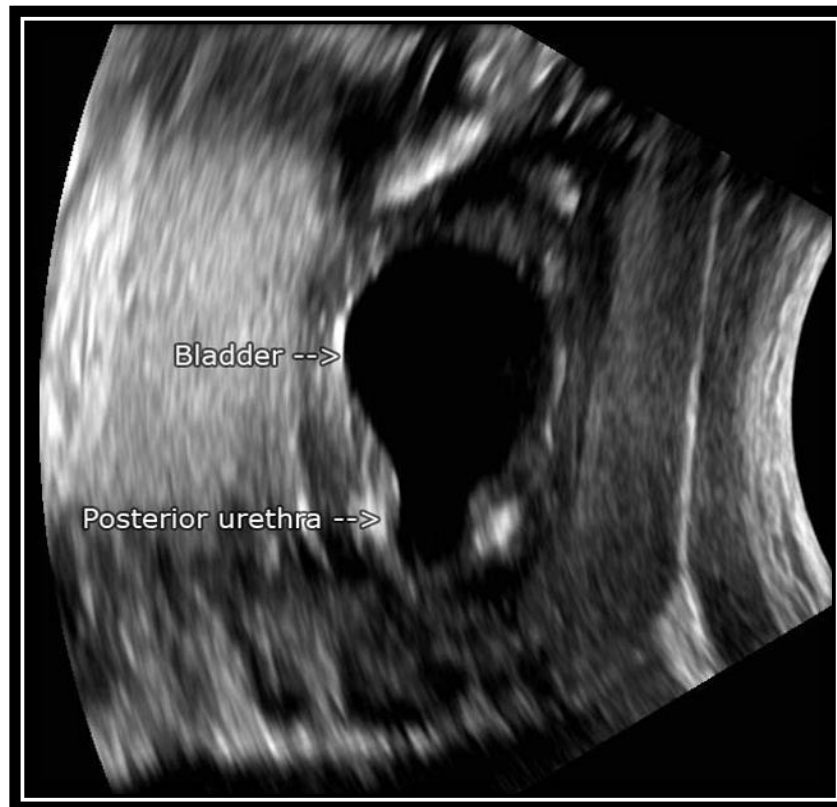


Figure 11. Keyhole sign[7].

A RUCG should be obtained without delay to confirm the diagnosis. Characteristic RUCG findings include a dilated proximal urethra with a thickened bladder neck.

There are several modalities for treatment_of posterior urethral valves. The hallmark of all the modalities is valve ablation. This can be done by open, blind or endoscopic procedures[7].

If treatment is delayed, the obstruction may lead to end-stage renal failure.

Sometimes, end stage renal failure may still occur after intervention if presentation is late[7].

b. Megaureters:

Visualized often in the 3rd trimester, it corresponds to the congenital dilation of the ureter, whether is obstructive "primitive megaureter" or secondary to a VUR [9],[10].

Megaureters rarely require emergent treatment. As shown by Confer and colleagues, 72% of lower grade (grade I to III) non-obstructing, non-refluxing megaureters resolve spontaneously in 12 to 36 months. If infection or severe obstruction is identified along with impaired or deteriorating renal function, surgical intervention in the form of cutaneous ureterostomies is required.

Prenatal ultrasound rarely makes the etiological diagnosis of a megaureter which are divided into 2 kind of pathologies: Primary obstructive megaureter and refluxing megauretere.

b-1: Primary obstructive megaureter:

The primary obstructive megaureter is the second most common cause of hydronephrosis after ureteropelvic junction obstruction. It is usually 1.6 to 4.5 times more frequent on the left than on the right and 4 times more in boys than in girls [11].

The cause of these POM is not yet determined, it is typically caused by an adynamic stenotic segment at the ureterovesical junction secondary to hypoplasia or dysplasia of the distal ureter. This obstructive lesion transmits increased pressure to the kidney and is, therefore, important to identify at an early stage. The other major risk to long-term renal function is recurrent or chronic infection [3],[11],[10].

The management of the POM has evolved this last decade from a surgical

attitude to a “careful” attitude since this malformation regresses in 70% of cases according to some authors[11],[12].

b-2: Refluxing megaureter:

We talk about refluxing megaureter when the IVU shows a megaureter and the VCUG objective a reflux without sub-vesical obstacle.

It has a common way with the other types of Megaureters, an adynamic distal segment, to which is added an incompetence of the antireflux system allowing the urine to flow back into the ureter [13].

c. Vesicoureteral reflux:

VUR, defined as retrograde flow of urine from the bladder back up the ureter into the kidney, it is a common renal abnormality predisposing neonate to UTIs and pyonephrosis. In children with urinary tract infection, we find a VUR in 30% to 60% of cases[8],[14],[15],[16].

Prevalence decreases with age and varies by sex: Of a clear female predominance, the VUR concerned 8 girls for 1 boy [17].

VUR is commonly seen in conjunction with many congenital uropathy. It is also seen as an isolated defect in approximately 1%.

The radiological cystogram remains the gold standard examination for the detection of VUR. It gives excellent anatomical definition and the grade of reflux can be determined using the international classification for VUR [18].

The severity of reflux is variable and generally evaluated according to the International reflux Study grading with VCUG [3],[19]:

- ❖ **I: Reflux into ureter but not reaching renal pelvis**
- ❖ **II: Reflux reaching pelvis without blunting of calyces**
- ❖ **III : Mild calyceal blunting**
- ❖ **IV : Progressive calyceal & ureteral dilation**
- ❖ **V: Very dilated & tortuous collecting system**
- ❖ **± intrarenal reflux as modifier to grade II+**

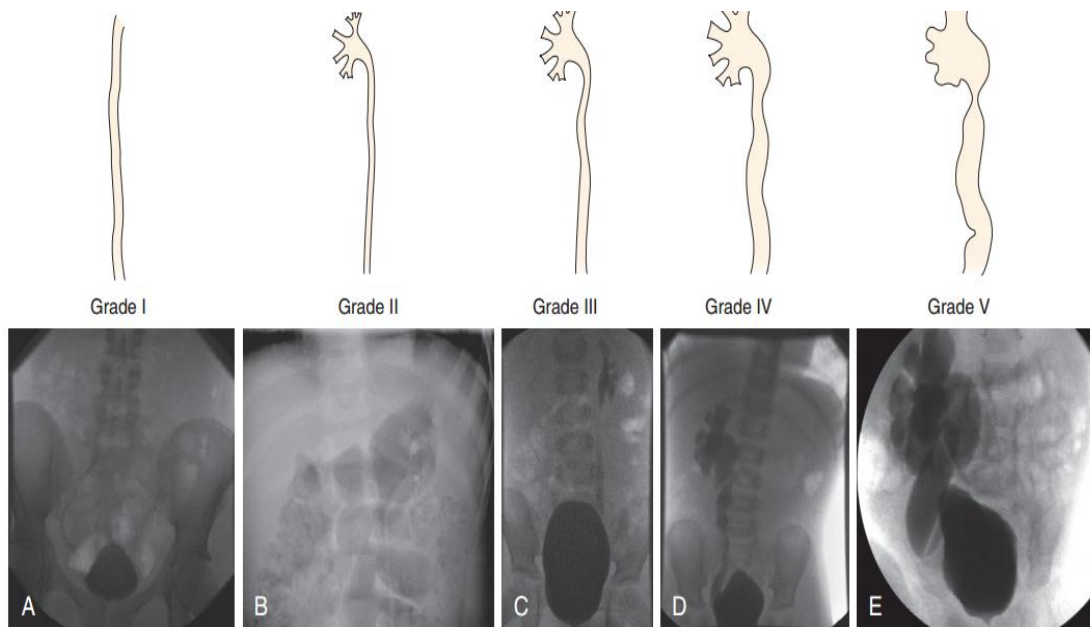


Figure 12. International classification of reflux.

- A. Grade I: Urine refluxes only into the ureter without reaching the renal pelvis or calyces
- B. Grade II: urine refluxes into the ureter, renal pelvis, and calyces, without any dilatation of the collecting system
- C. Grade III: urine refluxes into a mildly dilated and tortuous ureter, the renal pelvis, and calyces, with mild blunting of the fornices
- D. Grade IV: urine refluxes into a moderately dilated and tortuous ureter, the renal pelvis, and calyces, with complete obliteration of fornical angles but maintenance of papillary impressions
- E. Grade V: urine refluxes into a grossly dilated and tortuous ureter, the renal pelvis, and calyces, with blown fornices where papillary impressions are no longer visible.

Treatment options:

- ✓ **Prophylactic antibiotic therapy** (medical management): Reduces recurrent UTIs.
- ✓ **Ureteral reimplantation surgery** (surgical management).
- ✓ **Endoscopic periureteral injections** (minimally invasive endoscopic management).

Surgical indications for VUR have become more selective, it is rarely required in the neonatal period. If surgery is required, it is reserved for infants with high-grade VUR associated with recurrent UTIs and renal scarring [14],[16].

Overall, the management of VUR diagnosed in the neonate after a UTI following the initial evaluation includes close follow-up with renal and bladder ultrasound and selective use of continuous prophylactic antibiotic [14].

d. Double Ureter or Ureteral Duplication:

In an autopsy population, ureteral duplication occurs in 1 in 125 patients (0.8%) and constitutes the most frequent ureteral anomaly. The right and left kidneys are affected equally. There are twice as many girls as boys with duplications.

Ureteral duplication may be incomplete or complete [3],[20].

- ✓ **Incomplete ureteral duplication** is also known as a bifid collecting system (Y ureter) involving a bifid renal pelvis or bifid ureters: If there are two separate pyelocaliceal systems and they join at the UPJ, it is considered a bifid pelvis; if there are two separate ureters at the proximal aspect and they join at any point below the UPJ, but before entering into the bladder, the patient is considered to have bifid ureters.
- ✓ **Complete ureteral duplication** is when there are two separate ureters that continue and enter the urinary bladder (Figure 13).

Clinically, the most common presentation is a urinary tract infection with a

duplex system. Duplications may also come to medical attention during the work-up of abdominal pain or masses.

Diagnosis can be confirmed by an intravenous pyelogram. A RUCG is necessary to evaluate reflux that is present in more than half of complete duplications and in almost a quarter of the incomplete duplication.

Therapy varied from segmental renal resection and ureterostomy to reimplantation of refluxing ureter [3].

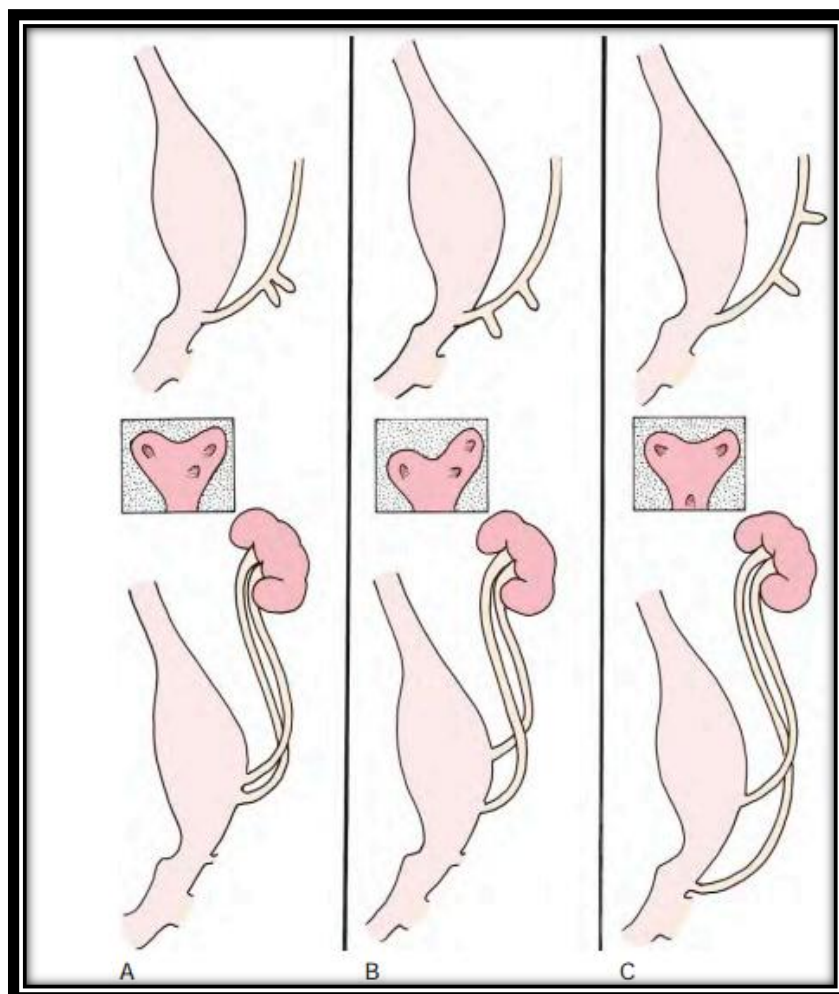


Figure 13. Complete ureteral duplication.

- A. Complete ureteral duplication formed by two ureteral buds originating from a normal site on the mesonephric duct
- B. One of the two ureteral buds has a lower than normal origin, resulting in complete duplication with Vesicoureteral reflux into this ureter.
- C. One of the two ureteral buds has a higher than normal origin, resulting in complete duplication

with an ectopic upper pole ureter.

e. **Neurogenic bladder:**

Neurogenic bladders include all vesico-sphincter dysfunctions due to a congenital abnormality of the nerve pathways (lumbosacral dysmorphisms, sacral agenesis, diastematomyelia) which are the more frequent.

The diagnosis of a neurogenic bladder may be suspected in the presence of spinal dysraphism at birth. These neurogenic bladders have a double consequence: incontinence urinary tract and the more or less rapid degradation of the urinary tract lead to end-stage renal failure.

The essential of treatment is the preservation of the upper urinary tract and get a social continence. [2],[21],[22].

2. **Surgical technics**

a. **Cutaneous vesicostomy:**

Two technics for cutaneous vesicostomy have been used for many years [23]:

- **The Blocksom vesicostomy [24]** is fashioned through a small transverse incision halfway between the umbilicus and the pubis. The fascia is incised, and the peritoneum is pushed superiorly off the dome of the bladder. The urachal remnant is divided, and the dome of the bladder is pulled up to the skin. The fascia is secured to the bladder wall to form a 24-Fr defect, and the bladder is matured as a flush stoma.

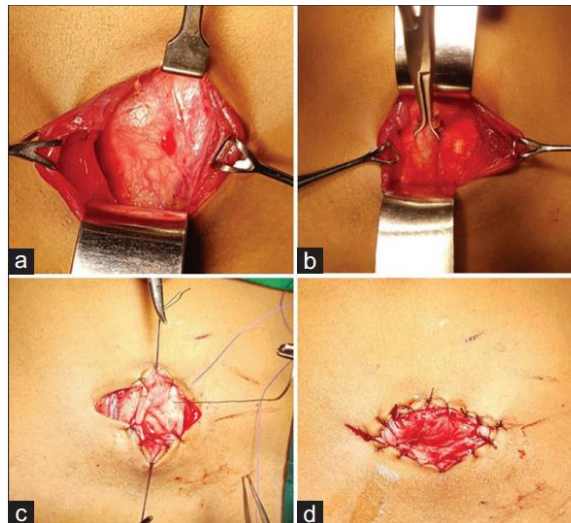


Figure 14. Blocksom Vesicostomy [24].

- a. Urinary bladder exposed after retracting rectus abdominis muscle,
 - b. Urinary bladder brought out with Babcock's forceps,
 - c. Fixation sutures taken from Bladder wall to muscle layer,
 - d. postoperative bladder stoma.
- **Lapides [25]**, described elevation of an anterior bladder wall flap with deep insertion of an abdominal skin flap to fashion the cutaneous vesicostomy.

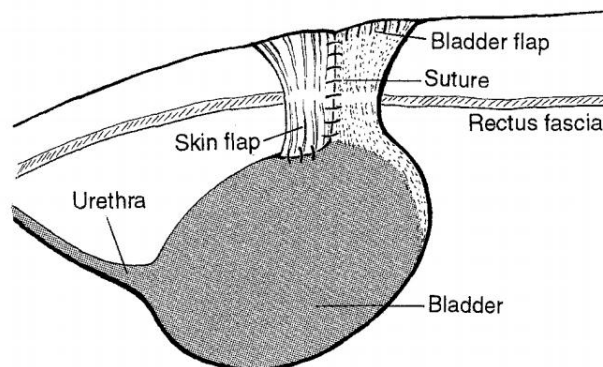


Figure 15: Sagittal view of Lapides-type cutaneous vesicostomy [26].

The more common technique was described by **Blocksom** in 1957 and modified By **Duckett** in 1960's [24].

In our series, all patients underwent a Blocksom vesicostomy.

b. Cutaneous Ureterostomy:

Cutaneous ureterostomy is a type of urinary diversion in which one or both ureters are detached from the bladder and brought through the abdominal wall to form a STOMA. It is a safe, quick, and effective procedure in treatment of hydronephrosis, and is introduced to remove high pressures in renal cavities [27].

b-1: Proximal ureterostomy:

They ensure a good drainage of the upper excretory cavities, while having the advantage of preserving the length of the ureter and its vascularization. They are of three types:

❖ **Loop ureterostomy:** first described by Johnston in 1963 [28].

Loop ureterostomy is an excellent form of urinary diversion in selected cases of congenital hydroureteronephrosis. It can easily be taken down and is the more appropriate choice for temporary diversion.

Technic: after an oblique incision in the mid flank, the muscles are split and the retroperitoneum is entered. The ureter is easily identified, and a loop is brought to the skin with minimal mobilization. The ureter is opened longitudinally for 2 cm [29].

A loop of ureter brought to the skin without disrupting ureteral continuity obviates most of the disadvantages of other drainage procedures and adds significant advantages of its own.

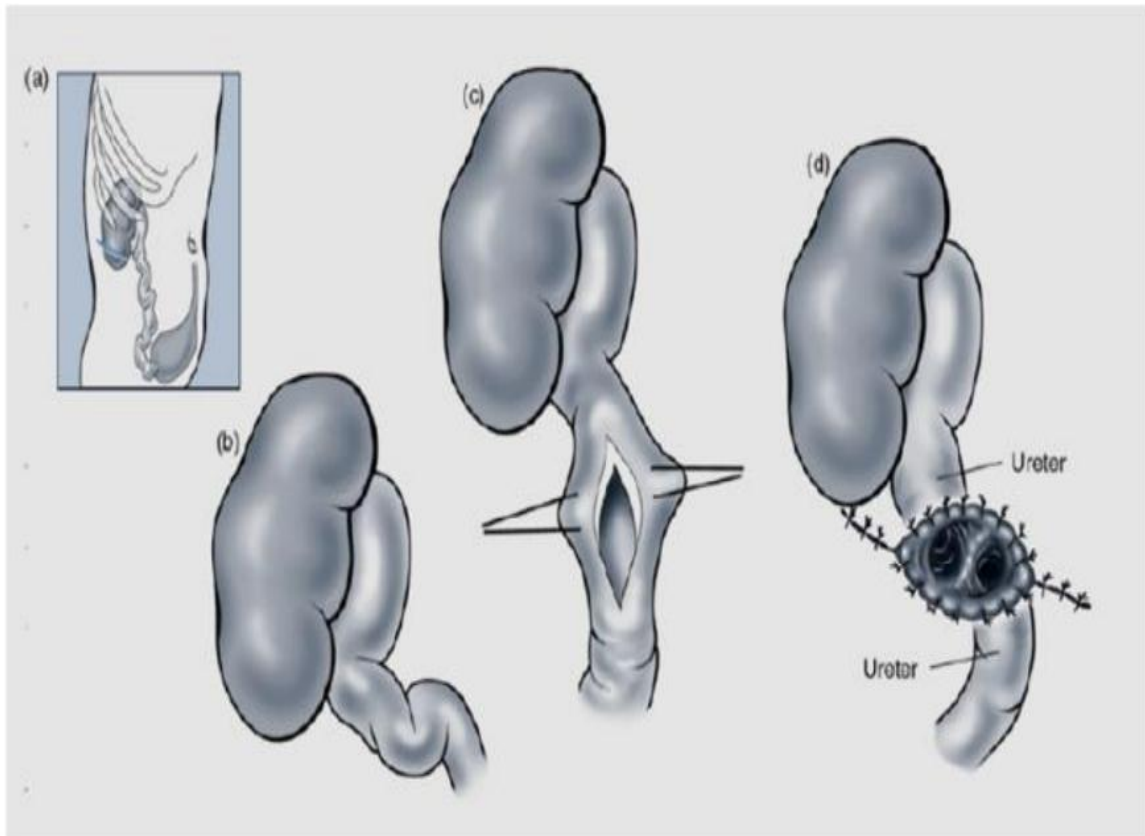


Figure 16. Surgery steps of loop ureterostomy:

- a. Lateral lobotomy.
- b. Locating the dilated ureter.
- c. Longitudinal ureterostomy.
- d. Making of ostomy orifice.

The advantages of loop cutaneous ureterostomy are several: Effective renal drainage is readily and simply established. A foreign body is not introduced into the urinary tract. A generous stoma can be created which is less likely to stricture. The ureteral blood supply is in less danger of jeopardy, since the stoma is nourished from both ends of ureter [29].

Although loop ureterostomy is an easy and relatively short operation, it had one serious drawback: there is little or no urine flow down the distal limb of the ureter this has the risk of allowing contracted bladder as well as posing problems in ureteric reimplantation in a dry field [30],[31].

Loop ureterostomy can be temporary or permanent, or can easily be converted to an ileal conduit when desired [29].

❖ **Sober ureterostomy** First described by Sober in 1972 [31].

Technic: The kidney and ureter are approached retroperitoneally. The ureter is divided at a point sufficiently far below the renal pelvis to leave enough length for the proximal cut end to be used as a terminal cutaneous stoma. The distal cut end is then anastomosed to the side of the renal pelvis as in a pyeloplasty using a single layer of catgut sutures.

The proximal cut end is then delivered into the loin incision and stitched to the skin as a nipple ureterostomy stoma. The stoma is intubated for 10 days to allow the edematous suture line to settle but after that the tube is removed.

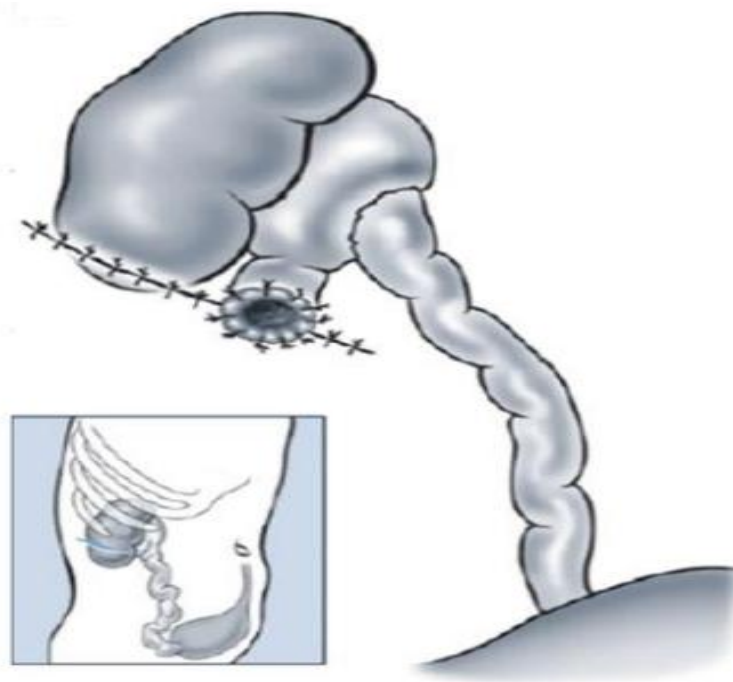


Figure 17. Sober ureterostomy.

In the inverted Sober ureterostomy (Roux-en-Y ureterostomy), it is the distal segment that is attached to the skin, while the proximal segment is anastomosed to the distal segment.

The greatest advantage of the procedure is the ease with which the ureterostomy can be closed. The Sober Y ureterostomy does not damage the bladder because it permits decompression and passage of urine into the bladder at the same time but the stoma is an end one and is apt to stenosis reason why sober ureterostomy, is rarely used today [30].

❖ **Ring ureterostomy:** First described in 1976 [30].

Ring ureterostomy combines both the advantages of the loop ureterostomy with a well vascularised stoma and the sober Y ureterostomy allowing easy restoration of ureteric integrity.

Technic:

The child is placed in the flank position and a short skin incision is made below the 12th rib, rather anteriorly. The muscles are divided and the retroperitoneal space entered. The ureter is identified without difficulty.

The highest loop of ureter is chosen and traced up to the renal pelvis, care being taken not to devascularise it, while freeing proximally obstructing kinks. Following mobilization, the loop of ureter to be used should be drawn out of the wound by a rubber sling, and an anastomosis made between the two limbs of the loop at the base. Two longitudinal ureterostomy incisions are made, approximately 2 cms in length parallel to one another in the proximal and distal limbs and a side-to-side anastomosis is performed with 0000 continuous Dexon suture. Often it is convenient to employ the renal pelvis itself to form the upper limb, thus effectively performing a pyeloplasty in cases with secondary pelvi-ureteric obstruction due to kinking. A ring of ureter is thus created, the superficial arc of which is brought out through the incision and the muscle layer is closed in a bridge through the center of the ring. The exteriorized arc is then incised laterally and sutured to the skin. The absence of kinks may be confirmed by the passage of a catheter but no indwelling

tube should be required. The operation can be performed bilaterally at the same session.

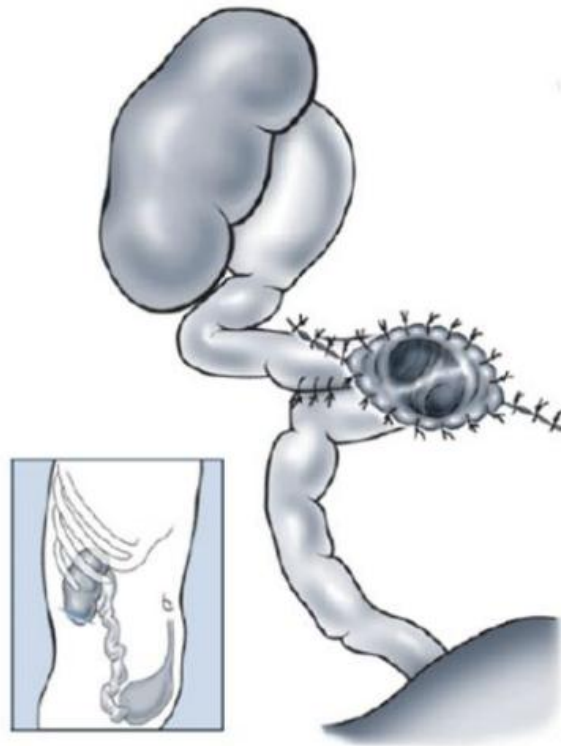


Figure 18. Ring ureterostomy.

- In all 3 types, the ureter is approached by an anterolateral lobotomy incision. The abdominal muscles are cut along the length of the incision. The ureter is spotted retroperitoneally and moored to the skin.

b-2: Distal ureterostomy (inguinal):

They have a place as a longer-term derivation mode than proximal ureterostomy. The can be lateral or terminal:

❖ **Lateral ureterostomy**

They have the same principles as proximal lateral ureterostomy.

❖ End ureterostomy

Technic:

End ureterostomy is usually performed via a 2-cm modified Gibson incision lateral to the border of rectus muscle. The external oblique aponeurosis is divided in the direction of its fibers, the internal oblique and transversus abdominis muscles are split. The ureter is easily identified extraperitoneally and dissected to the vesicoureteric junction. The ureter is ligated at the VUJ and divided proximally, preserving the maximum length. The end of the ureter is brought out as a stoma through the incision and fixed to the external oblique sheath and the skin with interrupted vicryl stitches [29].

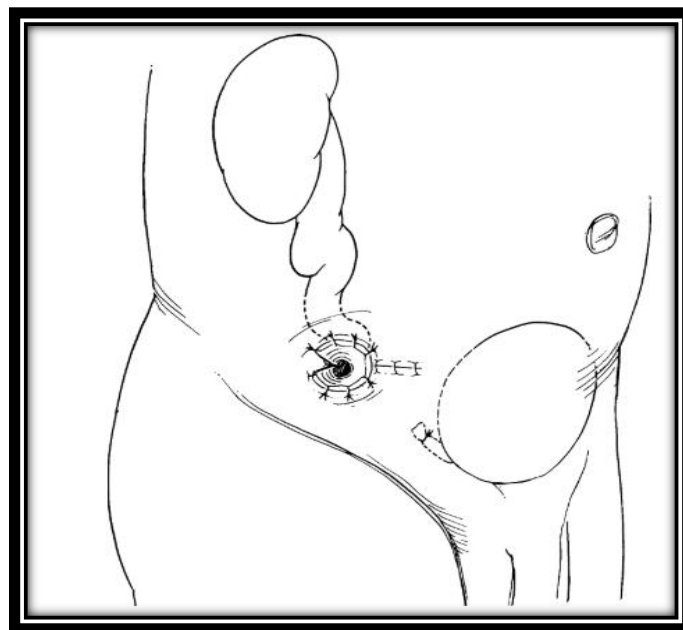


Figure 19. End cutaneous ureterostomy.

End cutaneous ureterostomy—unilateral to the flank or bilateral to the midline is an excellent form of tubeless diversion. Its major disadvantages are disruption of continuity of the ureter, danger of distal ureteral slough from a compromised blood supply and a high incidence of ureterocutaneous stricture [29].

End ureterostomy makes reconstitution of the ureter more difficult and should

be reserved as a rare permanent form of diversion in cases of severe bladder dysfunction [23].

c. Nephrostomy:

Percutaneous nephrostomy is a passageway that is introduced percutaneously into the renal pelvicalyces that can later be maintained by a tube, stent or catheter. Following its introduction by Wickbom in 1954 who described percutaneous puncture of the renal pelvis as a diagnostic procedure, Goodwin and Casey first described its therapeutic use for relief of urinary tract obstruction the following year in 1955 [32].

According to SIR one of its indications is: Provision of urinary diversion in cases of urinary tract obstruction is a safe technique that can be used successfully for short- and long-term drainage in all children, even in small infants and those with solitary kidneys, and is a valuable adjunct to surgery, and there is no single recognizable absolute contraindication [33].

B. Diagnosis conduct in front of malformative uropathy

1. Antenatal diagnosis

The advent of antenatal ultrasound has transformed the life and functional prognosis of congenital uropathy and has upset the management of these abnormalities by allowing an early diagnosis and therapeutic approach, participating largely to the reduction of mortality and morbidity associated with this affection [9].

The circumstances of discovery are fortuitous in the vast majority of cases, sometimes in the first trimester, mainly in the second or third trimester.

The incidence of antenatal detection of a genitourinary anomaly varies between 0.5% and 2% of all pregnancies. Rarely, there is a known genetic risk: familial urinary pathology of dominant transmission, consanguinity of the couple or a case in the siblings.

The ultrasound discovery of an hydroureteronephrosis is quite common in antenatal (1 to 4% of pregnancies). The international rate of antenatal screening for these abnormalities is about 60% to 70% [34].

Threshold values have been defined to try to specify the prognosis of the dilation. Most authors agree that the upper limit of the norm is 4mm before and 7mm after 33 weeks of amenorrhea. The risk of uropathy is even higher than the dilation is important (greater than 15mm in the third trimester) and that it gets worse during the pregnancy [35].

In countries where ultrasound is answered, the diagnosis of MU is becoming more frequent in antenatal. Therefore, the postnatal care of these children has changed dramatically. Currently, pediatric urologists are consulted before birth with a presumptive diagnosis, and no longer postnatal for symptomatic children [35].

In Morocco, as in all the countries of the third world, pregnancies are poorly followed, this is due to several factors, including: poverty, the difficulty of access to

care especially in rural areas and illiteracy. As a result, the antenatal diagnosis of a MU is much less in our context.

In Kahloul & al series [9], the antenatal diagnosis was suspected in 10 patients (7% of cases).

In Rabat series [22], the diagnosis of MU was suspected in only 4 patients (18% of cases).

In our series, the diagnosis of MU was suspected in only 5 patients (13% of cases). In these patients, the obstetrical ultrasound of the 2nd and 3rd trimester showed a bilateral hydronephrosis, the earliest at 18 weeks of amenorrhea.

Table 8: Comparison of patients with antenatal diagnosis between our series and series of literature.

Authors	Year	Number of cases	Antenatal diagnosis
Kahloul & al [9]	2010	71 cases	7%
Rabat series [22]	2017	27 cases	18%
Our series	2018	37 cases	13%

2. Postnatal diagnosis

a. Clinical approach of MU:

In postnatal period, UTI is the most frequently discovered circumstance in the literature [14],[36],[37].

In infants and children, UTI are often associated with underlying anatomic abnormalities that predispose and complicate bacteriuria. First infections should therefore be considered complicated and should undergo an imaging evaluation [38].

UTI is around 69% in the Kahloul & al, 100% in Mohsen & Alireza [39].

In our series, it is around 72%.

Table 9. Comparison of patients with UTIs

Authors	Year	UTI
Kahloul & al [9]	2010	69%
Mohsen & Alireza [39]	2013	100%
Our series	2018	72%

Fever is the main physical sign, it is most often related to UTI found in 70% of cases in the Kahloul & al series and 65% in our series.

Table 10. Comparison of percentage of patients having fever.

Authors	Fever (percentage)
Kahloul & al [9]	70%
Our series	65%

b. Biological and radiological approach of malformative uropathy:

b-1: CBEU:

Neonatal UTIs are commonly caused by gram-negative rods, with *Escherichia coli* (40%–72%) and *Klebsiella* species (7%–40%) responsible for over 80% of cases. *Enterococcus*, a gram-positive coccus, is the third most common organism, with an incidence of 10%–16% [14].

Escherichia coli are the bacteria agents most commonly infecting the urinary tract. Specific *Escherichia coli* serotypes (O1, O2, O4, O6, O7, and O75), identified

by their cell wall O-antigens, are associated with pediatric UTIs [35].

In our series the isolated germs were:

Escherichia coli (54% of cases), Klebsiella pneumoniae (16.21%) then Pseudomonas aeruginosa, Staphylococcus aureus and Candida albicans.

b-2: Renal and bladder ultrasonography:

The BAPU consensus was that the initial postnatal investigation in babies with hydroureteronephrosis is the realisation of renal ultrasound and RUCG [40] .

In imaging the urinary tract in children, the modality of choice for the initial examination will almost universally be ultrasound. US is inexpensive, immediate, painless, requires no sedation or anaesthetic, is widely available, and is radiation free [41].

The reno-vesical ultrasound allows a morphological study of the kidneys, participates in the diagnosis and the follow-up of MU. The exploration should study the morphology of the entire urinary tract (kidneys, ureters, bladder and urethra) [42].

In our series, the reno-vesical ultrasound was performed in all patients (100% of cases).

In the series of kahloul & al [9], a renal ultrasound was performed in 98.5% of cases.

Table 11. Comparison of percentage of achieving reno-vesical US.

Authors	Year	Percentage of achievement of Reno-vesical ultrasound
Kahloul & al [9]	2010	98.5%
Our series	2018	100%

Hydroureteronephrosis was the predominant anomaly in our series.

Renal Doppler with Resistive Index measurement is currently proposed as a non-invasive method to diagnose obstructive uropathy, but it is not common practice for us [10].

b-3: RUCG:

This invasive examination requires retrograde catheterization of the urethra (not anodyne in boys), and involves significant risks (irradiation, iatrogenic infection, lesions of the urethra).

It allows the detection of urethral and vesical malformations. It is the exam of choice for the diagnosis of VUR and PUV. Although, RUCG is recommended after the first episode of febrile UTI for all children, depending on sex, age, and clinical presentation [15],[37].

In our series: the RUCG was performed in 26 patients (70% of cases) before urinary diversion. A VUR is found in 17 patients (45.9% of cases). It is bilateral in 8 patients (21.6% of cases), unilateral in 9 patients (24.3% of cases): Right in 6 patient (16.2% of cases) and Left in 3 patients (8.1% of cases) and PUV is found in 5 patients (13.5% of cases).

In kahloul & al series the RUCG was performed in 52 patients before urinary diversion (73% of cases): 49 VUR is found (69% of cases) and 3 PUV (4.2% of cases).

In Rabat series the RUCG was performed in 20 patients before urinary diversion (74.04% of cases): 15 VUR is found (55.56% of cases): bilateral in 5 patients (18.52% of cases) and unilateral in 10 patients (37.04% of cases), and 4 PUV (14.81% of cases).

Table 12: Comparison of the results of the RUCG between our series and the series of literature.

	VUR		PUV
	Bilateral	Unilateral	
Our series	21.6%	24.3%	13.5%
Kahloul & al [9]	69%		4.2%
Rabat series [22]	18.52%	37.04%	14.81%

b-4: URO-MRI:

Imaging of the urinary tract in children relies on US as the first-line imaging modality; however, MRI has an invaluable role to play. In most paediatric canthers, it is considered completely unacceptable to proceed to MRI in routine practice unless US had already been performed and had been unable to fully answer the diagnostic question.

US, CT, and MRI all provide good anatomic images of the kidney and urinary tract, but MRI has developed very rapidly over recent years and has great potential in the near future to change the way the urinary tract is imaged after the initial US. Uniquely, MRI can also give functional information on the kidneys unlike the other cross-sectional modalities. MRI is therefore alone in being able to give both anatomical and functional information of the kidney.

In our series, no patient did URO MRI given its unavailability and its expensive cost.

Table 13: Table comparing the diagnoses found in our series with the series of literature.

Diagnosis	Our series (37 cases)	Kahloul & al (71 cases)	Rabat series (27 cases)
PUV	17	3	6
Neurogenic bladder	8	-	2
Megaureters (POM+ refluxing Megaureters)	10	13	11
Ureteropelvic junction obstruction	1	15	6
Urethral polyp	1	1	-
Bladder exstrophy	-	1	-
Apphalia and recto vaginal fistula	-	-	1
Pyelic ectopia	-	-	1
Ureterocele	-	1	-

C. Therapeutic management of malformative uropathy

1. Cutaneous vesicostomy

a. Achievement age:

- Vastyan & al [43]: the records of 31 patients treated by CV with a mean age of 23 months.
- Prudente & al [44]: realized on 22 patients, the mean age is 44 months.
- In Mohsen & al [39]: the mean age is 7,5 months.
- In our series 32 patients were treated by CV: the mean age of 25.9 months which is close to Vastyan & al.

Table 14: Comparison of the patient's age at the time of the realization of the vesicostomy.

Authors	Year	Number of cases	Achievement age
Vastyan & al [43]	2005	31	Mean age: 23 months
Prudente & al [44]	2009	21	Mean age: 43 months
Mohsen & al [39]	2013	53	Mean age: 7.5 months
Our series	2018	32	Mean age: 25.9 months

b. Indications of cutaneous vesicostomy:

- In the series of Vastyan & al, from the 31 patients treated with CV, 19 patients had neurogenic bladder (61.29% of cases), 7 PUV (22.58% of cases) and 3 bilateral refluxing megaureter (9.67% of cases).
- In the series of Prudente & al required on 22 patients, a CV were performed on 7 PUV (33,3% of cases) and 5 neurogenic bladder/spina bifida (23,8% of cases).

- In the series of Mohsen & al, required on 53 patients, a CV were performed on 35 patients with PUV (66% of cases) and 16 patients with neurogenic bladder (30% of cases).
- In our series , the primary pahological conditions are : PUV in 15 patients, then neurogenic bladder and refluxing megaureters.

Table 15: Comparison of CV indications.

Authors	Year	Number of cases	Retained diagnosis
Vastyan & al [43]	2005	31	-PUV: 7 P -Neurogenic bladder: 19 P
Prudente & al [44]	2009	21	-PUV: 7 P -Neurogenic bladder/SB: 5 P
Mohsen & al [39]	2013	53	-PUV: 35 P -Neurogenic bladder :16 P
Our series	2018	32	-PUV: 15 P -Neurogenic bladder:8 P -Refluxing megaureters:8 P

b-1. Cutaneous vesicostomy in the treatment of posterior urethral valve:

Some authors have compared vesicostomy and primary valve ablation in the treatment of PUV:

Walid & Gordon [6]: reviewed 50 patients with PUV: 42 patients were treated with primary valve ablation (84% of cases) and 8 patients with urinary diversion (16% of cases): those patients had renal deterioration and severe hydronephrosis and/or high-grade reflux.

They concluded that CV may be indicated in patients with unrelenting urosepsis refractory to all treatment and in those with a very small urethral caliber.

Godbole & Wade [45]: reviewed the outcomes of 54 boys with PUV : 23 were treated with vesicostomy and 31 with primary valve fulguration .

They concluded that there was no significant differences in the major outcomes between those children who were treated by initial vesicostomy and those who underwent primary fulguration. The tendency was for the vesicostomy group to have done better in the major outcomes. Vesicostomy may therefore be considered in selected cases of PUV as the primary treatment option.

Lukong & Ameh [7] reviewed the role of vesicostomy in the management of PUV in 35 patients, given the limitations for endoscopic treatment in the setting: 23 patients had a vesicostomy and 12 patients had a primary valve ablation.

They concluded that CV plays an important role in management of PUV where primary valve avulsion cannot be readily done due to lack of appropriate facilities and instruments.

In our series, all patients with PUV underwent incontinent urinary diversion given the limitations of endoscopic treatment.

Table 16: Comparison of patients with PUV treated with vesicostomy or primary valve ablation.

Authors	Year	Cases	Treatment of PUV
Walid & Gordon [6]	1998	50	16% vesicostomy 84% primary valve ablation
Godbole & Wade [45]	2007	54	57% primary valve ablation 43% vesicostomy
Lukong & Ameh [7]	2014	35	66% vesicostomy 34% primary valve ablation
Our series	2018	17	100% vesicostomy

The gold standard for the treatment of posterior urethral valve is valve ablation, this could be effected by open or endoscopic approaches.

In developing countries endoscopic treatment is limited in neonates and infants due to lack of appropriate sized instruments. The neonatal cystoscope or valvotome may not be able to pass through a small neonatal urethra. In this circumstance, urinary diversion is used initially and followed later by definitive valve ablation when the urethral size would have reached an appropriate size [7].

Neonatal cystoscopes are often not readily available in our environment, thereby making primary valve ablation difficult in this category of patients. As a consequence, urinary diversion is done before the definitive valve ablation.

b-2. Cutaneous vesicostomy in the treatment of neurogenic bladder secondary to spina bifida:

Indications for vesicostomy in patients with NB caused by spina bifida included: hydronephrosis, Recurrent UTI, VUR, renal scarring and bladder calculi, UTD despite proper anticholinergic treatment and parental request[46],[47],[48].

Infants with a neurogenic bladder and unsafe storage pressures may require a vesicostomy if CIC and anticholinergic medications fail or if the family is unable or unwilling to execute this medical measures.

Joel & Hutcheson [46]: of 350 patients with myelodysplasia only 23 had a permanent vesicostomy(6.57% of cases).

Irfan & Alonson [47]: of 1573 patients with spina bifida only 14 patients underwent CV for management of their neurogenic bladder (1% of cases).

In our series: of 275 patients with SB only 5 patients underwent CV for management of their neurogenic bladder(1.85% of cases).

Table 17: Comparison of patients with neurogenic bladder/SB treated with vesicostomy.

Authors	Year	Cases	Number & Pourcentage of CV
Joel & Hutcheson [46]	2001	350	6.57%
Irfan & Alonson [47]	2017	1573	1%
Our series	2018	275	1.85%

c. Closure of cutaneous vesicostomy:

In the series of Vastyan [43], the closure of CV was performed in 24 patients which is 77,42% of cases.

Prudente & al [44]: reported closure of the CV in 6 patients (27,27% of cases), while Mohsen & al [63]: described closure of CV in 35 patients (66,04% of cases). In our series Closure of the CV was performed in 12 patients (40% of patients under vesicostomy).

Table 18: Comparison of patients with closure vesicostomy.

Authors	Number of cases	Closure of CV number & percentage
Vastyan & al [43]	31	24 (77.42%)
Prudente & al [44]	21	6 (28.5%)
Mohsen & al [39]	53	35 (66.04%)
Our series	32	12 (40%)

d. Duration of cutaneous vesicostomy:

In series of Vastyan & al, the mean duration of CV is 23 months; while in the series of Prudente & al, it is 28,8 months.

In our series, the mean duration is 22 months.

Table 19: Comparison of duration of CV in patients.

Authors	Number of cases	Mean duration (months)
Vastyan & al [43]	31	23 months
Prudente & al [44]	21	28.8 months
Our series	32	22 months

e. Complications of CV:

Complications related to CV include: Stomal stenosis, contact dermatitis, mucosal prolapse and bladder calculi [1],[23].

Prudente & al [44] reported stomal stenosis(38% of cases), dermatitis(24% of cases), and mucosal prolapse (29% of cases).

Benedetoo & al [26] reported stomal stenosis occurred in 4 patients (14.8% of cases), mucosal prolapse has not occurred in any patient, and 5 peristomal dermatitis (18.5% of cases).

Vastyan & al [43] reported stenosis in 7 patients (22% of cases), prolapse in 2 patients (6% of cases), and significant cellulitis around the stoma in 2 patients (6% cases).

Complications related to CV according to Mohsen & al [39] were: dermatitis in 10 patients (18.86% of cases), stomal stenosis in 3 patients (5.66% of cases) and mucosal prolapse in 2 patients (3.77% of cases).

In our series stomal stenosis in 7 patients (22% of cases) was the only complication, no other complications were found.

Table 20 : Comparison of complications of vesicostomy with different series.

Authors	Year	Number of cases	Complications (number & percentage)
Benedetoo & al [26]	1996	27	Stomal stenosis: 4 cases (14.8%) Peristomal dermatitis: 5 cases (18.5%)
Vastyan & al [43]	2004	31	Stomal stenosis:7 cases (22%) Mucosal prolapse: 2 cases (6%) cellulitis around the stoma: 2 patients (6%).
Prudente & al [44]	2009	21	Stomal stenosis: 8 cases (38%) Dermatitis: 5 cases (24%) Mucosal prolapse:6 cases (29%)
Mohsen & al [39]	2013	53	Stomal stenosis:3 cases (5.66%) Dermatitis:10 cases (18.86%) Mucosal prolapse:2 cases (3.77%)
Our series	2018	32	Stomal stenosis:7 cases (22%)

2. Cutaneous ureterostomy

a. Achievement age:

In our series 62.5 % of patients were drained before 1 year of life, what is comparable to the series of Sarduy & al [27].

The average age of our patients is 28 months compared to 17months in the series of Kitchens & al [49].

Table 21. Table comparing the age of patients at the time of achieving ureterostomy.

Authors	Year	Number of cases	Age of patients
Sarduy & al [27]	1982	59	70% of patients before 1 year
Kitchens & al [49]	2007	29	Average age:17 months
Our series	2018	8	62.5% of patients before 1 year Average age: 28 months

b. Drained side:

In our patients cutaneous ureterostomy was bilateral in 6 patients (75% of cases), and unilateral in 2 patients (25% of cases).

In the literature, unilateral ureterostomy is more common [49],[17].

Table 22: Comparison of the drained sides.

Authors	Year	Number of cases	Drained side
Kitchens & al [49]	2007	29	24 unilateral including 9 single kidneys 5 bilateral
Bouty in Mehdaoui thesis [17]	2016	18	18 unilateral including 1 single kidney 0 bilateral
Our series	2018	8	2 unilateral 6 bilateral

c. types of cutaneous ureterostomy:

Felderhof [28] compared the cutaneous loop ureterostomy with the Roux-en-Y ureterostomy, argued that although loop ureterostomy is an easy and relatively short operation, it exposes to nonfunctioning and contracted bladder. This serious complication is not seen after roux-en-Y ureterostomy.

Sarduy & al [27] reviewed 59 children with severe hydronephrosis managed by CU: 49 with LCU, and 12 with ECU. They conclude that the procedure is safe, quick, and effective in draining the kidney.

Rosen & al [50] have described LCU as easy to perform and is an excellent method for achieving temporary upper urinary tract drainage. ECU is suited for long-term or permanent urinary diversion in children with at least one dilated ureter

and can provide a socially acceptable stoma when delayed reconstruction is necessary.

In series of Kitchens & al [49], all the patients underwent end ureterostomies.

In our series, ECU was performed in 2 cases and ring ureterostomy in the remaining 6 patients.

Table 23: Table comparing types of ureterostomy

Authors	Year	Number of cases	Types of cutaneous ureterostomy
Felderhof [28]	1976	25	15 loop ureterostomies 10 Roux-en-Y ureterostomies
Sarduy & al [27]	1982	59	49 loop ureterostomies 12 End ureterostomies
Rosen & al [50]	1994	32	20 loop ureterostomies 12 End ureterostomies
Kitchens & al [49]	2006	29	29 End ureterostomies
Our series	2018	8	2 End ureterostomies 6 Ring ureterostomies

d. Indications of Cutaneous ureterostomy:

Rosen et al [50] separated the indications of ureterostomy according to its type:

LCU has as a main indication in obstructive uropathy unresponsive to lower urinary tract drainage whose most common etiology PUV. Other indications are: obstruction requiring delayed surgical correction, high grade reflux into a solitary kidney or, a hydroureteronephrosis complicated with infection or sepsis.

Indications for ECU are congenital anomalies of bladder, included prune-belly syndrome, 'Valve Bladder Syndrome', bladder exstrophy and urogenital sinus defect, it is most often indicated as a long term or permanent urinary diversion.

Liard & al [51] in their series including boys with PUV, underwent Sober ureterostomy

The indications for diversion were renal insufficiency, high grade reflux, deterioration of renal function despite valve resection, severe infection, severe dilation of the upper urinary tract and doubt about the functional value of 1 kidney.

In our series the indications of ureterostomy included: Severe dilatation of upper urinary tract, persistence of abnormalities after reimplantation, renal insufficiency and pyelonephritis.

Table 24: Comparative table of indications of ureterostomy.

Authors	Year	Number of cases	Indications of ureterostomy/ number of cases
Rosen & al [50]	1993	32	<ul style="list-style-type: none"> -Obstructive uropathy unresponsive to lower tract drainage: 14 cases -Obstruction requiring delayed surgical correction: 2 cases -Solitary kidney with reflux: 2cases -Obstruction with infection: 4 cases -Poor bladder function: 6 cases -High grade reflux into poorly functioning kidney: 4 cases
Liard & al [51]	2000	17	<ul style="list-style-type: none"> -Severe dilatation of upper urinary tract: 8 cases -Renal insufficiency: 5 cases -High grade reflux: 4 cases -Deterioration of renal function: 5 cases -Severe infection: 4 cases
Our series	2018	8	<ul style="list-style-type: none"> -Severe dilatation of upper urinary tract: 5 cases - persistence of abnormalities after reimplantation: 1 case Renal insufficiency: 2 cases -pyelonephritis: 1 case

e. **Duration of ureterostomy and age of closure:**

In the Kitchens & al series [49], the mean duration of ureterostomy and the age of closure was respectively 19.2 months and 36 months.

In our series, the mean duration was 16 months and the age of closure was 28 months.

Table 25: Comparison of durations of ureterostomy and age at closure.

Authors	Year	Duration of ureterostomy	Age at closure of ureterostomy
Kitchens & al [49]	2007	19.2 months	Mean age: 36 months
Our series	2018	16 months	Mean age: 28 months

f. Complications of ureterostomy:

In the pediatric population, ureterostomy has been under-indicated because of complications, including stenosis of the ureterostomy.

Liard & al [51] draining all patients with PUV with Sober ureterostomy noted 2 stomal stenosis and only 1 case of fistula after closure of the ureterostomy. In the Kitchens & al, all patients were drained by distal ureterostomy, and only 1 patient developed stenosis.

In our series, 1 patient developed fistula after closure of the ureterostomy.

Table 26. Comparison of complications of ureterostomy.

Authors	Number of cases	Complication of ureterostomy
Liard & al [51]	17	2 stomal stenosis 1 fistula (after closure)
Kitchens & al [49]	29	1 stenosis
Our series	8	1 fistula (after closure)

II. TRAUMATIC PATHOLOGY

A. Reminder

1. Urethral injuries

Pediatric urethral trauma is a rare injury that presents a challenge for urologist. Urethral injuries account for 3.4% of the children admitted with traumatic injuries of the genitourinary tract. The incidence is rare due to the fact that the urethra is short, mobile and protected by the pubic bone .Males more commonly sustain a urethral injury than females, with a mean age of 9 years old [52][53][54].

Any patient who has sustained a pelvic fracture or significant trauma to the perineum should be suspected to have an urethral injury until studies indicate otherwise. Signs of urethral injury include blood at the meatus, gross hematuria, severe pain on voiding, and inability to void. Perineal edema or hematoma involving the scrotum is also a sign of urethral injury. Any patient suspected to have an urethral injury should undergo a rectal examination to determine the position and fixation of the prostate. In membranous urethral injuries, the prostate and bladder may be displaced up out of the pelvis, and this is apparent on rectal examination [38].

Retrograde urethrography is considered the gold standard for diagnosis of urethral injuries.

a. Classification of traumatic urethral injuries:

Male urethral injuries can be classified as anterior and posterior:

- **Anterior urethral injuries (penile and bulbar urethra):** are caused by blunt trauma such as vehicular accidents such as falling astraddle on the crossbar of a bike or blows to the perineum from bicycle handlebars, tops of fences or kicks to the perineum.

The injury of the anterior urethra represents the predominant lesion type in boys. The incidence is ranging between 1.6% and 25% [5]. Characteristically, these traumas are straddle-type injuries infrequently associated with pelvic fractures. Predominantly, the bulbar urethra is concerned [55],[53].

- **Posterior urethral injuries (membranous and prostatic urethra):** are linked with pelvic fractures, most commonly caused by road traffic accidents, crush injuries and falls from height. The incidence of posterior urethra injury after pelvic fracture is uncommon with a reported frequency of 0.47–4.2% [52].

In contrast to adults, the intra-abdominal location of the bladder and the prepubescent smaller as well as more cranially placed prostate predispose to complete posterior urethral rupture in boys. Erectile dysfunction occurs in 20–60% of patients after traumatic posterior urethral rupture [55],[53].

Injuries vary from simple stretching (25%) to partial rupture (25%) to complete disruption (50%) [55].

Goldman Classification [56]

Even though many classifications have been proposed for urethral traumatic injuries, the most accepted scheme based on the results of retrograde urethrography is the Goldman classification. The scheme is divided into five types:

- **Type I:** Rupture of the puboprostatic ligament, the posterior urethra is intact, but stretched by the movement of the prostate and the neck of the bladder superiorly; therefore, no extravasation of contrast material is seen.

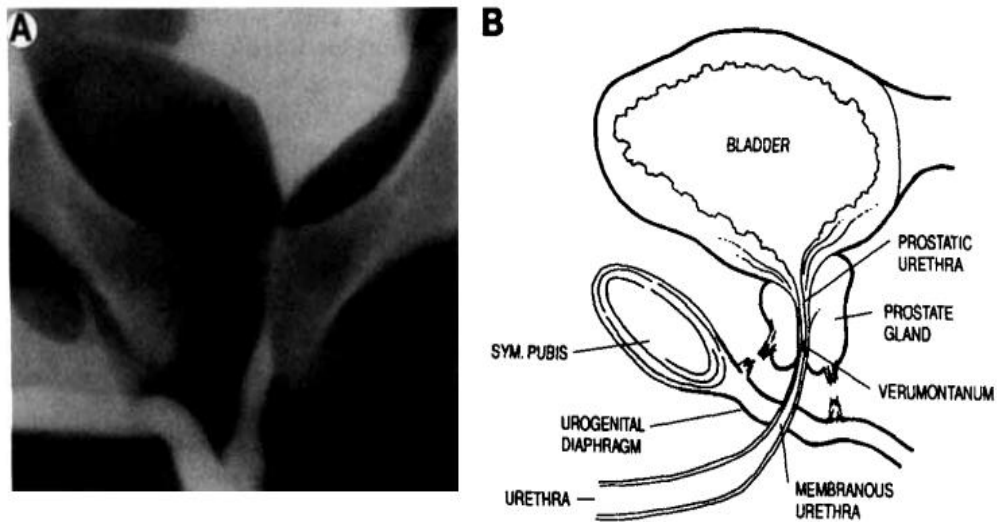


Figure 20. type I urethral injury.

Injury with posterior urethra stretched but intact.

A. Retrograde urethrogram reveals hematoma indenting bladder base.

B. Posterior urethral stretching after rupture of puboprostatic ligaments.

- **Type II:** Partial or complete posterior urethral injury in which the tear of the membranous urethra is found above the urogenital diaphragm; contrast-agent extravasation is seen within the extra peritoneal pelvis.

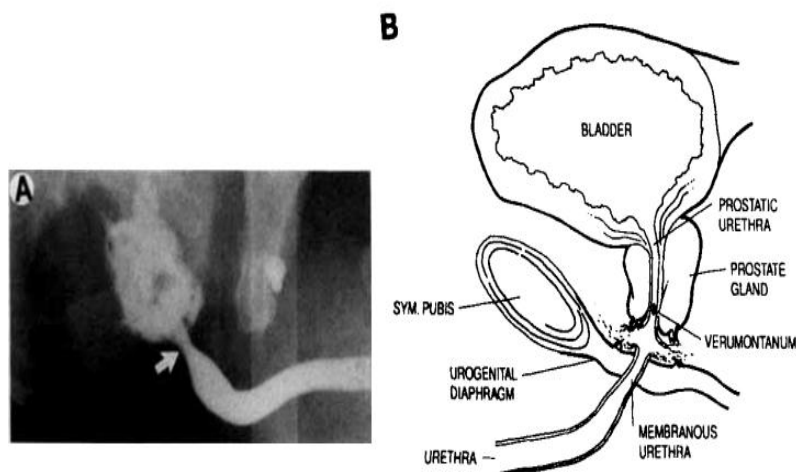


Figure 21. type II urethral injury.

A and B type 2 injury with urethra ruptured above intact urogenital diaphragm.

Retrograde urethrogram demonstrates extravasation above intact membranous urethra.

- **Type III:** Partial or complete posterior urethral injury with disruption of the urogenital diaphragm including the proximal bulbous urethra leading to an extravasation not only within the extraperitoneal pelvis, but also with in the perineum.

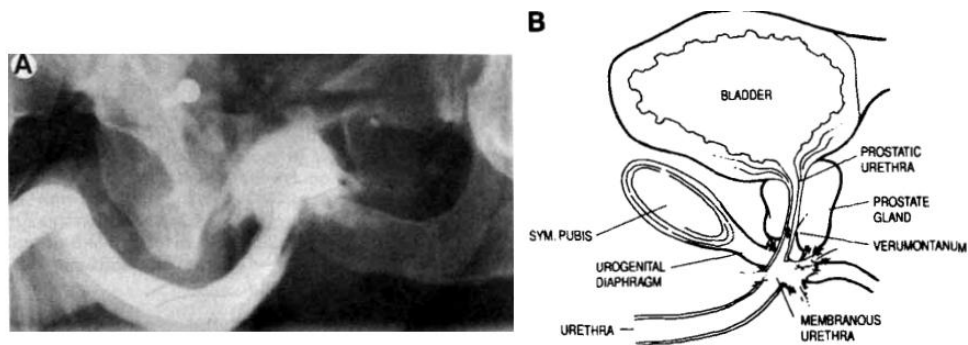


Figure 22. Type III urethral injury.

A and B: type 3 injury extending through urogenital diaphragm to involve proximal bulbous urethra. Retrograde urethrogram reveals contrast extravasation below urogenital diaphragm into perineum surrounding proximal bulbous urethra.

- Type IV: Bladder neck injury with extension into the proximal urethra; the contrast-agent extravasation is found in the extraperitoneal pelvis just about the bladder neck and periurethrally.

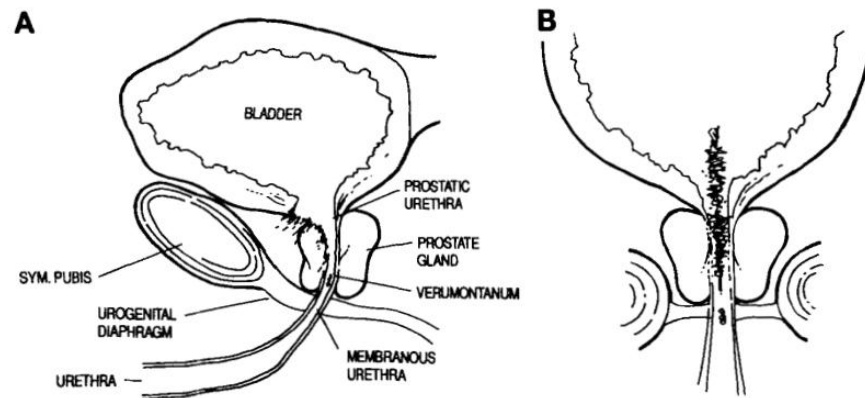


Figure 23. Type IV urethral injury.

A. lateral view.

B. anteroposterior view.

If only the bladder base without extension into the urethra is injured, a type IVA can be distinguished.

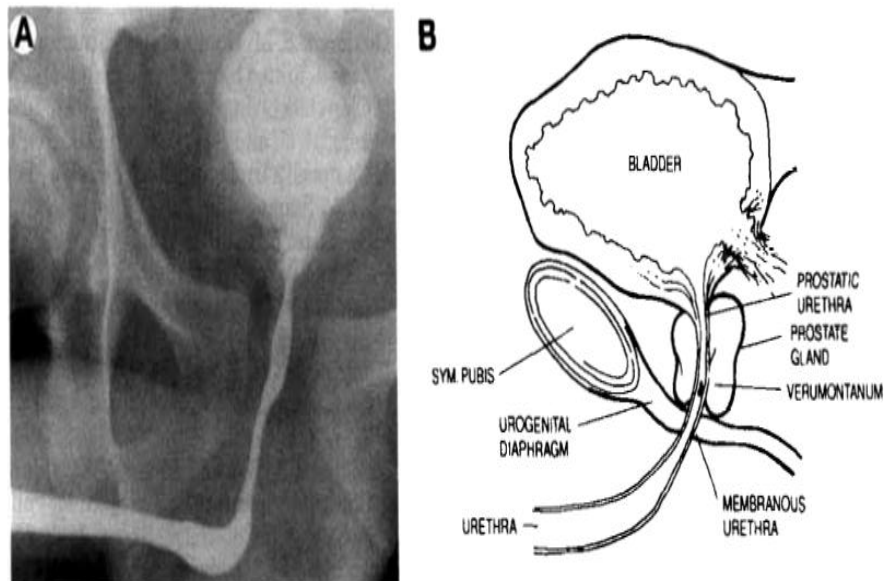


Figure 24. Type IVA.

A and B: Retrograde urethrogram shows contrast extravasation from bladder base surrounding proximal prostatic urethra and diastasis of the symphysis pubis. This injury represents extraperitoneal bladder rupture but extension of injury into proximal urethra cannot be excluded on radiographic study.

- **Type V:** Partial or complete injury confined to the anterior urethra, hence extravasation is present inferior to the urogenital diaphragm. Only after disruption of the deep layer of the penile fascia, contrast agent is issued within the borders of the dartos fascia.

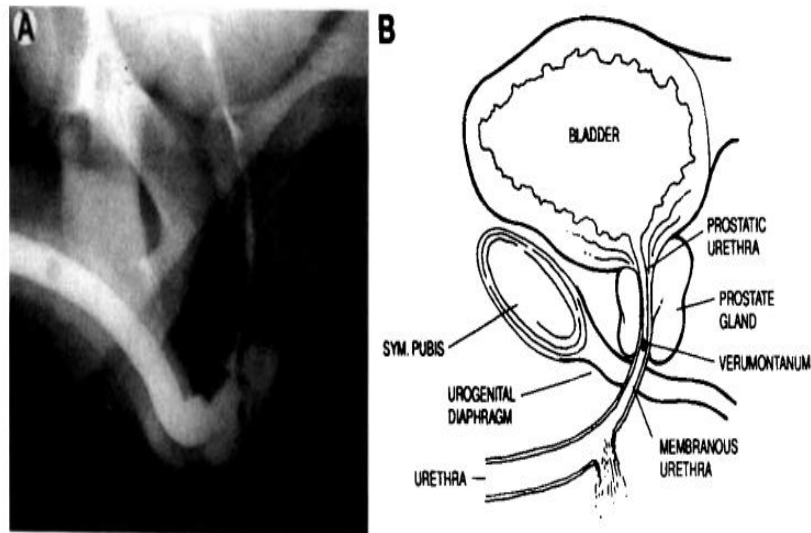


Figure 25. Anterior urethral injury.

A and B: Retrograde urethrogram demonstrates partial injury involving proximal bulbous urethra.

This classification is more appropriate because it is anatomically correct. It does not mix anatomical grouping with categorizations based on the mechanism of injury. Consequently, this approach is easy for physicians in urology, radiology and emergency medicine to understand, use and remember.

b. Management of traumatic urethral injuries:

Management of urethral injuries remains controversial because it depends on the site, type, and extent of the injury. In addition, most urologists have little experience with these injuries and there is a lack of randomized prospective trials[55]. The management entails different techniques including primary urethral realignment, endoscopic realignment and delayed repair after temporary diversion by suprapubic cystostomy. [57]

The initial management is to obtain drainage of the bladder by suprapubic cystostomy, which assures not only a safe urinary diversion, but also prevents urine extravasation at the site of injury.

The management of posterior urethral injuries differs from the management of injuries of the bulbous urethra because of associated severe injuries and the amount of tissue damage resulting from trauma to the posterior urethra. Bulbous urethral or straddle injuries are often uncomplicated by associated injuries to other systems and cause minor tissue damage. The management of bulbous urethral injuries is simple and involves either observation or urethral catheter drainage to prevent urethral bleeding or painful voiding.

Often the patient has minor dysuria and transient hematuria. Straddle injuries often resolve without the patient being evaluated by a physician and come to light later when a stricture develops at the injury site.

The initial management of injuries to the posterior urethra is not so straightforward and produces considerable ongoing controversy.

Contusions can be safely treated with an indwelling transurethral catheter for 7 days.

Partial disruptions are best treated with bladder drainage via suprapubic cystostomy. In selected cases of posterior partial disruptions, primary endoscopic urethral realignment may be attempted; if successful, this approach may limit subsequent urethral strictures.

Complete disruptions usually are treated with bladder drainage via suprapubic cystostomy. This option is simplest and can be used safely in all patients.

Definitive surgery is deferred for about 8 to 12 wk. until the urethral scar tissue has stabilized and the patient has recovered from any accompanying injuries.

Long term sequelae of urethral injury are: stricture, urethrocutaneous fistulae, urinary incontinence and erectile dysfunction.

The immediate result of suprapubic drainage alone is stricture formation of the injured portion of the posterior urethra in 97% of cases. The occasional patient who does not form a stricture probably represents an unrecognized partial urethral injury that healed spontaneously. As urethrocutaneous fistula, periurethral diverticula, urethral stricture, incontinence and impotence [53].

2. **Bladder injuries**

The bladder is the largest organ in the urinary tract when it is full of urine. It is well protected in adults because it lies within the confines of the bony pelvis. The rigid pelvic ring and the rectus abdominis muscle guard it. The bladder occupies a less protected position in infants and children; it is a more abdominal organ and lies exposed above the pubis, although the pelvic bones are not fully developed, making the bladder more easily injured than in the adult.

Bladder injuries are more likely in patients who have multiple pelvic fractures, including a widened symphysis pubis and sacroiliac joint and fractures of the sacrum.

a. Clinical presentation and diagnosis of bladder injuries:

- ❖ Clinical signs of bladder injury are relatively nonspecific; however, a triad of symptoms is often present: gross hematuria, suprapubic or abdominal pain or tenderness, and difficulty in voiding or inability to void.
- ❖ All patients with bladder injury have significant micro hematuria, and gross hematuria occurs in 95%. Of patients with the findings of pelvic fracture and gross hematuria, 45% have bladder rupture. Bladder injuries seldom occur in isolation and are most often associated with multiple organ injuries, such as closed head trauma, other solid organ injuries, and severe hemorrhage. This accounts for the high mortality of 20% to 40% in patients with bladder rupture.
- ❖ The diagnosis of bladder injuries can be difficult and relies on filling the bladder retrograde through a catheter with contrast fluid and imaging with either standard radiographs or computed tomography scans.

CT cystography is the current best investigation for assessing traumatic bladder injury. The bladder should be imaged when fully distended and after drainage. CT scanning of the bladder even with a clamped Foley catheter, if filled with contrast fluid excreted from the kidneys, is unreliable because the bladder is not forcibly distended. Spiral CT scanning has not provided more accuracy unless the bladder is filled in a retrograde manner.

b. Mechanism and classification: **Mechanism**

Of all bladder injuries, 60% to 85% are from blunt trauma and 15% to 40% are from penetrating injuries [58],[59].

Blunt trauma is the more common mechanism: The exposed position of the bladder in children makes it more susceptible to blunt trauma when the bladder is full. This type of injury has been seen most often in motor vehicle accidents when the child is wearing a lap seat belt.

The most frequently accompanying injury is a Pelvic Fractures , occurring in > 95% of bladder ruptures caused by blunt trauma. Other concomitant injuries include long bone fractures and CNS and chest injuries.

Penetrating injuries, most often gunshot wounds, account for < 10% of bladder injuries.

Gunshot wounds are the most common type of penetrating bladder injury followed by stabbings. Associated traumatic injuries are common, and the mortality is 12% to 22% secondary to those extra urinary injuries. Injuries to the recto sigmoid, small bowel, and iliac vessels are the most common associated injuries.

Penetrating bladder trauma requires surgical exploration and repair. In the case of gunshot wounds, debridement of nonviable bladder tissue surrounding the wound is usually necessary. The perivesical space and the bladder should be drained. Pelvic hematoma and fecal contamination from rectal injuries may complicate these wounds. Simultaneous diversion of the bowel is common in multisystem complicated injury.

☑ **Classification**

Blunt injury to the bladder is categorized as either a contusion or a rupture.

-Bladder contusions:

Bladder contusions, or a “bruised bladder,” are relatively benign, and this is usually a diagnosis of exclusion. It is described as damage to the bladder mucosa or muscle without loss of bladder wall continuity or extravasation of urine.

Bladder contusions can have transient hematuria or may even be clinically silent; however, the amount of hematuria does not indicate the degree of bladder injury. Nor does the ability to urinate exclude bladder injury or perforation. Bladder contusions are much more frequent and, can present with no clinical signs, thereby making their incidence truly unknown because they can go undiagnosed. Contusions account for one third (1/3) of all bladder injuries and are treated with catheter drainage alone. The catheter is left in place until gross hematuria clears in most cases. It is unnecessary to image the bladder after the catheter is removed if the patient voids normally.

- Bladder ruptures

With bladder ruptures, an abdominal examination may reveal signs of peritoneal irritation, which include distention, guarding, and rebound tenderness.

Bladder ruptures are described as either intraperitoneal, extraperitoneal or both, and differ in the site of injury, mechanism of injury, and treatment.

- ❖ Intraperitoneal bladder rupture is more common in children because of the more exposed position of the bladder. The filled bladder is struck, and the acute increase in pressure caused by the trauma against the closed bladder neck causes the bladder to rupture at its weakest and most mobile point, the dome. The dome of the bladder is covered only by peritoneum, and a forceful tear in this area results in a communication with the

peritoneal cavity. The diagnosis is made when the cystogram reveals contrast fluid within the peritoneal cavity classically outlining loops of bowel. These injuries account for one third of all bladder ruptures.

The accepted management of intraperitoneal bladder rupture is open surgical exploration and primary repair. This is considered an urgent procedure and includes irrigation of the peritoneal cavity. The peritoneal cavity is not drained, but the bladder is drained with either a suprapubic tube or a urethral catheter.

- ❖ The second type of bladder rupture is extraperitoneal, and it occurs in the lower half of the bladder and is almost exclusively associated with pelvic fractures. With disruption of the bony pelvic ring, the bladder is torn on the lateral inferior wall and may be lacerated or penetrated with bone fragments. The cystogram reveals extravasation of contrast material into the peri vesical soft tissues in a typical flame pattern, but the contrast material is confined to the pelvis.

Almost all patients with extraperitoneal bladder ruptures are treated nonoperatively with urethral catheter drainage for 7 to 10 days.

c. Complications

Complications of bladder injuries include uroascites (free urine in the peritoneal cavity) due to intraperitoneal rupture, infection (including Sepsis and Septic Shock), persistent haematuria, Urinary Incontinence in Adults, bladder instability, and fistula.

Complications occur when bladder drainage is not maintained, and persistent extravasation occurs. Use of broad-spectrum antibiotics helps avoid the serious complications of infection.

3. Initial management

Table 27. Observations of patients with traumatic urethral and bladder injuries.

Patient	Observation
<u>P1</u>	A 10-year-old male was diagnosed with posterior urethral injury after being hit by a car. Initially a suprapubic cystostomy was done. 2 months later, an urethrocytography done returned normal and a cystostomy closure was performed
<u>P2</u>	An 11-year-old male was diagnosed with urethral trauma due to a pelvic fracture after being hit by a truck. An abdominal and pelvic CT was done, on its results a suprapubic cystostomy was performed. 4 months later, an urethrocytography done showed a complete stenosis of the bulbar urethra and he underwent serial urethral dilations.
<u>P3</u>	An 11-year-old male was diagnosed with bladder rupture after a road accident. Initially, a suprapubic cystostomy was done. 5 months later, an urethrocytography done returned normal and a cystostomy closure was performed.

Therefore, in our series, all patients underwent an immediate management by suprapubic cystostomy and no primary realignment was done.

Suprapubic cystostomy and delayed repair was first advocated by **Johanson in 1953** [54]. Despite the high rate of stricture formation, perceived advantages of this technique include avoiding entry into the pelvic hematoma with the risk of infection and excessive blood loss, speed and simplicity of suprapubic tube placement, and avoiding acute mobilization of the prostate and urethra with resultant lower impotence and incontinence rates.

Some authors report the indication of Primary realignment (first described by Clark & al in 1992) vs. Suprapubic cystostomy for the management of posterior urethral injuries:

Londrgan & al [60] reported six patients with severe traumatic urethral injuries treated successfully with early fluoroscopic realignment: they affirmed that primary realignment may be safe and effective treatment option for traumatic urethral injuries.

Barrett & al [5] compared PR with SPC for the management of pelvic fracture-associated posterior urethral injuries with regards to rates of stricture, erectile dysfunction and urinary incontinence. They conclude that PR appears to reduce the incidence of stricture formation after pelvic fracture-associated posterior urethral injuries as compared with SPC.

Pontes & Pierce [60] reported that urinary diversion could possibly be the only required treatment because most traumatic injuries to the anterior urethra are partial disruptions.

CONCLUSION

Urinary diversions are methods of external urinary drainage proposed as temporary surgical treatments for malformative uropathy and emergency treatment of traumatic pathology which cause a dilation of the upper urinary tract, when the conditions do not allow a radical cure of the pathology.

This retrospective study looking at 40 cases of incontinent urinary diversions Colligated from department of pediatric surgery university Hassan II hospital-Fez between 2013 and 2017 (4 years) stated several points that concord with the literature and others that discord. Furthermore, this work allowed us to focus on the benefits and limitations of incontinent urinary diversions, even if it doesn't allow us to draw conclusions given the nature of the study (retrospective) and the sample size, but just to make findings.

Our work allows us to conclude that urinary diversion protect the upper urinary tract, reduce ureterohydronephrosis, and improve kidney function.

These are simple surgeries, with few complications.

ABSTRACT

Abstract

Incontinent urinary diversion for management of malformative uropathy and traumatic pathology in children (a review of 40 cases).

Introduction: Urinary diversion is defined as the surgical diversion of urine from the urinary tract, and it can be performed at all levels: Cutaneous Vesicostomy for bladder, Cutaneous ureterostomy for ureters and percutaneous nephrostomy for kidney.

Although studies on the advantages and disadvantages of this surgeries have been widely used in the international literature, it is clear that this type of study is little discussed in the Moroccan context.

Purpose: to evaluate the interest and importance of urinary tract diversion in malformative uropathy and traumatic pathology.

Materials and methods: We performed a retrospective study in the department of Pediatric surgery in Hassan II University Hospital–Fez, of 40 children who underwent incontinent urinary diversion for management of their congenital urologic disease, and traumatic pathology during 4 years.

Results: We evaluate 40 children (35 males and 5 females) who underwent incontinent urinary diversion.

37 patients had malformative uropathy: We found 17 boys with posterior urethral valves, 10 patients with primary megaureter, and 8 with neurogenic bladder.

Of 37 patients: 29 underwent cutaneous vesicostomy, 5 cutaneous ureterostomy, 3 cutaneous vesicostomy and cutaneous ureterostomy. To report that no percutaneous nephrostomy was done.

The indications for diversion were severe ureterohydronephrosis, vesical

dysfunction and renal function deterioration. During IUD, ureterohydronephrosis improved in 24 patients (65%). 29 children improved their renal functions besides 5 who developed chronic renal failure. The recurrent urinary tract infections didn't decrease significantly with IUD.

The complications were few, stomal stenosis was found in 7 cases. Parents believe that IUD has a good effect in improving general state of their children, however they are not pleased with the stoma.

3 patients with traumatic urethral and bladder injuries (1 bladder rupture and 2 posterior urethral injuries) underwent an immediate management with CV with a mean duration of 7.6 months. Overall, one patient developed symptomatic urethral stricture (33% of cases).

Conclusion: incontinent urinary diversion protects the upper urinary tract, reduce ureterohydronephrosis, and improve kidney function. These are simple surgeries, with few complications.

Key-words: urinary diversion, nephrostomy, vesicostomy, ureterostomy, malformative uropathy, Urethral injuries, Bladder injuries.

Résumé

Les dérivations urinaires incontinentes dans la prise en charge des uropathies malformatives et des pathologies traumatiques de l'enfant (à propos de 40 cas).

Introduction : La dérivation urinaire incontiente est définie comme étant la dérivation chirurgicale de l'urine des voies urinaires. Elle peut être pratiquée à tous les niveaux : on la qualifie de vésicostomie lorsqu'il s'agit d'une dérivation vésicale, et d'urétérostomie pour une dérivation urétérale alors que pour une dérivation rénale il s'agit d'une néphrostomie percutanée.

Bien que les études portant sur les avantages et inconvénients de cette chirurgie aient connues un grand essor dans la littérature internationale, force est de constater que ce genre d'étude sont peu aborder au niveau du contexte marocain.

Objectif : évaluer l'intérêt et l'importance des dérivations urinaires dans les pathologies malformatives et traumatiques de l'enfant. Et ce, dans le contexte marocain.

Matériels et méthodes : Nous avons mené une étude rétrospective dans le département de chirurgie pédiatrique de l'hôpital universitaire Hassan II de Fès, chez 40 enfants qui ont subi une dérivation urinaire incontiente pour la prise en charge de leur maladie urologique congénitale, et leur pathologie traumatique pendant 4 ans.

Résultats : 40 enfants ont été évalué (35 garçons et 5 filles). 37 patients ont été suivis pour uropathie malformative, dont 17 garçons avec des valves de l'urètre postérieur, 10 patients avec un mégauretère, 8 avec une vessie neurologique. Sur 37 patients : 29 ont eu une vésicostomie, 5 une urétérostomie, 3 une vésicostomie et urétérostomie, à signaler qu'aucune néphrostomie percutanée n'a été pratiquée.

Les indications de dérivation étaient une urétérohydronephrose sévère, un dysfonctionnement vésical et une détérioration de la fonction rénale.

Au cours de la dérivation, l'urétérohydronephrose s'est améliorée chez 24 patients, soit 65% de la population étudiée. En effet, la fonction rénale s'est améliorée chez 29 enfants et 5 ont développé une insuffisance rénale chronique alors que les infections récurrentes des voies urinaires n'ont pas diminué de manière significative avec la dérivation. Les complications étaient rares, une sténose a été retrouvée dans 7 cas. Les parents pensent que la dérivation améliore l'état général de leurs enfants néanmoins ils ne sont pas satisfaits des stomies.

Trois patients présentant des lésions traumatiques de l'urètre et de la vessie (1 rupture de la vessie et 2 lésions de l'urètre postérieur) ont subi une prise en charge immédiate par une vésicostomie d'une durée moyenne de 7,6 mois. Dans l'ensemble, un patient a développé une sténose de l'urètre (33% des cas).

Conclusion : les dérivations urinaires incontinentes protègent les voies urinaires supérieures, réduisent l'urétérohydronephrose et améliorent la fonction rénale. Ce sont des chirurgies simples, avec peu de complications.

Mots-clés : dérivation urinaire, néphrostomie, vésicostomie, urétérostomie, uropathie malformative, lésions urétrales, blessure de la vessie.

ملخص

التحويلات البولية عند الطفل

(بصدد 40 حالة)

مقدمة:

يتم تعريف التحويلات البولية على أنها تحويلات جراحية للبول من المسالك البولية. يمكن تطبيقها على جميع المستويات، فتسمى: فغر المثانة عندما يتم التحويل على مستوى المثانة، فغر الإحليل حين تتم على مستوى الإحليل، فغر الكلية حين تتم على مستوى الكلية.

الأهداف:

تقييم الهدف من التحويلات البولية وآثارها السلبية.

المواد والأساليب:

قمنا في هذا الصدد بدراسة تراجعية في قسم جراحة الأطفال في المستشفى الجامعي الحسن الثاني بفاس لـ 40 طفل خضعوا لإحدى التحويلات البولية على مدى أربع سنوات.

النتائج:

قمنا بتقييم 40 طفل (35 ولد و05 فتيات).

37 حالة كانت تعاني من تشوهات الجهاز البولي، من بينها 17 طفل يحملون صمام الإحليل الخلفي،

10 أطفال يحملون توسع الحالب، و8 يحملون المثانة العصبية.

في هاته الحالات تم فغر المثانة لـ 29 حالة، فغر الإحليل لـ 5 حالات، فغر المثانة والإحليل معا لـ 3

حالات، مع العلم أنه لم يتم فغر الكلية لأية حالة.

كانت دواعي القيام بجراحة تحويلية كالتالي:

موه شديد في الكلية والحالب، ضعف المثانة وتدهور وظيفة الكلي.

خلال التحويلات البولية تراجع امتصاص الكلي والحالب عند 24 طفل ما يمثل 65% من الحالات

المدروسة، كما تحسنت الوظيفة الكلوية عند 29 طفل بنما تدهورت الحالة إلى قصور كلوي عند 5 أطفال فيما لم

يشهد تكرار عدوى المسالك البولية تحسنا ملحوظا رغم القيام بالتحويلات.

عبر غالبية الآباء عن رضاهم حيال الصحة العامة لأطفالهم رغم عدم رضاهم عن فوهة التحويلات.

خضع 3 أطفال يعانون من صدمات على مستوى مجرى البول والمثانة جراء حوادث (1 تمزق المثانة،
2 جرح على مستوى الإحليل الخلفي) لفغر مثانة فوري مع متوسط مدة 7.6 شهر. في المجمل عانى طفل واحد
من تضيق الإحليل (33%).

خاتمة:

التحويلات البولية تحمي المسالك البولية العليا، تخفض موه الكلية وتحسن عملها، إنها جراحات بسيطة مع
ندرة المضاعفات.

الكلمات الأساسية:

التحويلات البولية - فغر المثانة - فغر الإحليل - فغر الكلي - تشوهات المسالك البولية - جرح المثانة - جرح
مجرى البول.

BIBLIOGRAPHY

- [1] J. D. Browning and H. A. Stephany, "Advances in Pediatric Urinary Diversion," *Urol. Clin. North Am.*, vol. 45, no. 1, pp. 123-132, 2018.
- [2] J. Guys, A. Camerlo, and G. Hery, "Vessies neurologiques de l' enfant : approche diagnostique et thérapeutique," vol. 11, no. 15392, pp. 1-12, 2013.
- [3] N. Becker and E. D. Avner, "Congenital nephropathies and uropathies," *Pediatr. Clin. North Am.*, vol. 42, no. 6, pp. 1319-1341, 1995.
- [4] H. Otukesh *et al.*, "Long-term upper and lower urinary tract functions in children with posterior urethral valves," *J. Pediatr. Urol.*, vol. 6, no. 2, pp. 143-147, 2010.
- [5] K. Barrett, L. H. Braga, F. Farrokhyar, and T. O. Davies, "Primary realignment vs suprapubic cystostomy for the management of pelvic fracture-associated urethral injuries: A systematic review and meta-analysis," *Urology*, vol. 83, no. 4, pp. 924-929, 2014.
- [6] W. Farhat, G. M. C. Lorie, G. Capolicchio, P. A. Merguerian, A. Khoury, and D. Ba, "Outcomes of Primary Valve Ablation Versus Posterior Urethral Valves," *Urology*, vol. 4295, no. January 1995, pp. 653-657, 1998.
- [7] C. S. Lukong *et al.*, "Role of vesicostomy in the management of posterior urethral valve in Sub-Saharan Africa," *J. Pediatr. Urol.*, vol. 10, no. 1, pp. 62-66, 2014.
- [8] S. Martini, C. Fischer, and J. P. Guignard, "Reflux vésico-urétéral chez l' enfant : connaissances actuelles et recommandations," pp. 346-349, 2002.
- [9] N. Kahloul, L. Charfeddine, R. Fatnassi, and F. Amri, "Les uropathies malformatives chez l'enfant: À propos de 71 cas," *J. Pediatr. Pueric.*, vol. 23, no. 3, pp. 131-137, 2010.
- [10] E. Merlini and P. Spina, "Primary non-refluxing megaureters," *J. Pediatr. Urol.*, vol. 1, no. 6, pp. 409-417, 2005.

- [11] M. L. Diakité *et al.*, "Le mégauretère primitif de type obstructif : Stratégies thérapeutiques à propos de 30 cas," *African J. Urol.*, vol. 19, no. 2, pp. 107–112, 2013.
- [12] E. Fontaine, S. Ben Mouelli, and D. Beurton, "Chirurgie du méga-uretère obstructif primitif de l'enfant ou de l'adulte," no. 194365, 2018.
- [13] C. L. Enfant, P. L. Obtention, D. U. Doctorat, and E. N. Medecine, "LES ASPECTS ÉVOLUTIFS DU MÉGA-URETÈRE CHEZ L'ENFANT (A propos de 62 cas)," 2018.
- [14] P. Wang, O. Djahangirian, and E. Wehbi, *Urinary Tract Infections and Vesicoureteral Reflux*, Tenth Edit. Elsevier Inc., 2017.
- [15] S. Çelebi *et al.*, "Reliability of the Grading System for Voiding Cystourethrograms in the Management of Vesicoureteral Reflux: An Interrater Comparison," *Adv. Urol.*, vol. 2016, 2016.
- [16] M. Peycelon and G. Audry, "Place de la chirurgie dans la prise en charge du reflux vésico-urétéral de l'enfant," *Arch. Pediatr.*, vol. 16, no. 12, pp. 1598–1602, 2009.
- [17] M. A. Siham, "INTERET DES URETEROSTOMIES DANS LA PRISE EN CHARGE DES UROPATHIES MALFORMATIVES CHEZ L'ENFANT (A propos de 19 cas)," 2016.
- [18] M. A. Rossleigh, "Renal Infection and Vesico-Ureteric Reflux," *Semin. Nucl. Med.*, vol. 37, no. 4, pp. 261–268, 2007.
- [19] R. Mathews and T. K. Mattoo, "Vesicoureteral Reflux," *Compr. Pediatr. Nephrol.*, pp. 549–559, 2008.
- [20] M. M. Rodriguez and M. M. Rodriguez, "Congenital Anomalies of the Kidney and the Urinary Tract (CAKUT) Congenital Anomalies of the Kidney and the Urinary Tract (CAKUT)," vol. 3815, 2014.

- [21] H. Y. Wu, L. S. Baskin, and B. A. Kogan, "Neurogenic bladder dysfunction due to myelomeningocele: Neonatal versus childhood treatment," *J. Urol.*, vol. 157, no. 6, pp. 2295–2297, 1997.
- [22] M. I. Raqui, "les dérivations urinaires incontinentes chez l'enfant (A propos de 27 cas)," 2017.
- [23] A. C. Rhee, E. B. Yerkes, and R. C. Rink, *CHAPTER 118 Incontinent and Continent Urinary Diversion*, 7th ed. Elsevier Inc.
- [24] R. B. Nerli, R. A. Patil, K. Foundation, and K. Prabhakar, "Revised Blocksom vesicostomy: Operative steps," pp. 58–60, 2017.
- [25] J. Lapidés, E. P. Ajemian, and J. O. H. N. R. Lichtwardt, "CUTANEOUS VESICOSTOMY," pp. 1147–1151, 2002.
- [26] P. S. Int, "Vesicostomy in childhood : indications and results," pp. 348–350, 1996.
- [27] J. P. Smith and H. A. W. li, "Results in Children Managed by cutaneous ureterostomy," vol. XIX, no. 5, pp. 0–2, 1982.
- [28] B. J. Felderhof and S. Cass, "Cutaneous Loop Versus Roux–en–Y Ureterostomy: A Comparison of Two Methods for Diversion of Urine," vol. 11, no. 4, pp. 527–531, 1976.
- [29] A. TI and E. S. Tank, "LOOP CUTANEOUS URETEROSTOMY IN INFANCY," pp. 1–5, 1976.
- [30] R. Ureterostomy, "Ring Ureterostomy," pp. 789–792, 1976.
- [31] S. Ghazal, "EXPERIENCE WITH THE SOBER URETEROSTOMY," vol. 112, 1974.
- [32] R. D. Mahmood, L. Yizhi, and M. T. M. L, "Percutaneous Nephrostomy," 2003.
- [33] S. Laurin, S. Sandstrm, and H. Ivarsson, "Percutaneous Nephrostomy in Infants and Children," pp. 526–529, 2000.

- [34] G. Podevin, G. Levard, M. Marechaud, F. Girault, and D. Barret, "Strategie diagnostique postnatale des uropathies malformatives depistees avant la naissance," *Arch. Pediatr.*, vol. 4, no. 5, pp. 411–415, 1997.
- [35] M. Cassart, "Mise au point postnatale des dilatations des voies urinaires de diagnostic anténatal," *J. Radiol.*, vol. 92, no. 2, pp. 125–133, 2011.
- [36] P. Cochat, F. Cazet, A. Liutkus, C. Mourani, J. Exantus, and C. Akatchерian, "Néphrologie pédiatrique dans les pays en développement," *Arch. Pediatr.*, vol. 12, no. 6, pp. 723–725, 2005.
- [37] H. P. Huang, Y. C. Lai, I. J. Tsai, S. Y. Chen, and Y. K. Tsau, "Renal Ultrasonography Should Be Done Routinely in Children with First Urinary Tract Infections," *Urology*, vol. 71, no. 3, pp. 439–443, 2008.
- [38] G. rink Mouriquand, *pediatric urology*. 2011.
- [39] M. Rouzrokh, A. Mirshemirani, and A. Khaleghnejad–tabari, "Protective Temporary Vesicostomy for Upper Urinary Tract Problems in Children : A Five–Year Experience," vol. 23, no. 6, pp. 648–652, 2013.
- [40] M. K. Farrugia, R. Hitchcock, A. Radford, T. Burki, A. Robb, and F. Murphy, "British Association of Paediatric Urologists consensus statement on the management of the primary obstructive megaureter," *J. Pediatr. Urol.*, vol. 10, no. 1, pp. 26–33, 2014.
- [41] M. P. Hiorns, "Imaging of the urinary tract: The role of CT and MRI," *Pediatr. Nephrol.*, vol. 26, no. 1, pp. 59–68, 2011.
- [42] R. de Bruyn and S. D. Marks, "Postnatal investigation of fetal renal disease," *Semin. Fetal Neonatal Med.*, vol. 13, no. 3, pp. 133–141, 2008.
- [43] P. Vajda and R. Somogyi, "Cutaneous Vesicostomy Revisited – the Second 15 Years," 2005.

- [44] M. M. and L. D. Prudente A, Reis L O, de Paula França R, “Vesicostomy as a protector of upper urinary tract in long-term follow-up,” *Urol. J.*, pp. 96–100, 2009.
- [45] P. Godbole, A. Wade, I. Mushtaq, and D. T. Wilcox, “Vesicostomy vs primary ablation for posterior urethral valves: Always a difference in outcome?,” *J. Pediatr. Urol.*, vol. 3, no. 4, pp. 273–275, 2007.
- [46] J. C. Hutcheson, C. S. Cooper, D. A. Canning, S. A. Zderic, and H. M. Snyder, “THE USE OF VESICOSTOMY AS PERMANENT URINARY DIVERSION IN THE CHILD WITH MYELOMENINGOCELE,” vol. 166, no. December, pp. 2351–2353, 2001.
- [47] M. İ. Dönmez, A. Carrasco, A. F. Saltzman, V. Vemulakonda, and D. T. Wilcox, “Long-term outcomes of cutaneous vesicostomy in patients with neuropathic bladder caused by spina bifida,” *J. Pediatr. Urol.*, vol. 13, no. 6, p. 622.e1–622.e4, 2017.
- [48] H. M. Snyder, M. A. Kalichman, E. Charney, and J. W. Duckett, “VESICOSTOMY FOR NEUROGENIC BLADDER WITH SPINA BIFIDA : FOLLOWUP,” vol. 130, pp. 724–726, 1983.
- [49] D. M. Kitchens *et al.*, “End Cutaneous Ureterostomy for the Management of Severe Hydronephrosis,” *J. Urol.*, vol. 177, no. 4, pp. 1501–1504, 2007.
- [50] M. A. Rosen, D. R. Roth, and E. T. J. Gonzales, “Current indications for cutaneous ureterostomy.,” *Urology*, vol. 43, no. 1, pp. 92–96, 1994.
- [51] P. Mitrofanoff, “TEMPORARY HIGH DIVERSION FOR POSTERIOR URETHRAL VALVES,” vol. 164, no. July, pp. 145–148, 2000.
- [52] B. B. Voelzke, B. N. Breyer, and J. W. McAninch, “Blunt pediatric anterior and posterior urethral trauma: 32-year experience and outcomes,” *J. Pediatr. Urol.*, vol. 8, no. 3, pp. 258–263, 2012.

- [53] R. Pichler *et al.*, “Diagnosis and management of pediatric urethral injuries,” *Urol. Int.*, vol. 89, no. 2, pp. 136–142, 2012.
- [54] R. T. da S. Ugino *et al.*, “Management of traumatic urethral injuries in children using different techniques: A case series and review of literature,” *Int. J. Surg. Case Rep.*, vol. 40, pp. 85–89, 2017.
- [55] L. Martínez-Piñeiro *et al.*, “EAU Guidelines on Urethral Trauma,” *Eur. Urol.*, vol. 57, no. 5, pp. 791–803, 2010.
- [56] S. M. Goldman, C. M. Sandler, J. N. Corriere, and E. J. McGuire, “Blunt urethral trauma: A unified, anatomical mechanical classification,” *J. Urol.*, vol. 157, no. 1, pp. 85–89, 1997.
- [57] S. Orabi, H. Badawy, A. Saad, M. Youssef, and A. Hanno, “Post-traumatic posterior urethral stricture in children: How to achieve a successful repair,” *J. Pediatr. Urol.*, vol. 4, no. 4, pp. 290–294, 2008.
- [58] I. Guttman and H. A. Kerr, “Blunt Bladder Injury Bladder rupture Bladder contusion Hematuria,” *Clin. Sports Med.*, vol. 32, no. 2, pp. 239–246, 2013.
- [59] R. J. Urry, D. L. Clarke, J. L. Bruce, and G. L. Laing, “The incidence , spectrum and outcomes of traumatic bladder injuries within the Pietermaritzburg Metropolitan Trauma Service,” *Injury*, vol. 7084, 2016.
- [60] M. S. Lee, S. H. Kim, B. S. Kim, G. M. Choi, and J. S. Huh, “The Efficacy of Primary Interventional Urethral Realignment for the Treatment of Traumatic Urethral Injuries,” *J. Vasc. Interv. Radiol.*, vol. 27, no. 2, pp. 226–231, 2016.