



ⵜⴰⵎⴻⵔⴰⵏⵜ ⴱⴰⵔⴰⵏ ⴱⴰⵏ ⴱⴰⵔⴰⵏ
Université Sidi Mohamed Ben Abdellah

YEAR 2020

Royaume du Maroc المملكة المغربية

كلية الطب والصيدلة
ⵜⴰⵎⴻⵔⴰⵏⵜ ⴱⴰⵔⴰⵏ ⴱⴰⵏ ⴱⴰⵔⴰⵏ
FACULTÉ DE MÉDECINE ET DE PHARMACIE

Thesis N° 023/20

**INTERVENTIONAL CATHETERIZATION TREATMENT IN VIEW
OF A PERCUTANEOUS CLOSING OF THE INTRACARDIAC SHUNTS
AND A DILATION OF THE COARCTATIONS OF THE AORTA WITH STENT OR NOT
(About 127 cases)**

THESIS

SUPPORTED AND PRESENTED PUBLICLY ON 13/01/2020

By

Mr. AMR NOORALDIN

Born the 10 September 1992 in Hebron – PALESTINE

TO OBTAIN MEDICAL DOCTORATE DEGREE

KEYWORDS:

Patent ductus arteriosus – Atrial septal defect – Ventricular septal defect
Coarctation of the aorta – Diagnosis – Transcatheter occlusion – Amplatzer duct occluder
Amplatzer Septal Occluder – Balloon angioplasty – Stent

JURY

M. HIDA MOUSTAPHA..... Professor of Pediatrics	PRESIDENT
Mr. ATMANI SAMIR..... Professor of Pediatrics	PROTRACTOR
Mr. HARANDOU MUSTAPHA..... Professor of Anaesthesia and Intensive Care	} JUDGES
Mr. EL KOUACHE MUSTAPHA..... Professor of Anatomy	
Mr. BERDAI MOHAMED ADNANE..... Aggregate professor of Anaesthesia and Intensive Care	

PLAN

INTRODUCTION	13
PERSONNEL REQUIREMENTS	16
Transcatheter Closure of Patent Ductus Arteriosus	18
A- INTRODUCTION	19
B- Indications for Percutaneous Closure.....	20
C- DEVICES FOR PATENT DUCTUS ARTERIOSUS	20
I. Gianturco coils.....	21
II. Detachables coils	22
III. Gianturco–Grifka vascular occlusion device (GGVOD)	23
IV. Amplatzer ductal occluder (ADO).....	23
D- PRECATHETERIZATION CARE.....	24
E- METHODS OF DEVICE IMPLANTATION	25
I. Angiographical classification	25
II. Gianturco coils	27
III. Amplatzer ductal occlude (ADO)	31
F- POST CATHETERIZATION CARE	36
G- COMPLICATIONS.....	37
I. Embolization to the Branch Pulmonary Arteries.....	37
II. Embolization to the descending thoracic aorta	39
III. Loss of grip on the coil mass	40
IV. Inability to release the coil after biopptome jaws are opened	40
V. Hemolysis from residual flows	40
VI. Infective endocarditis	40
Transcatheter closure of atrial septal defect	41
A-Introduction	42
B- Principles and issues of device closure of ASD	43
C-Indications for ASD closure.....	53
D- Techniques of percutaneous ASD closure.....	54

E– devices for ASD closure	55
I. ASO.....	55
II. Occlutech Figulla Flex II ASD Occluder.....	55
III. GSO.....	56
IV. CeraFlex ASD Occluder.....	57
V. Cocoon Septal Occluder	57
VI. Nit–Occlud ASD–R.....	58
VII. Cardi–O–Fix Septal Occlude	58
VIII. Ultracept II ASD Occluder	59
IX. Carag Bioresorbable Septal occlude	60
F– complications.....	61
I. Groin hematoma & femoral arteriovenous fistula.....	61
II. Device embolisation	61
III. Erosion/perforation of the atrial wall with pericardial effusion or tamponade	62
IV. Aortic incompetence	62
V. Coronary compression	63
VI. New–onset migraine	63
VII. Arrhythmias	63
VIII. Thrombosis & recurrent thromboembolic events	64
IX. Left ventricular dysfunction	65
Transcatheter closure of ventricular septal defect.....	66
A– INTRODUCTION.....	67
B– Indications for ventricular septal defect closure.....	68
C– Devices for ventricular septal defect	69
I. Rashkind device	70
II. Amplatzer devices	72
III. Button device	73

IV. Bard Clamshell umbrella	73
V. Gianturco coils	73
D–device implantation technique	74
E– Percutaneous closure of Muscular VSD’s.....	74
F–Percutaneous Closure of Perimembranous/membranous VSD	81
G–Complications	86
I. Device embolization.....	86
II. Arrhythmias	87
III. Air embolism	87
IV. Hemolysis	87
V. Valvular regurgitation	87
VI. Pericardial effusion	88
Coarctation of the aorta	89
A–Introduction	90
B–INDICATIONS FOR TREATMENT.....	90
C–Treatment of Coarctation.....	92
D–Percutaneous Options and Mechanism of Action	92
E–Equipment	93
I. Balloons for Angioplasty.....	96
II. Balloons for Stent Delivery.....	96
III. Stents	97
IV. Guidewires	100
VI. Sheaths	100
F–Catheterization Procedure.....	102
G–Technique of Balloon Angioplasty	106
H–Technique of Stenting	108
I–Complications.....	112
I. Technical complications	113

II. Aortic wall complications.....	114
III. Peripheral vascular complications.....	115
IV. Post-procedural rebound hypertension.....	115
V.Thoracic pain and abdominal discomfort	115
Patients and methods	117
I. Patients and Inclusion / Exclusion criteria	118
II. The parameters studied	118
1. Study of epidemiological data	118
a. Age	118
b. Sex	118
c. Weight.....	118
d. Personal history	119
2. Diagnosis	119
2.1.Clinic	119
a. functional signs	119
b. physical examination	119
2.2.Radiography.....	119
a. chest X-rays	119
b. transthoracic Echo/Doppler data	119
3. Treatment, Evolution and Post-operative care.	119
III. Difficulty of the study	119
RESULTAT	120
PATENT DUCTUS ARTERIOSUS.....	121
1. Study of epidemiological data.....	121
a. Age distribution.....	121
b. Gender distribution.....	121
c. Distribution by weight.....	121
d. Genetic syndromes	121

e. Intracardiac disease and PDA	122
f. Etiological factors	122
2. Diagnosis	123
2.1. clinic	123
2.1.1. functional signs	124
2.1.2. physical examination	124
a. Pulse Examination	124
b. Blood pressure	124
c. Cardiac auscultation	125
d. Signs of heart failure	126
e. The arterial oxygen saturation	126
2.2. Radiography	126
2.2.1 chest X-rays data	126
a. cardiothoracic ratio (CTR)	126
b. The pulmonary vasculature	126
c. Left mid-cardiac border	126
2.2.2. Transthoracic Echo/Doppler Data	126
a. Study of the ductus arteriosus	126
a.1. The channel diameter	126
a.2. maximum Doppler velocity	127
a.3. shunt direction	127
b. Left heart chambers	128
c. Right heart chambers	128
d. Pulmonary arterial hypertension	128
e. Associated lesions	128
3. Treatment, Evolution and Post-operative care	128
atrial septal defect	130
1. Study of epidemiological data	130

a. Age distribution.....	130
b. Gender distribution	130
c. Distribution by weight.....	130
d. Genetic syndromes	130
e. Intracardiac disease and PDA	131
f. Etiological factors.....	131
2. Diagnosis	132
2.1. clinic	132
2.1.1. functional signs	132
2.1.2. physical examination	133
a. Pulse Examination	133
b. Blood pressure	133
c. Cardiac auscultation	133
d. Signs of heart failure	134
e. The arterial oxygen saturation	134
2.2. Radiography	134
2.2.1 chest X-rays data.....	134
a. cardiothoracic ratio (CTR)	134
b. The pulmonary vasculature.....	135
c. Left mid-cardiac border	135
2.2.2. Transthoracic Echo/Doppler Data.....	135
a. Study of the atrial septal defect.....	135
a.1. The channel diameter.....	135
a.2. maximum Doppler velocity.....	135
a.3. shunt direction.....	135
b. Left heart chambers.....	135
c. Right heart chambers.....	135
d. Pulmonary arterial hypertension	136

e. Associated lesions	136
3. Treatment, Evolution and Post-operative care.....	136
ventricular septal defect	137
1.Study of epidemiological data	137
a. Age distribution	137
b. Gender distribution	137
c. Distribution by weight.....	137
d. Genetic syndromes	137
e. Intracardiac disease and PDA	138
f. Etiological factors.....	138
2. Diagnosis	139
2.1. clinic	139
2.1.1. functional signs	139
2.1.2. physical examination	140
a. Pulse Examination	140
b. Blood pressure	140
c. Cardiac auscultation	140
d. Signs of heart failure	140
e. The arterial oxygen saturation	140
2.2. Radiography.....	140
2.2.1 chest X-rays data.....	140
a. cardiothoracic ratio (CTR)	140
b. The pulmonary vasculature.....	140
c. Left mid-cardiac border	140
2.2.2. Transthoracic Echo/Doppler Data	141
a. Study of the ventricular septal defect	141
a.1. The channel diameter.....	141
a.2. the number of the VSD	142

a.3. maximum Doppler velocity.....	142
a.4. shunt direction.....	142
b. Left heart chambers.....	142
c. Right heart chambers.....	142
d. Pulmonary arterial hypertension	142
e. Associated lesions	142
3. Treatment, Evolution and Post-operative care.....	143
Coarctation of the aorta	144
1. Study of epidemiological data.....	145
a. Age distribution.....	145
b. Gender distribution	145
c. Distribution by weight.....	145
d. Genetic syndromes	145
e. Intracardiac disease and PDA	146
f. Etiological factors.....	146
2. Diagnosis.....	147
2.1. clinic	147
2.1.1. functional signs	147
2.1.2.physical examination	148
a. Pulse Examination	148
b. Blood pressure	148
c. Cardiac auscultation	148
d. Signs of heart failure	148
e. The arterial oxygen saturation	148
2.2. Radiography.....	149
2.2.1 chest X-rays data.....	149
a. cardiothoracic ratio (CTR)	149
b. The pulmonary vasculature.....	149

c. Left mid–cardiac border	149
2.2.2. Transthoracic Echo/Doppler Data	149
3. Treatment, Evolution and Post–operative care.....	151
Global epidemiological profile of our study.....	152
Global functional sign of our study	152
Radiography of our study	152
Transthoracic Echo of our study.....	152
Treatment results of our study.....	152
DISCUSSION.....	153
PATENT DUCTUS ARTERIOSUS	154
Main characteristics according to others authors	154
Atrial septal defect.....	162
Main characteristics according to others authors	162
Ventricular septal defect	164
Main characteristics according to others authors	164
Coarctation of the aorta.....	167
Main characteristics according to others authors	168
Conclusion	173
Abstract	179
BIBLIOGRAPHY.....	185

ABBREVIATIONS

PDA	: Patent Ductus Arteriosus
ADO	: Amplatzer Duct Occluder .
ASD	: Atrial septal defect
ASO	: Amplatzer Septal Occluder
AV	: atrioventricular
BIB	: Balloon-in-Balloon
CBRO	: Carag Bioresorbable Septal Occluder
Chd	: congenital heart disease
CHF	: congestive heart failure
COA	: Coarctation of the aorta .
CTR	: Cardiothoracic ratio .
DAO	: Descending aorta
GGVOD	: Gianturco-Grifka vascular occlusion device .
GSO	: Gore Septal Occluder
HSO	: Helex Septal Occluder
ICE	: intracardiac echocardiography
IVC	: inferior vena cava
KT	: Cathétérisme .
LA	: left atrial
LPA	: Left pulmonary artery .
LV	: Left ventricular .
LV	: left ventricle
MPA	: Main pulmonary artery .
PAH	: Pulmonary arterial hypertension .

PDA	: Patent ductus arteriosus .
PVOD	: pulmonary vascular obstructive disease
PVR	: Pulmonary vascular resistance .
PVR	: pulmonary vascular resistance
QP	: Pulmonary flow .
QS	: Systemic flow .
RA	: right atrium
RV	: Right ventricular .
RV	: right ventricle
SFD	: stop flow diameter
SGA	: Small for gestational age .
SVC	: Superior vena cava
TEE	: transesophageal echocardiography
TTE	: Transthoracic echocardiography
VSD	: ventricular septal defect

INTRODUCTION

During the last few years, dramatic changes have taken place in the pediatric cardiac catheterization laboratory.

Improved non invasive diagnostic techniques have narrowed the indications for diagnostic cardiac catheterization, and the laboratory is now increasingly being used for therapeutic procedures. Concern about the appropriateness of some applications of pediatric therapeutic cardiac catheterization has arisen recently because of numerous catheter techniques, the increased numbers of persons and centers using these techniques, and the increased number of lesion types thought to be amenable to catheter therapy.

In comparison with diagnostic cardiac catheterization, therapeutic catheter procedures require more time and resources, are costlier and riskier, and demand more technical training and expertise. High levels of skill are required of the operator who performs the various therapeutic catheterization techniques. These procedures should only be performed in institutions with appropriate facilities, personnel, and programs [1]. These considerations, combined with the rapid increase in the number of laboratories and cardiologists performing therapeutic catheterization procedures, cause concern about hospital and physician credentialing, hospital and physician peer review, and human subjects investigational review. Since publication of the last American Heart Association statement[2] on pediatric therapeutic cardiac catheterization many new devices and applications have been described.

OBJECTIVE

- Report a new technique that is currently developing in unit Pediatric Medical and Surgical Unit – University Hospital Hassan II –Fez.
- Prove the safety of this intervention that should be a priority rather than a choice.
- Identify the challenges and limitations of this technique.

PERSONNEL

REQUIREMENTS

Therapeutic catheterization training programs vary in type, extent, and quality. Because of the complexity and potential risks of these procedures, specific credentialing criteria should be developed for those who wish to begin performing therapeutic catheterization as well as for those who continue to perform various procedures.

Performance of therapeutic catheterization in children requires specific training. Pediatric cardiology fellows should receive therapeutic catheterization training in one or more centers that carry out angioplasty, valvuloplasty, and/or vascular occlusion procedures. Before performing a therapeutic catheterization as the primary operator, the fellow or practicing pediatric cardiologist should be required to receive procedure-specific training under the supervision of a qualified individual similar to that required of internist cardiologists who wish to perform coronary angioplasties [3]. Credentialing should be procedure specific. To maintain his or her credentials, the cardiologist should perform or supervise an adequate number of cases annually to maintain skills, and the results must compare favorably with national experience. The pediatric cardiologist must be aware of new trends and information through reading and attendance of meetings. However, attending “how- to” seminars and observing experts does not obviate the need for personal experience. An ACC/AHA task force report states that “it is essential that physicians performing angioplasty and related procedures are adequately trained, that facilities and equipment used are capable of obtaining the necessary radiographic information, and that the safety record of the laboratory is acceptable.” [4]

The facility, hospital, quality assurance programs, and laboratory personnel associated with the pediatric therapeutic catheterization program must meet applicable international standards.[1]

Transcatheter Closure of Patent Ductus Arteriosus

A. Introduction

Ductus arteriosus develops from the distal portion of the left sixth aortic arch and connects the main pulmonary artery with descending aorta. After birth, the ductus closes by contraction of the medial smooth muscle leading to constriction, shortening and functional closure, followed by permanent sealing of the lumen to form ligamentum arteriosus. Failure of constriction of ductus leads to patency of ductus. The incidence of isolated patent ductus arteriosus (PDA) in terms of infants is 1 in 2,000 live births [1]. The PDA constitutes 6 to 11% of all congenital heart defects. In preterm infants, the incidence is higher, at about 8 per 1,000. The shape of the PDA varies, but most often the aortic end is wide and narrows towards the pulmonary end. Earlier descriptions such as conical, tubular, short, and long, have largely been replaced by a classification described by Krichencko et al. [2] Type A. Ductus with narrowest segment is at the pulmonary end, Type B. Ductus is short and narrow segment is at the aortic end, Type C.

Tubular ductus without narrowing, Type D. Ductus with multiple constrictions and Type E. Bizarre configuration with elongated, conical ductus with narrowing is remote from the anterior border of trachea. Types A and B are further divided in to three subgroups based on the relation of the pulmonary end to the trachea. In this paper we will review the methods of PDA closure, indications for closure, devices available for percutaneous closure, selection of devices for closure and methods of device implantation along with results and future directions.

B. Indications for Percutaneous Closure

The procedure is indicated only in patients with continuous murmur suggestive of PDA with Echo-Doppler confirmation. We do not recommend [10] closure of the so-called “silent ductus” detected incidentally without typical auscultatory features. Very small and small PDAs are candidates for closure even though they are not hemodynamically significant, mostly to eliminate the risk of subacute bacterial endocarditis. Medium- and large-sized ducts should be closed to prevent further volume overloading of the left ventricle, to treat congestive heart failure and to prevent pulmonary vascular obstructive disease along with eliminating the risk of endocarditis. Closure is contraindicated in patients with ductal-dependent congenital cardiac anomalies and those associated with pulmonary vascular obstructive

C. Devices for patent ductus arteriosus

A number of devices were used in human subjects and underwent clinical trials, but only a few devices are approved by FDA in the US for transcatheter closure of PDA; these include, Gianturco coil, Gianturco- GriTha vascular occlusion device and Amplatzer duct occluder.

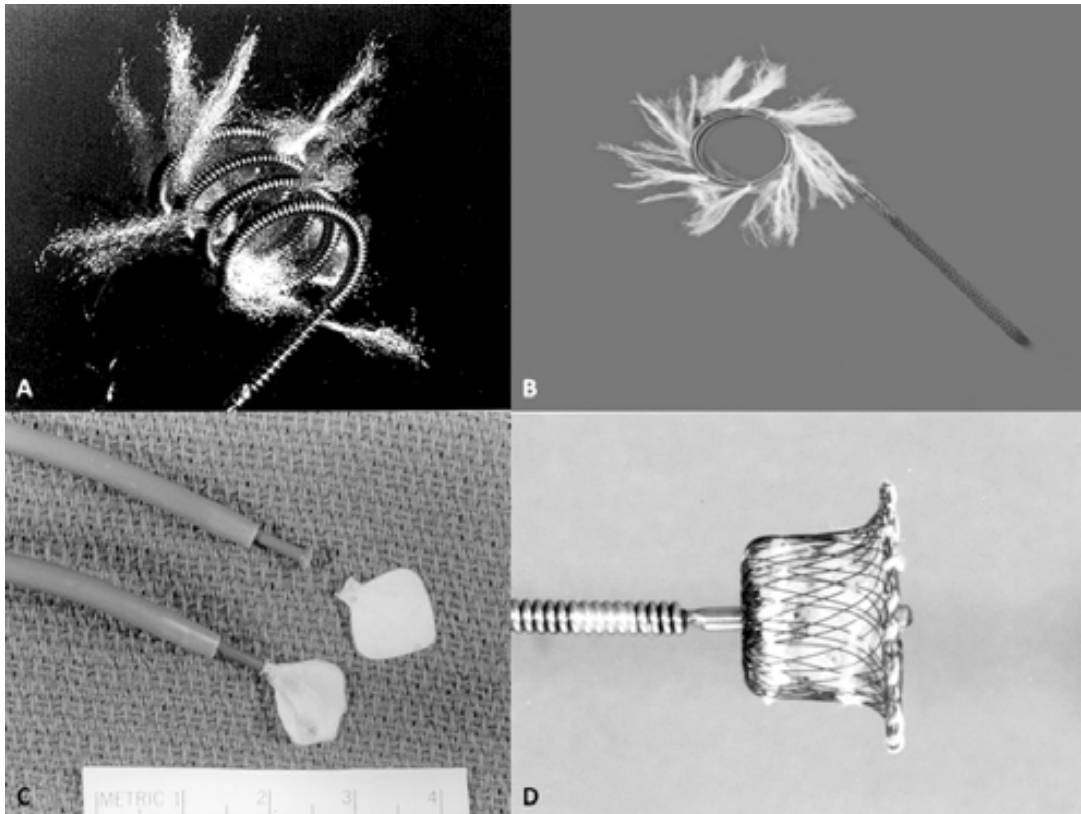


Figure.1: Photographs of transcatheter delivered patent ductus arteriosus occlusion devices: A. Gianturco coil, B. Cook detachable coil, C: Gianturco– Grifka vascular occlusion device and D. Amplatzer Duct Occluder.

I. Gianturco coils

These are comprised of stainless–steel wire with thrombogenic dacron fibers incorporated into them. These coils were originally described in 1975 [6] and were used to occlude renal arteries and have undergone a number of changes over the years. They are commercially available at the present time for clinical use in a variety of wire diameters, loop diameters and lengths. They were initially used on an off–label basis; subsequently received FDA approval.

Since the initial description by Cambier et al. [7] of occlusion of PDA, a number of refinements and modifications of the procedure or of the coil have occurred; these include ante grade and multiple coil techniques, [8] snare–assisted

coil delivery, [9]bioptome–assisted coil delivery, [10]temporary balloon occlusion of the ductus on the aortic [11]or pulmonary artery [12] end, five loop coil design, [13,14] coil delivery via catheters with tapered tip, [15,16] increasing the wire diameter to 0.052", [17,18] coil implantation without the use of heparin [19] and detachable design [20,21].

Some of these techniques may have advantage over the conventional retrograde free coil delivery, while others may marginally improve upon the technique. Many of these changes increase the complexity of the procedure, prolong the fluoroscopy and procedure time and add to the cost. These considerations should be taken into account when embarking on the use of modified techniques. Our own view is that conventional retrograde delivery of free 0.038" Gianturco coils for very small PDAs is adequate [22](Figure1A).

II. Detachable coils

Gianturco coils have been successfully used in the occlusion of PDA; however, lack of controlled delivery and inability to retrieve and reposition the coil are thought to be potential problems. Consequently, detachable coils have been developed. Two different designs have been undertaken: the first type (Cook detachable coil) has a mechanism in which the notch of the stretched coil winding interlocks with the bead at the end of the core wire in the delivery catheter [20]. Once the coil is positioned appropriately, the coil can be released by the handle at the proximal (outside the patient) end of the delivery catheter. The second design is also a Gianturco coil, but with an added short threaded extension at its proximal end. This is attached to the distal end of the delivery wire, which provides controlled delivery and retrieval when required.

Following implantation at the desired location, the delivery wire is unscrewed from the coil, thus releasing the coil [21]. This is named “Flipper” detachable coil (Figure 1B).

III. Gianturco–Grifka vascular occlusion device (GGVOD)

The GGVOD, consists of a nylon sac and a long occluding wire [23,24] and is presumed to be a modification of Megal’s conical Nylon sack filled with segments of modified guide wire (which was experimented in the late 1980s [25]). The GGVOD is manufactured in several sizes (3, 5, 7, and 9 mm)

and can be implanted via 8 French sheaths. It is approved by the FDA for general clinical use. In the limited published studies [23,24] residual shunts were present in 9% patients immediately after device deployment but, all of them closed spontaneously during follow-up. Because of requirement of a large delivery sheath for device delivery and difficulty in retrieval of dislodged devices, it is not commonly used in clinical practice (Figure 1C).

IV. Amplatzer ductal occluder (ADO)

The ADO is made up of 0.004” Nitinol wire mesh designed as a mushroom – shaped implant and is self-expandable [26,27]. The device length is 7 mm except for the 5/4 device (which is 6 mm long). The aortic end is 2 mm larger than the pulmonary end, gradually tapers from the aortic to pulmonary end. A thin retention disc is placed at the aortic end and is 4 mm larger than the aortic end of the device.

A recessed screw is assembled into the pulmonary end and is connected to the delivery wire during deployment. Polyester fibers are sewn into the device to encourage thrombosis after implantation. The devices can be implanted via 6 to 8 French sheaths. Multiple sizes are manufactured.

At the present time, ADO is the most commonly used device worldwide in the closure of moderate-to-large PDAs (Figure 1D).

D. PRECATHETERIZATION CARE

The clinical examination demonstrates the PDA continuous murmur in the expected location. The electrocardiogram is often normal. Active infection is ruled out. Transthoracic echocardiography aims to identify any potential associated lesions, to assess left ventricular volume diameters and function, to assess PDA size and, finally, to assess pulmonary arterial pressure. The echocardiogram is very useful in determining if PDA closure is, in fact, indicated. Although it was previously believed that all PDAs identified should be closed, with more relaxed recommendations regarding sub acute bacterial endocarditis prophylaxis in the setting of the ductus, small haemodynamically-insignificant PDAs with no evidence for left atrial or left ventricular enlargement are often not closed.

E. Methods of Device Implantation

The methods of implantation of the two most commonly used devices, namely free Gianturco coils and Amplatzer duct occluder will be described.

I. Angiographical classification

Following a brief assessment of the haemodynamics, PDA closure always begins with an aortogram to precisely assess the aortic arch and PDA characteristics, as the ductus arteriosus may persist in a wide variety of sizes and configurations (Fig. 2). Krichenko et al. described a useful angiographical classification for guidance of transcatheter PDA closure [28].

Ductal anatomy in the lateral projection is classified into five categories:

- Type A: is a conical ductus, with a well-defined aortic ampulla and constriction at its pulmonary end .
- Type B: is a large and very short ductus, mimicking an aortopulmonary window-like structure .
- Type C: is a tubular duct, of varying length, without any constriction at its pulmonary end .
- Type D: is more complex, with multiple constrictions on the ductus;
- Type E: is an elongated ductus, frequently seen in ex-premature babies.

This initial angiography is performed with a 4 F or 5 F pigtail catheter positioned in the proximal descending aorta in the straight lateral view. Other projections may be helpful, such as 30° right anterior oblique projections in the left-sided aortic arch, 30° left anterior oblique projections in the right-sided aortic arch and, eventually, a combined left anterior oblique 30°, cranial 30° to open up the pulmonary artery bifurcation and show the proximal left pulmonary artery (for dextrocardia, it is the right anterior oblique equivalent).

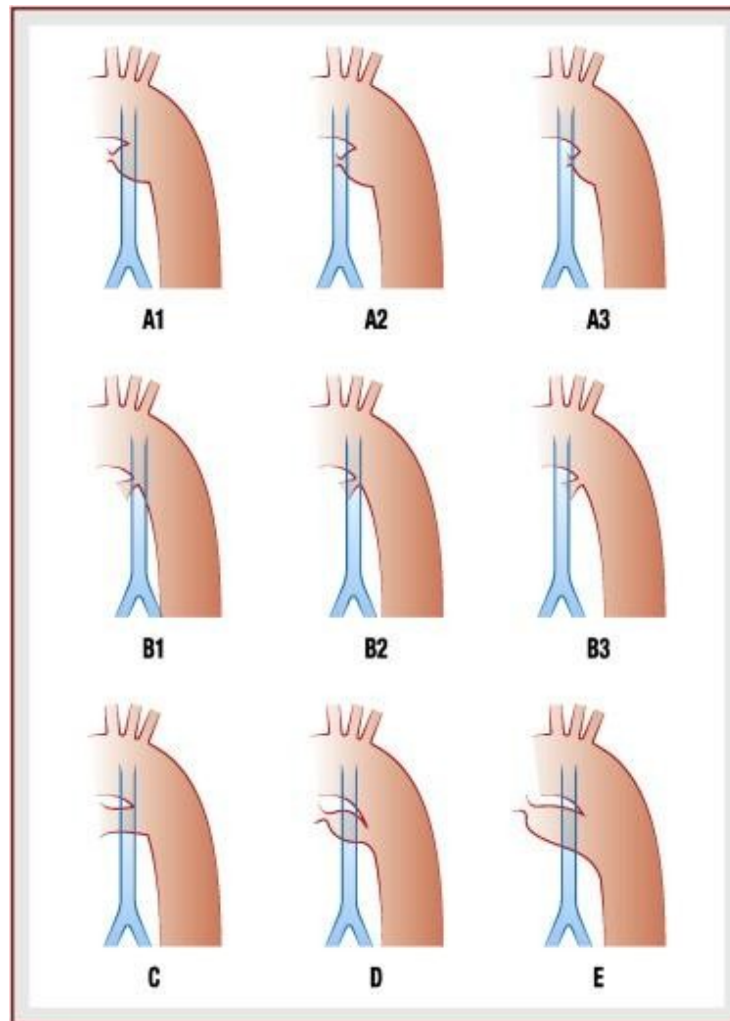


Figure. 2 Angiographical classification from Krichenko et al. [28]. Ductal anatomy in the lateral projection is classified into five categories.

II. Gianturco coils

Implantation of free coils was initially described by Cambier et al. [7] and the method that we use [5,13, 14, 22] is similar to that detailed by Cambier. Cardiac catheterization is performed percutaneously via the femoral vein and artery to confirm the clinical and echocardiographic diagnosis. Heparin (50 to 75 units/kg) is administered intravenously following insertion of the arterial sheath. Aortic arch angiography in 30° right anterior oblique (RAO) and straight lateral views is performed by injecting 1 ml/kg of contrast material via a 4- or 5-French marker pigtail catheter introduced through the femoral arterial sheath (Figure 3).

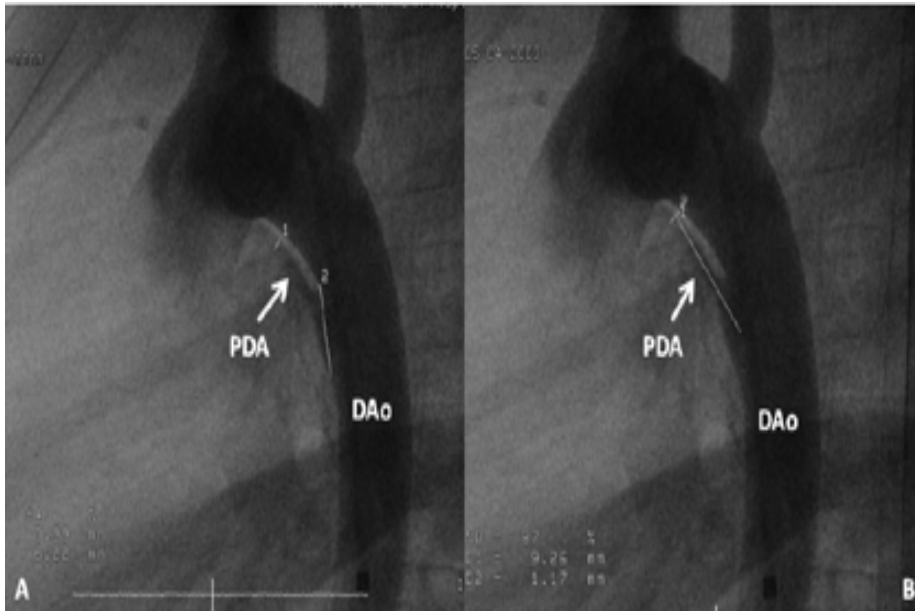


Figure.3: Selected cine frames from aortic arch angiogram in lateral views demonstrating measurements in a patient with small patent ductus arteriosus (PDA). Measurements of minimal ductal diameter and ductal ampulla in A and minimal ductal diameter and length of the ductus in B are shown. Catheter with markers is partly seen both A & B. DAo, descending aorta.

Measurement of narrowest ductal diameter (usually at the pulmonary end), size of ampulla (at the aortic end) and length of ductus are measured (Figure 4) in both views and averaged.

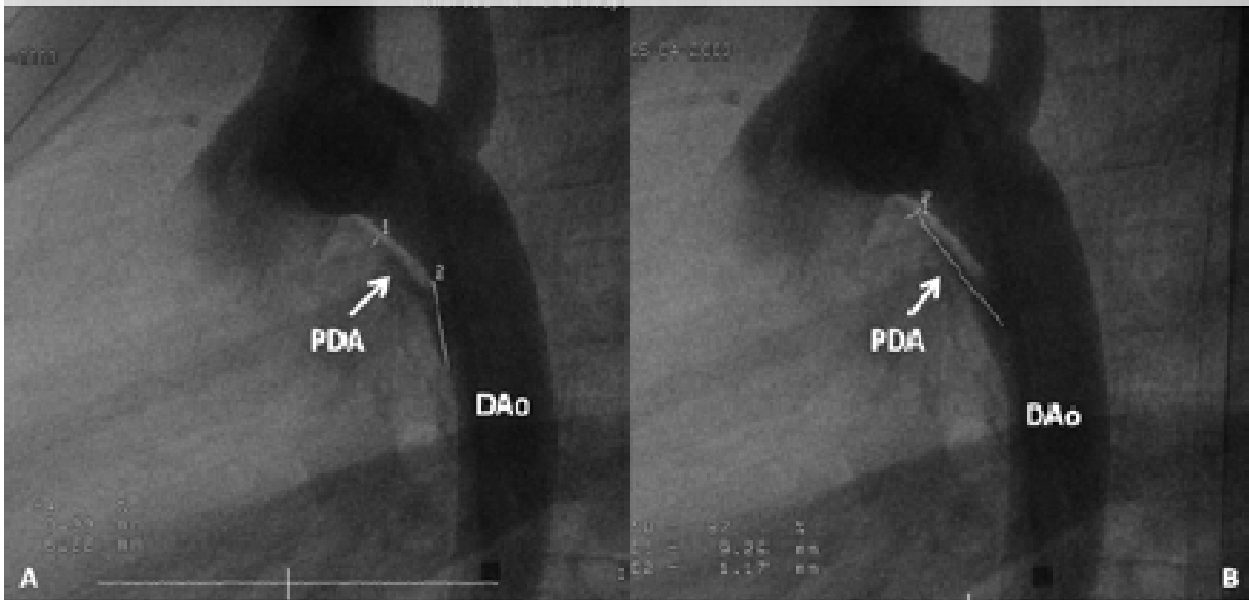


Figure.4: Selected cine frames from aortic arch angiogram in lateral views demonstrating measurements in a patient with small patent ductus arteriosus (PDA). Measurements of minimal ductal diameter and ductal ampulla in A and minimal ductal diameter and length of the ductus in B are shown. Catheter with markers is partly seen both A & B. DAo, descending aorta.

Sometimes foreshortening may give spurious values, which may be ignored. These measurements serve as a guide for selection of the diameter of the coil used for occlusion. We almost exclusively use 0.038" Gianturco coils because of better occlusion when compared 0.035" coils.

A 4-French right coronary artery catheter (Cordis, Miami, FL) or a 4-French Glidecath catheter (Meditech, Watertown, MA) is introduced from the descending aorta into the main pulmonary artery via the PDA.

If the catheter cannot be advanced easily into the ductus, the soft end of a 0.035" straight Benston (Cordis, Miami, FL), straight Teflon-coated Amplatz (Cook,

Bloomington, IL), or angled floppy (Meditech, Watertown, MA) guide wire is used to cross the ductus.

Our first preference is straight Benston guide wire. The catheter is advanced across the ductus over the guide wire. Position of the tip of the catheter in the main pulmonary artery is ensured by pressure measurements and if necessary, test injection of contrast material.

Aortic arch angiographic frames, obtained in the RAO and straight lateral views (Figure 3), are used as a reference/guide throughout the procedure. The relationship of the minimal ductal diameter with the anterior tracheal shadow is noted and should be used to position the coil in the ductal structure.

A coil with a loop 2 to 3 times the narrowest ductal diameter is selected for implantation. The coil is loaded into the catheter with the stiff end of a 0.038-in Teflon-coated guide wire but is advanced with its floppy end. Under fluoroscopic guidance (lateral view) one to one and one-half loops of the coil are delivered into the main pulmonary artery.

The delivery guide wire is partially withdrawn and the entire system (the coil and catheter) is pulled back so that the delivered coil loops are drawn into the pulmonary end of the ductus. Then, the delivery catheter is pulled back gently into the aortic end of the ductal ampulla.

The delivery guide wire is re-advanced until it touches the coil in the catheter. The guide wire is fixed in position and the catheter is slowly withdrawn over the wire into the descending aorta, thus extruding the remaining coil into the aortic end of the ductal ampulla. Thus, the delivered coil straddles the narrowest diameter of the ductus.

Fifteen minutes after coil delivery, repeat aortic arch angiography (Figure 5),

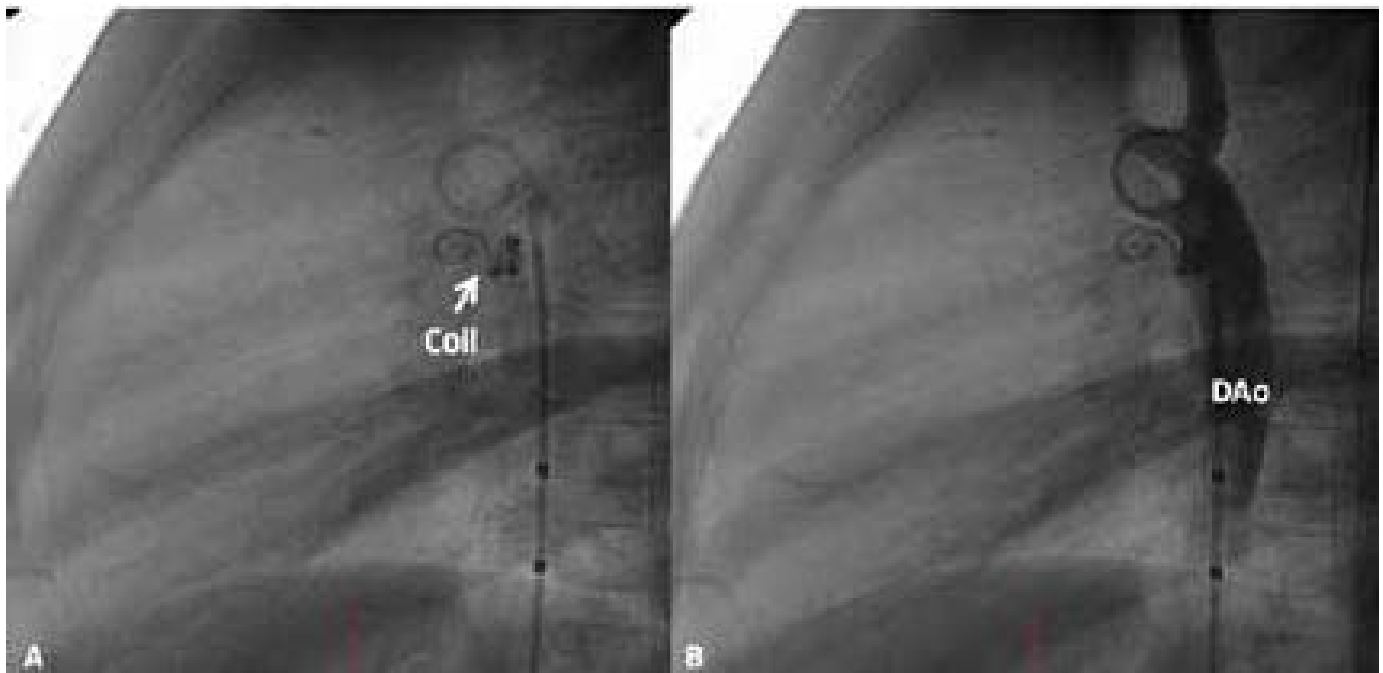


Figure.5: Selected cine frames from aortic arch angiogram in lateral view demonstrating the position of the coil (arrow) in the patent ductus arteriosus (A) and complete occlusion of the ductus (B). Catheter with markers is seen in both A & B.

DAo, descending aorta.

Careful pressure pullback from the aortic arch to descending aorta, and measurement of oxygen saturations from the right ventricle, main pulmonary artery and ascending aorta are performed.

One dose of Ancef (25 mg/kg/dose) is administered intravenously in the catheterization laboratory and two additional doses are given 6 and 12 hours after the first dose. The heparin is not continued nor its effect reversed. Clinical evaluation, chest roentgenogram and echo-Doppler studies are obtained on the day following the procedure and at 1, 6, 12, 36 and 60 months after coil implantation.

III. Amplatzer ductal occlude (ADO)

Musura and his associates [27] were the first to report use of the Amplatzer duct occluder in human subjects and the method that we use is similar to that described by Musura. The procedure is similar to that described in the coil implantation section above up to the measurement of ductal size (Figure 6).

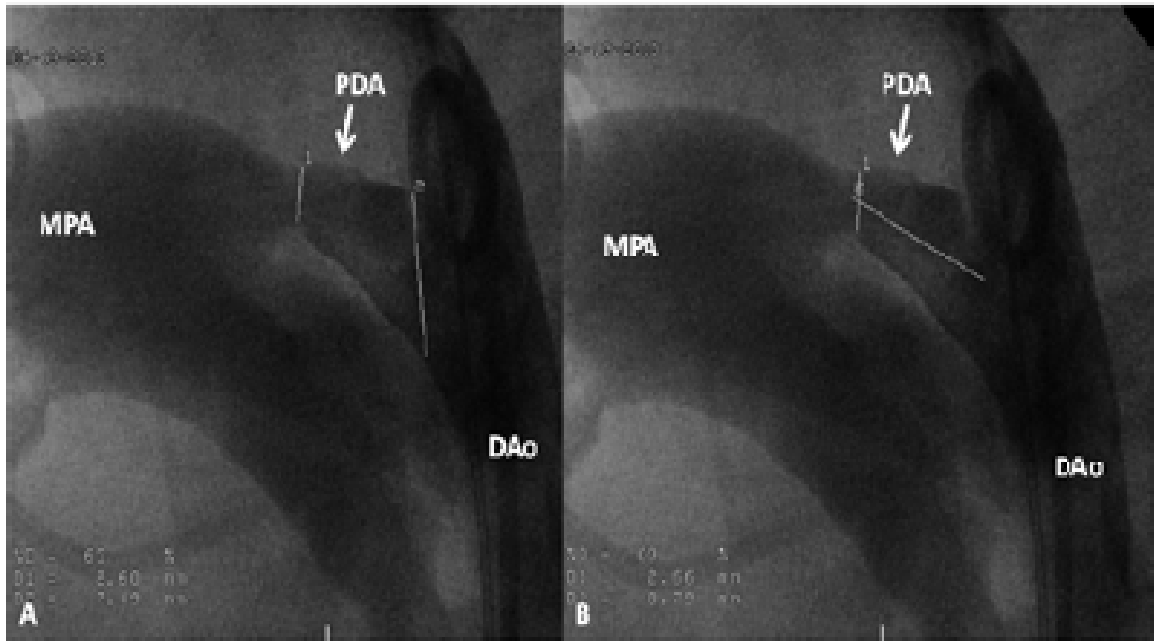


Figure.6: Selected cine frames from aortic arch angiogram in lateral views demonstrating measurements in a patient with moderate to large patent ductus arteriosus (PDA). Measurements of minimal ductal diameter and ductal ampulla in A and minimal ductal diameter and length of the ductus in B are shown. DAo, descending aorta; MPA, main pulmonary artery.

A 4 or 5-French multipurpose catheter is introduced into femoral vein, positioned in the main pulmonary artery and advanced into the descending aorta via the ductus. If the catheter cannot be advanced across the ductus by itself, we use 0.035" straight

Benston guide wire, with a long floppy tip to cross the ductus. A 0.035" extra-stiff exchange-length J-tipped Amplatzer guide wire is positioned in the descending aorta and the multipurpose catheter removed. In rare occasions when antegrade entry into the PDA is not feasible, a guide wire (exchange length) is advanced into the pulmonary artery via a catheter and introduced into the ductus from the descending aorta.

The guide wire is further manipulated into the right ventricle, right atrium and superior vena cava. The wire is snared from the superior vena cava (or pulmonary artery) and exteriorized via the femoral venous sheath.

Then, an appropriate-sized Amplatzer PDA device delivery sheath is advanced over the wire, across the right heart and ductus and its tip positioned in the descending aorta.

An ADO device whose pulmonary end is 1 to 2 mm larger than the size of the narrowest diameter of the PDA is selected for implantation.

The selected Amplatzer duct occluder is deaerated and screwed onto the delivery cable. After completely screwing the device, the device is unscrewed by one to one and one-half turns to facilitate unscrewing and release after it is positioned in the ductus. The device is withdrawn under saline into the loader sheath and the device is deposited into the delivery sheath already in place while flushing the device loader to avoid air entry into the system.

The device is advanced within the sheath under fluoroscopic guidance. When the tip of the device arrives at the tip of the sheath, the entire system is withdrawn until the tip of the sheath is in the descending aorta just distal to the aortic ampulla of the ductus.

Then, holding the device in place, the sheath is retracted so as to uncover and deploy the aortic disc of the device. The entire system is slowly pulled back into the ductal ampulla and if possible into the mid-ductus. An aortogram is performed to evaluate the position of the aortic disc of the device (Figure 7A).

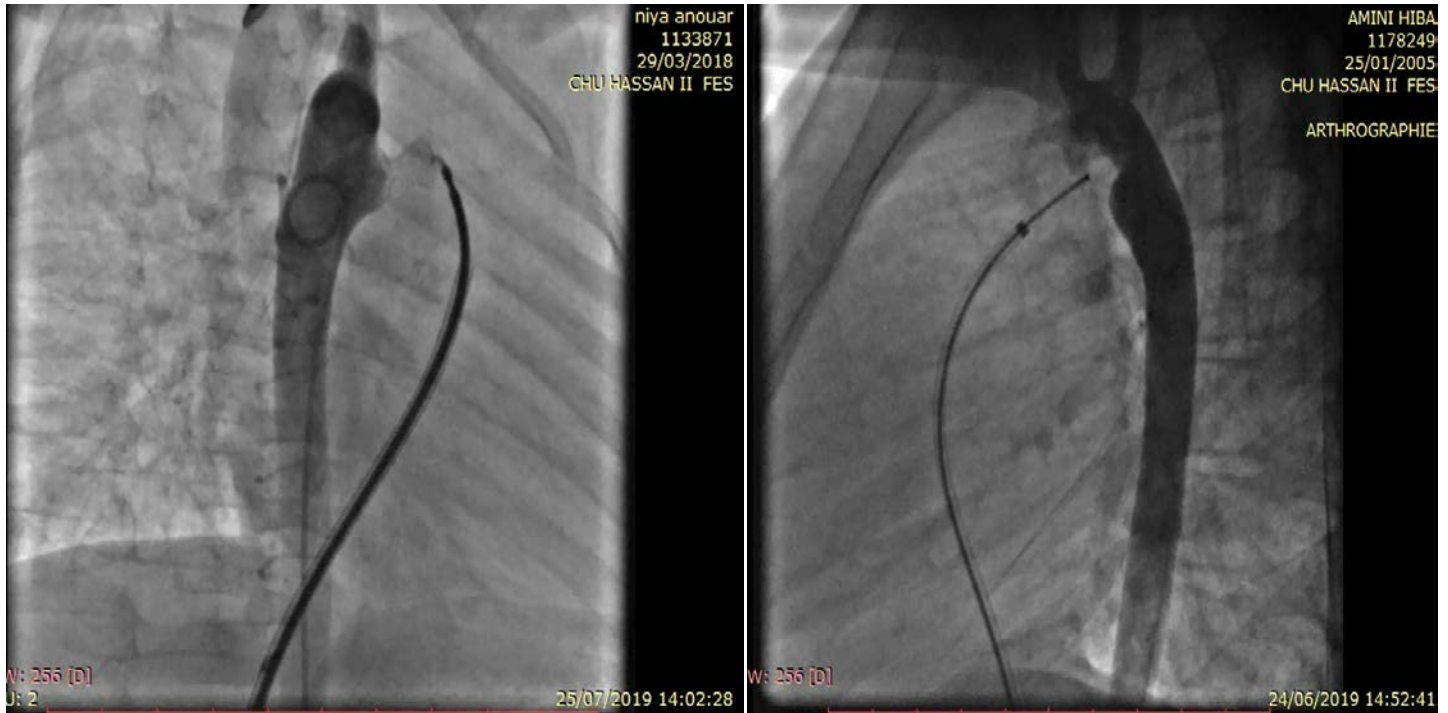


Figure.7: Selected cine frame from aortic arch angiogram in lateral view demonstrating the position of the aortic disc of the Amplatzer duct occlude (ADO) in the patent ductus arteriosus (A). Similar cine frame after opening the pulmonary end of the ADO (B). Both illustrate good position of the device components.

If satisfactory, the sheath is further withdrawn, while holding the device in place, to uncover the remaining part of the device, across the narrow pulmonary end of the ductus.

An aortogram (Figure 7B) is repeated to verify the position of the aortic disk within the ductus without protruding into the descending aorta and the position of the pulmonary end of the device across the narrowest part of the ductus and that

there is no residual shunt around (and parallel to) the device. Having been assured of good position of the device, the delivery cable is rotated counterclockwise until the device is released thus implanting the device. The delivery cable and sheath are withdrawn into the inferior vena cava and the delivery cable is then taken out of the patient and the delivery sheath flushed.

The long sheath is exchanged with a short sheath. Ten minutes following device implantation, aortic arch cineangiography is performed in 30° RAO and straight lateral (Figure 8) projections.

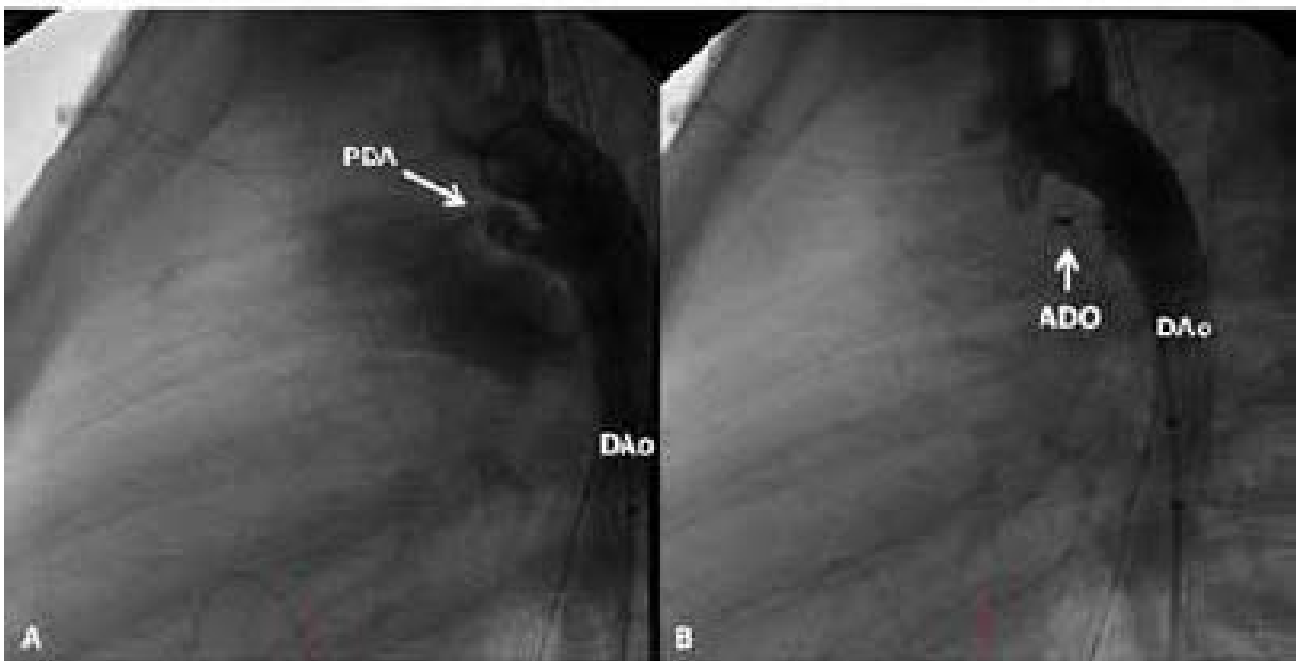


Figure.8: Selected cine frames from aortic arch angiogram in lateral view demonstrating patent ductus arteriosus (PDA) in A. Following implantation and release of the Amplatzer duct occluder (ADO) (arrow), the device position looks good the small residual shunt thru' the device (Figure 7B) is no longer seen (B). Catheter with markers is seen in both A & B. DAo, descending aorta.

Measurement of the pressures on pullback across the descending aorta and right ventricular, pulmonary arterial and aortic oxygen saturations are obtained.

Antibiotic administration and follow-up are similar to those described for the coil occlusion section.

Advantages of Using the ADO for Closing a Large PDA in Infants

The ADO, developed to close moderate-to-large-sized PDA, has a high success rate and low complication rate.[29] [33] They previously proposed a strategic approach to the closure of the ductus: use coils for small-size PDA and the ADO for moderate-to-large ones. There are many reports regarding closure of the ductus using the ADO, but the majority of patients included were over 1 year of age, and reports of ductal closure using the ADO in infants are few and the case numbers rather limited.[30] [31]PDA may be an isolated anomaly or associated with some other cardiovascular anomalies. Infants with a large ductus are usually symptomatic with tachypnea, tachycardia and difficulty in feeding. Failure to thrive and recurrent respiratory tract infections are also quite common. Early closure is generally required to relieve the symptoms. Although coil closure is effective, procedural failure is not uncommon in infants with a large ductus, and using large and multiple coils in infants frequently results in left pulmonary artery stenosis.

Meanwhile, residual shunt is more common in infants undergoing closure with coils than with the ADO. The mean fluoroscopic and procedural times are shorter with ADO closure than with coil closure for large ductus, so the ADO seems to be the ideal device to use in infants with a moderate-to-large PDA. However, difficulties in the deployment of the ADO in young children have been reported[30][31][32] ; for example, kinking of the sheath may occur while advancing the device to the right ventricular outflow tract, although this can be solved by snaring the sheath from the

descending aorta[30] or using an Amplatzer vascular plug pushing cable. Left pulmonary artery stenosis is not uncommon following deployment of ADO, but is usually mild ($V_{max} < 2.5$ m/ s).

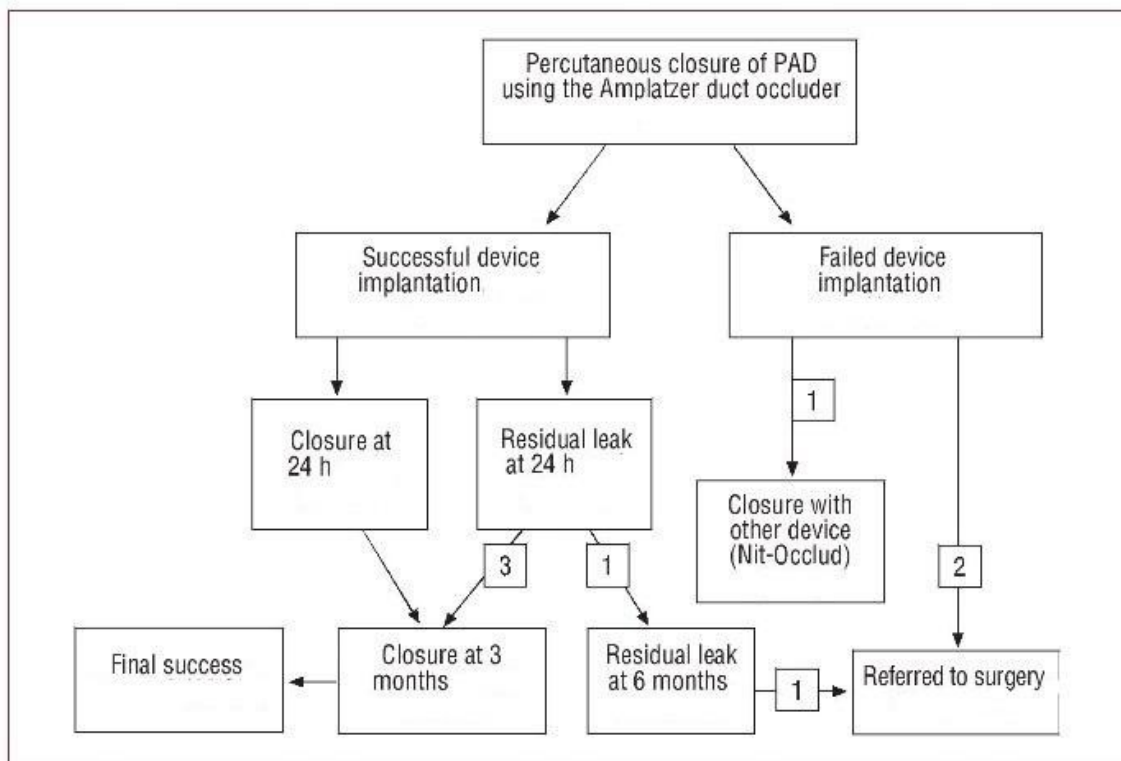
[29] [33] Avoiding using an excessively over-sized device in infants may decrease the incidence of this complication. Coarctation of the aorta following implantation of an ADO is not rare, but occurs mostly in young infant, in whom an excessively oversized device is implanted, resulting in protrusion of the retention flange into the aorta. An angled device can be useful in infants with a relatively short ductus to minimize protrusion of the upper part of the retention flange. [34] Recently, a swivel-disk device has been developed to diminish the possibility of developing a pressure gradient in the aorta.

F. POST CATHETERIZATION CARE

The patient can be sent home 6–8 hours after the procedure once recovery from sedation or anesthesia is complete especially if arterial access has not been used.[35] For children in whom arterial access was obtained we choose to keep them overnight,

Chest radiography and transthoracic echocardiography were conducted 24 h after the procedure to evaluate the shape and position of the device. Patients had follow up in the Pediatric Cardiology unit at intervals of 24 h then at 1 month, 6 months, and 12 months after the procedure. Patients were checked clinically for any evidence of cardiac murmur during each follow-up. Complete echocardiographic data (left pulmonary artery and aortic Doppler interrogation) in addition to evaluation for residual shunting.

Antibiotic prophylaxis for endocarditis be maintained after the procedure.



G. COMPLICATIONS

I. Embolization to the Branch Pulmonary Arteries (Fig.9)

This can happen soon after coil release or rarely within 24 hours or exceptionally after that. The dislodged coils usually embolize to the proximal right or left pulmonary arteries if they are large and if multiple coils are used. Single coils usually embolize distally to smaller branches. Sufficient time is available for planned retrieval because instability is rare. The long sheath should be retained in the MPA. A 4 French multipurpose catheter or the 4F snare catheter should be passed via the long sheath and positioned near the embolized coil mass with the help of a glide wire guided by the movement of the coil when it comes in contact with the wire. An Amplatz gooseneck snare (5 mm for children and small vessel embolization, 10 mm for other situations) should be used to grasp the coil tip. When multiple coils have been used for PDA closure it is important to hold the coils at the sutured end. The

coils must be captured into the long sheath in the pulmonary artery because it is important to prevent the coil mass to be entangled in the tricuspid valve tensor apparatus.

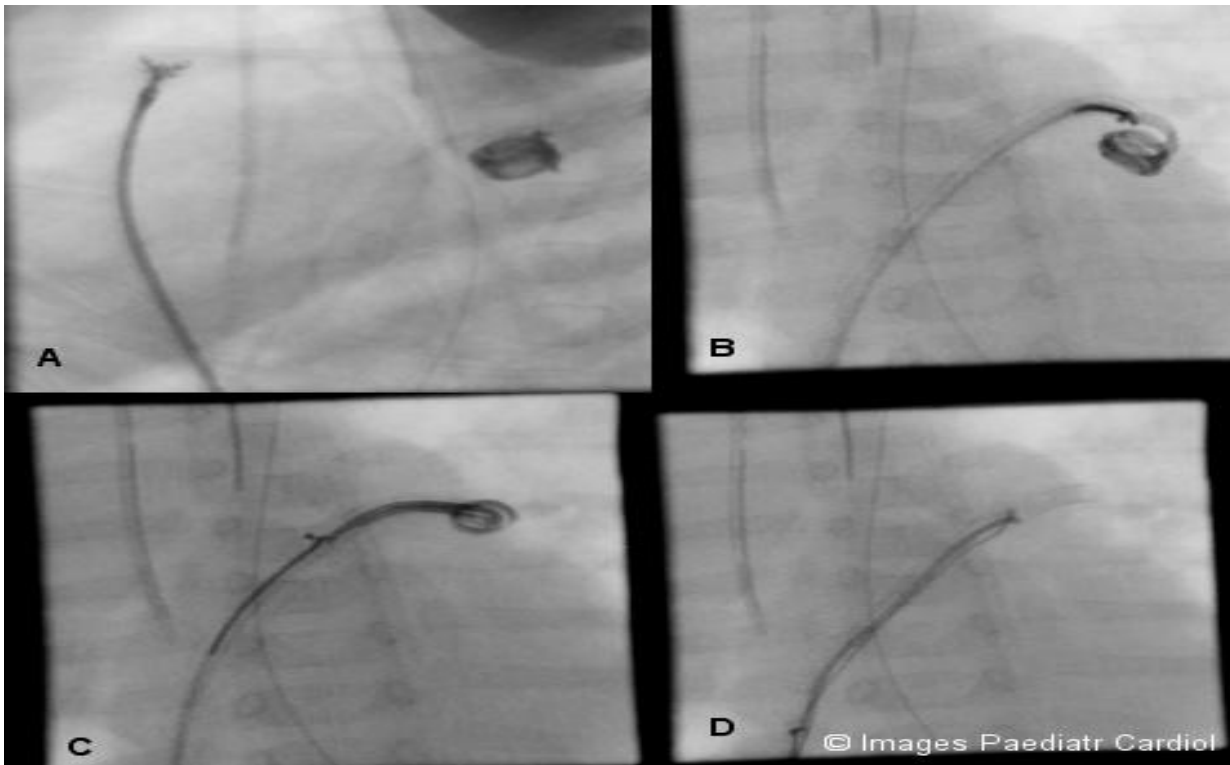


Figure.9 Retrieval sequence after embolization into the left pulmonary artery. Two coils were used to close a large duct in an infant. These coils embolized as soon as the jaws of the bioprobe were opened into the LPA (A). The sutured end of the coils have been grasped by a snare (B) and withdrawn into a long sheath in the proximal left pulmonary artery (C and D).

II. Embolization to the descending thoracic aorta (Fig. 10)

When coil(s) embolize into the aorta, the duct should be immediately re-crossed with a 5F multipurpose catheter or snare catheter. A 10 mm Amplatz gooseneck snare (Microvena, MN, USA) should be used to hold the end of the coil(s) and the same coil(s) can be deployed in the duct once again as the catheter is pulled back towards the MPA.

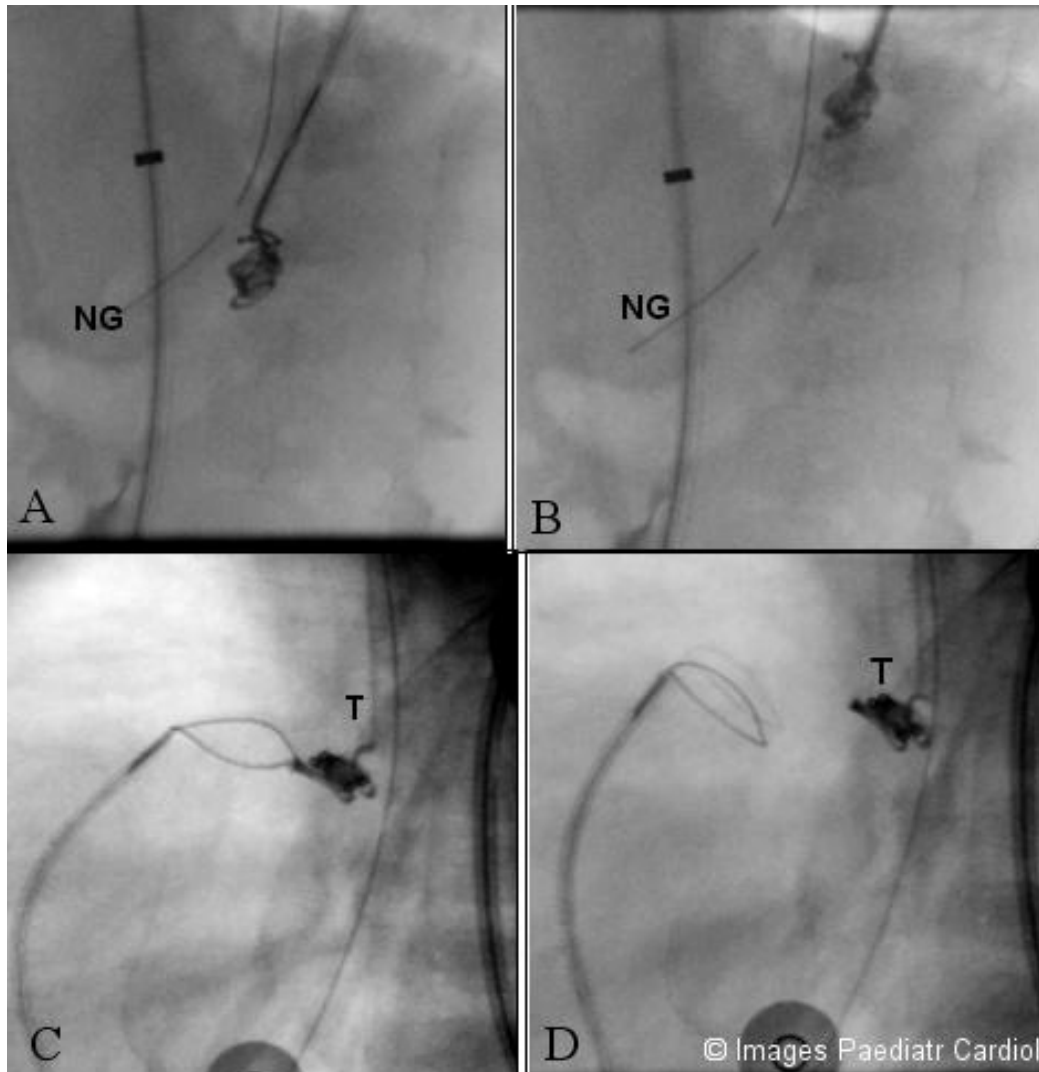


Figure.10 Retrieval sequence after embolization into the descending aorta. The snare catheter is introduced via the femoral vein and advanced into the descending aorta via the duct. The sutured end of the coil is grasped by the snare (A) and withdrawn (B) until the coil mass is firmly anchored in the duct ampulla (C). The snare is released after ensuring a secure position (D). NG: Naso-gastric Tube, T: tracheal air shadow

III. Loss of grip on the coil mass

The jaws of the biptome may sometimes lose their grip on the coil mass when coils are being pulled back into the long sheath after an initial unsatisfactory deployment. A variable part of the coil remains in the sheath. Attempts to recapture the coils with the biptome or a snare are unlikely to succeed and the coils may get pushed out of the sheath. A 3 F vascular retrieval forceps (Cook) works well in this situation. The tip of the vascular retrieval forceps has a short (3 cm), soft guide wire that can be positioned adjacent to the coil tip in the sheath. The jaws of the forceps open adequately enough to grasp the coil tip and retrieve the coil mass.

IV. Inability to release the coil after biptome jaws are opened

Occasionally coil tip remains in the jaws after they are opened. The coils can be released by slow rotation the biptome with the jaws open. Alternatively, advancing the long sheath to the jaws of the biptome helps in the release of the coil.

V. Hemolysis from residual flows

Hemolysis is a rare but a serious complication of coil occlusion.[35][36] for hemolysis to occur there often has to be clearly defined residual flow at the end of the procedure together with an audible murmur.

The occurrence of hemolysis correlated significantly with both age as well as duct size.

VI. Infective endocarditis .

Transcatheter closure of atrial septal defect

A. Introduction

Atrial septal defect (ASD) is one of the common congenital heart diseases with a prevalence of 1.6 per 1,000 live births and accounting for 8–10% of all congenital heart defects (CHD) (37). These defects may be small, medium, or large in size and oval, circular, or irregular in shape. The majority are single defects; however, multiple defects and fenestrated defects may occasionally be seen. Left to right shunt across the ASD produces dilatation of the right atrium, right ventricle, and main and branch pulmonary arteries. Pulmonary vascular obstructive disease does not manifest until adulthood, and even then it is rare, at least until late adulthood.

There has been a remarkable improvement in the treatment strategy of atrial septal defect (ASD) over the last few decades. Indebted to the improvement in device technology and procedural techniques, transcatheter closure of ASD is currently accepted as the treatment of choice in most patients with ASD. Recent generation devices enable easy and safe deployment of device with the properties of adequate flexibility, recapturability and repositioning. Use of biocompatible materials with improved device design and refined equipment finish may promote re-endothelialization and reduce potential damage to nearby structures. Most of currently available devices show excellent efficacy and comparable outcome with its own advantages and disadvantages. In addition to improvement of device properties and performance, there has been distinct improvement in procedural technique from numerous experiences of device closure of ASD. Nowadays there are well established principles regarding patient selection, pre-procedural evaluation, step-by-step details of procedure as well as post-procedural follow-up. However, an operator may encounter pitfalls in closing complex lesions such as large defect, rim

deficiencies and multiple defects, so every operator has to be familiar with each available device, general principle as well as special issues for complex lesions.

B. Principles and issues of device closure of ASD

Patient selection is an important initial step for a successful treatment. Procedure in the catheterization laboratory may be summarized stepwise; (I) hemodynamic study and assessment of morphologic characteristics of the defect; (II) establishment of procedural strategy including procedure-guiding modality and equipment to be used; (III) selection of optimal type and size of device; (IV) device implantation with cautions for potential complications including air embolism, damage to cardiac/vascular structures; (V) post-implantation assessment of the final result. After a successful procedure, appropriate patient education and follow-up are also essential parts of the treatment. Details and special considerations for each step of the procedure have well been described previously (38). There are individual issues which are often in debate including procedure-guiding modalities, sizing the defect, and closing complex defects.

➤ Issues on imaging guidance and defect sizing

Although there have been studies reporting device closure guided only by either fluoroscopy or echocardiography (39,40), it is generally recommended to perform the procedure under both fluoroscopic and echocardiographic guidance. For echocardiographic guidance, transesophageal echocardiography (TEE) has long been the standard modality for ASD closure. However, intracardiac echocardiography (ICE) is

gradually replacing the role of TEE recently. Transthoracic echocardiography (TTE) may also be used especially in patients with good windows for echocardiography such as small children (41).

There has been debate on the necessity of balloon sizing for selection of device size. Balloon sizing may be skipped in suitable defects with sufficient surrounding rims (42); however, it has long been regarded as an essential step of the procedure (43). Indeed, balloon sizing may provide more information than averaged size of the defect including compliance of surrounding rims and presence of additional defect.

While the balloon stretched diameter or balloon occlusive diameter were used in balloon sizing in the past, currently stop flow diameter (SFD) is recommended as the standard measurement to avoid oversizing (44). In self-centering devices such as the Amplatzer Septal Occluder (ASO) (St. Jude Medical, St. Paul, MN, USA), the recommended device size is the same or slightly larger (<2 mm) than the SFD. Nevertheless, the selection for device size should be individualized considering deficiency of rims, spatial relationship with nearby cardiac structures and size of the heart. In cases with aortic rim deficiency, the usual recommendation is to avoid an “oversized” device because of the potential risk of erosion (47). On the other hand, in cases with inferior vena cava (IVC) rim deficiency with higher risk of device embolization, use of an “undersized” device should be avoided. In case of using a non-self-centering device such as the Gore Septal Occluder (GSO) (WL Gore & Associates, Inc., Flagstaff, AZ, USA), a device twice the size of the defect is recommended (45), and the GSO is not recommended for defects >18 mm (46).

➤ ***Complex lesions***

Large defect

Large size of the defect may be the most common cause of difficulties in ASD closure using a device. The main problems are prolapse of left atrial (LA) disk of the device into the right atrium (RA) before proper positioning in the septum (47) and difficulty in sizing the defect. Device size is frequently selected by estimation rather than measurement of balloon diameter due to non-visualization of the whole defect in a single echocardiographic plane, difficulty in stabilization of the sizing balloon (melon-seeding or milking) and unavailability of sizing balloon larger than 34 mm.

Various modified implantation techniques have been suggested to overcome the problem with LA disk prolapse (*Table 1*). An operator should be familiar with his/her own technique to overcome this problem. The balloon-assisted technique may be helpful even in cases when other methods failed.

Table 1 Various technical modifications to prevent left atrial disk prolapse during device positioning

1. Waist deployment in LA
2. Rotation of sheath in LA (15)
3. Bending (pre-shaping) (15)/cutting of sheath tip (16)
4. RUPV technique (14,17)
Hypomochlion technique, LA roof technique
5. LUPV technique (14)
6. Stiff sheath (dilator) technique (18)
7. Use of Hausdorf-Lock sheath (14)
8. Balloon-assisted technique (19-21)
9. Straight side-hole delivery sheath technique (22)
10. Steerable sheath technique (23)
11. Use of JR coronary guiding catheter (24)

LA, left atrium; LUPV, left pulmonary vein; RUPV, right upper pulmonary vein; JR, Judkin's right.

Rim deficiencies (*Figure 11A,B,C,D,E*)

Deficiency in the surrounding rim(s) is frequently associated with large defects, and may potentially increase the risk of complications such as device embolization, erosion and encroachment of device onto nearby cardiac structures.

Aortic rim (antero-superior rim, *Figure 11A*) deficiency is most common rim deficiency (48) and device implantation is frequently interfered by LA disk prolapse. Erosion risk is higher in aortic rim deficiency as well as device oversizing, thus device selection has to be refrained from undue oversizing.

IVC rim (posteroinferior rim, *Figure 11B*) deficiency is second most common among rim deficiencies and associated with higher risk of device embolization (49). In case with this rim deficiency, under-sizing of the device

may further increase the risk of device embolization, and should be avoided. It is difficult to visualize IVC rim with TEE guidance, so ICE is preferable imaging modality in patients with IVC rim deficiency (50); however, so called ‘modified retroflexed view’ may be helpful to visualize IVC rim with TEE guidance (51).

Superior vena cava (SVC) rim (posterosuperior rim, *Figure 11C*) deficiency is a rare condition and may interfere with device positioning (52). When the rim deficiency is extended from SVC rim to aortic rim, this indicates the defect is located superiorly in the atrial roof and may carry higher risk of erosion (47,53).

In case with posterior rim (*Figure 11D*) deficiency, the feasibility of device closure may be decided by the extent of rim deficiency (*Figure 12*). In the presence of rim deficiency in large area from IVC to posterior rim, the risk of device embolization is very high and this condition may preclude device closure.

In atrioventricular valve rim (*Figure 11E*) deficiency, encroachment of device onto the mitral and/or tricuspid valve is a potential problem. This is a concern especially in infants and young children because of the inherent design of Amplatzer-type devices which have a relatively larger disk-rim width in smaller devices. In case of device encroachment onto the valve, it is generally recommended not to implant a device. There is an extremely rare documented case of erosion on mitral valve (54).

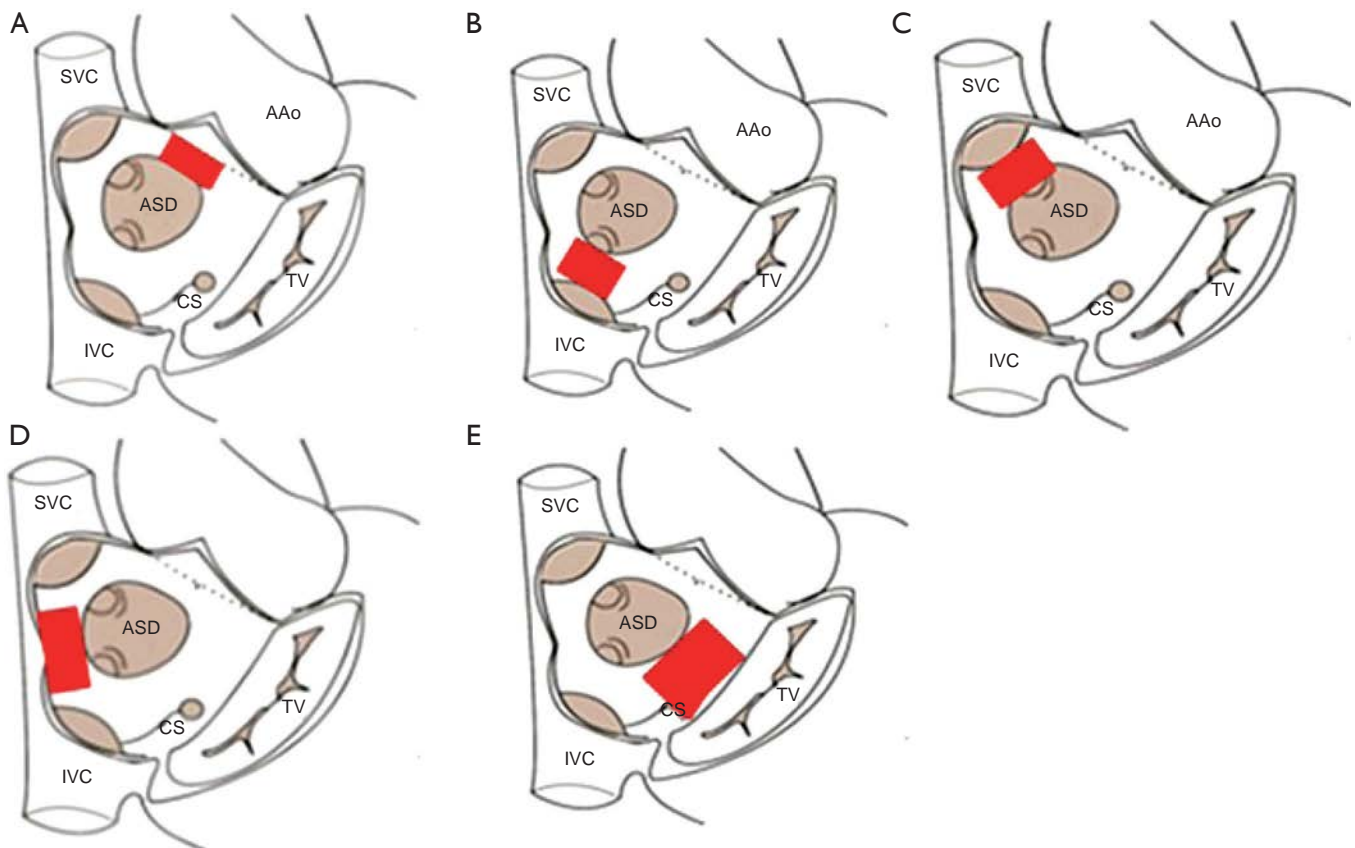


Figure.11 The locations of rim deficiencies: (A) aortic rim, (B) IVC rim, (C) SVC rim deficiency, (D) posterior rim, (E) atrioventricular valve rim. SVC, superior vena cava; IVC, inferior vena cava; ASD, atrial septal defect; CS, coronary sinus; AAo, ascending aorta; TV, tricuspid valve.

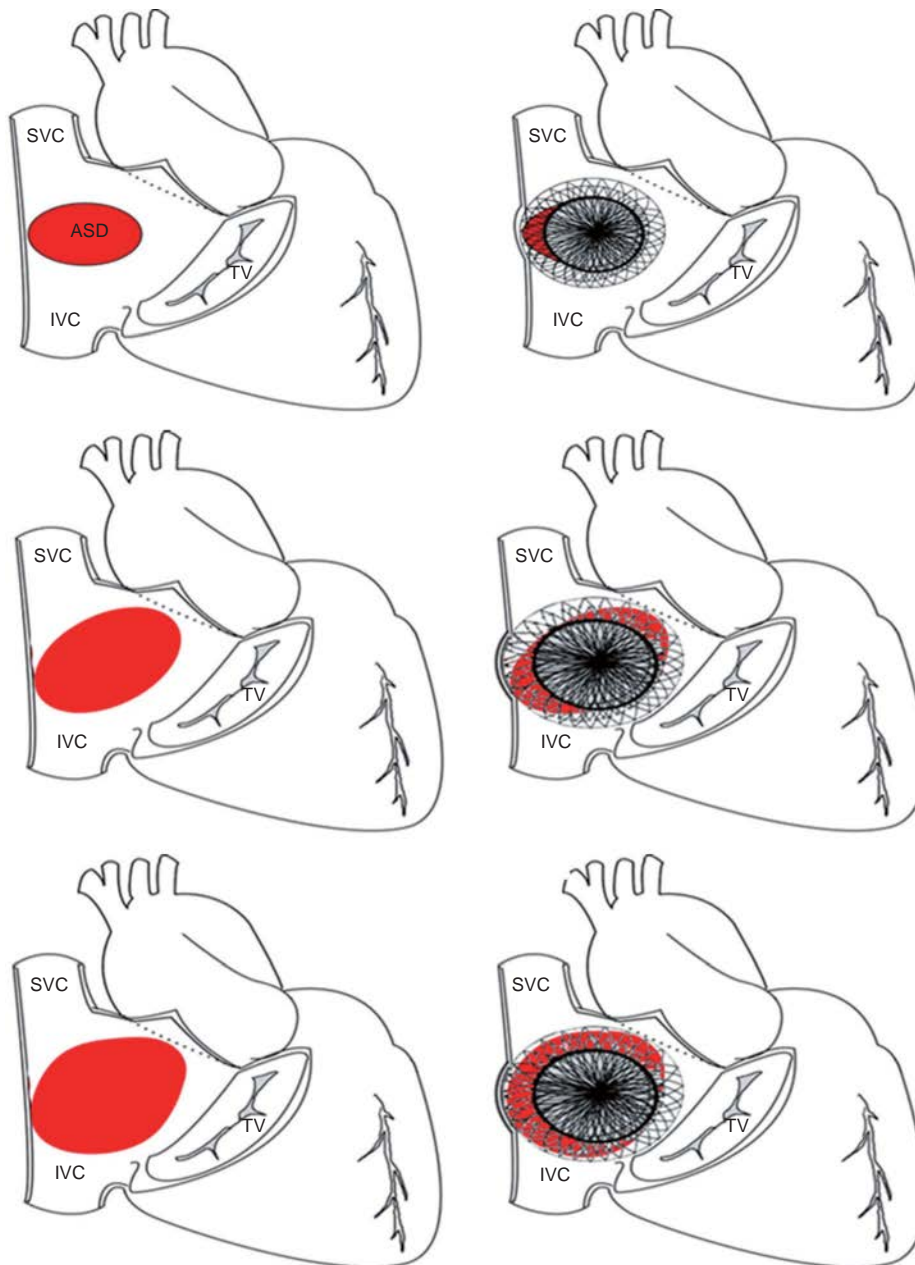


Figure.12 Illustration of feasible (A), borderline (B) and unfeasible (C) defect for device closure in posterior rim deficiency. For the defects with posterior rim deficiency, the extent of rim deficiency determines feasibility of device closure, so the clear anatomic definition is very important. SVC, superior vena cava; IVC, inferior vena cava; AAO, ascending aorta; TV, tricuspid valve.

Multiple defects

There are many challenges or considering factors when planning closure of multiple ASDs, including numbers/ size of the defect, location/spatial relationship between the defects, properties of supporting rims or intervening septum as well as presence of septal aneurysm. Ultimately, understanding the accurate anatomy and properties of surrounding/intervening rims of multiple defects is the cornerstone of successful device closure. To overcome these problems, proper use of real time 3-dimensional (RT3D) echocardiography may be helpful (55,56). RT3D echocardiography enables visualization of the wide ranged septum in a single view in the echocardiography and provides instantaneous understanding of the anatomy as well as identification of complex morphology and spatial relationship between multiple defects (*Figure 13*).

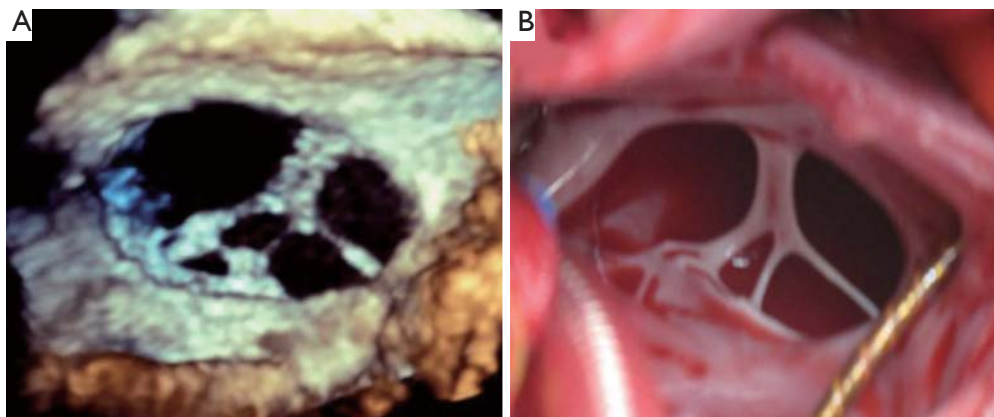


Figure.13 Real time 3-dimensional (RT3D) echocardiography is very useful to assess morphologic characteristics for multiple defects. Note the similarity between the realistic image from RT3D echocardiography (A) and actual image of the defect from the surgical field (B).

Temporary balloon occlusion test may also be useful to investigate compliance of surrounding rims and intervening septum, as well as to predict changes of the defects and rims after device implantation. Also, a careful observation of fluoroscopic images with balloon sizing may provide additional information on the spatial relationship between the defects and intervening septum (*Figure 14*). In case of device closure of multiple defects using multiple devices, the optimal combination of devices based on the comprehensive information from RT3D echocardiography and balloon occlusion test is required to prevent unfavorable interference between multiple devices (*Figure 15*). Usually, a small additional defect adjacent to a larger defect (<7 mm in distance) can also be closed by implantation of a single device in the major defect (57). When the additional defect is also sizable or defects are in distance each other, use of multiple devices is required. For multi-fenestrated defects with a large septal aneurysm, patch-like closure using a non-self-centering device may be a good option (*Figure 16*).

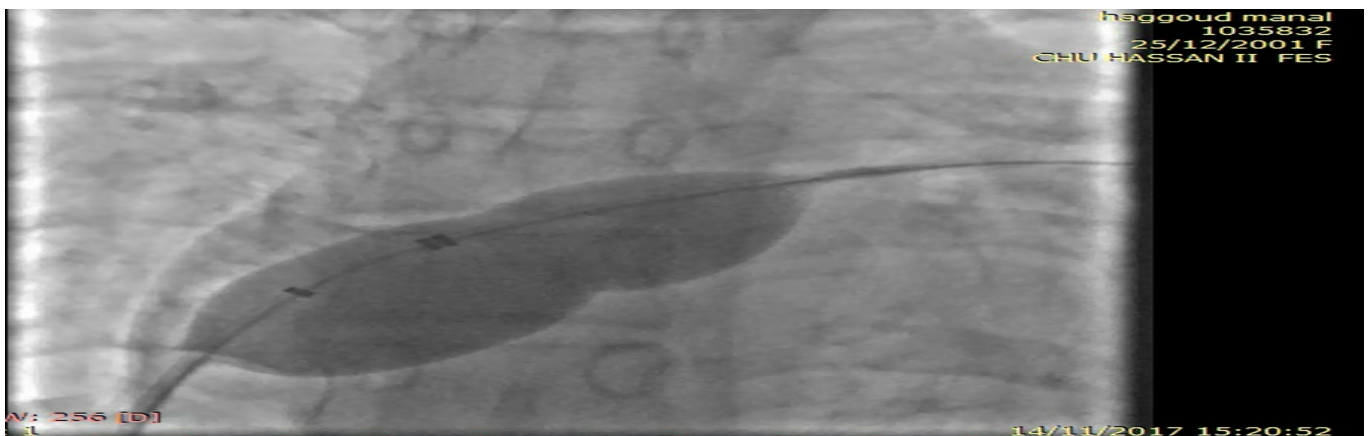


Figure.14: Careful observation of fluoroscopic image with balloon sizing may provide additional anatomic information on the defects and intervening septum.

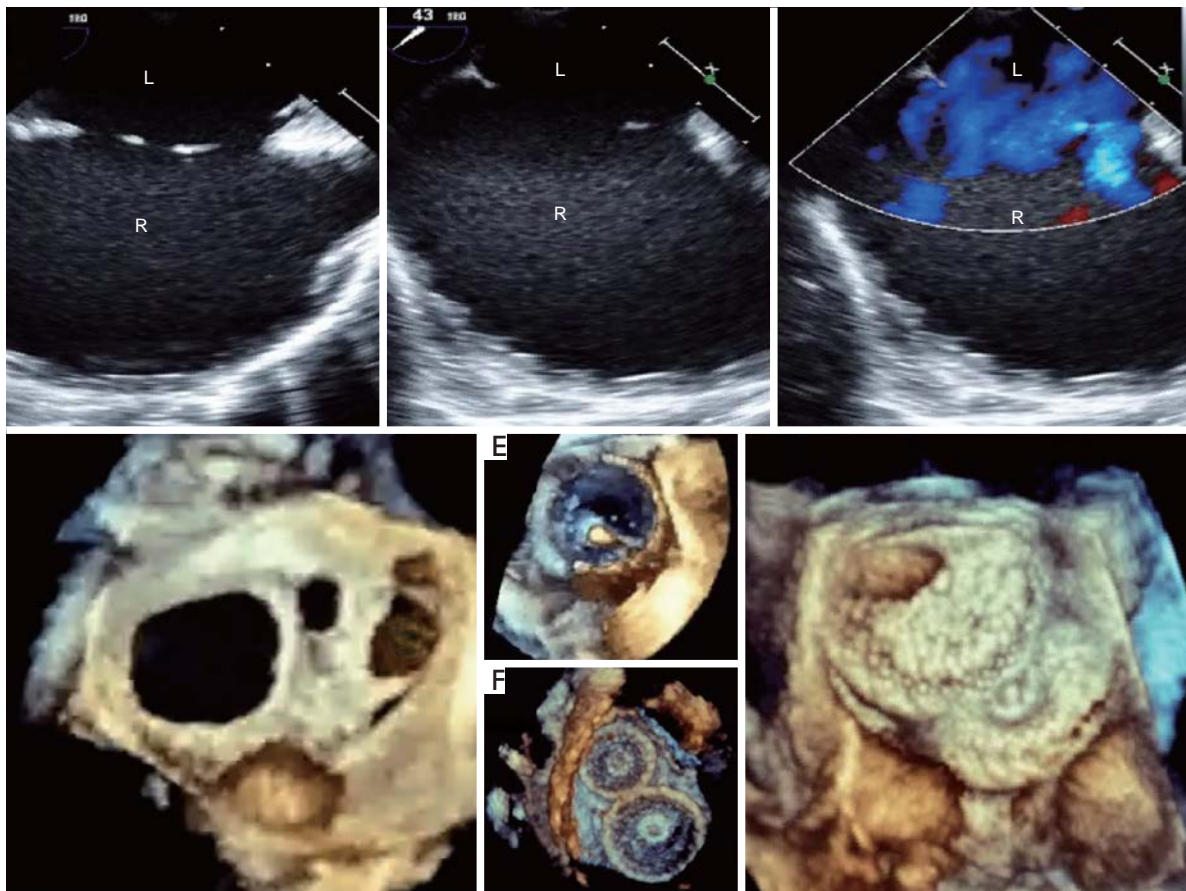


Figure.15: Advantages of real time 3-dimensional (RT3D) transesophageal echocardiography (TEE) guidance in device closure of multiple ASDs. True anatomy of multiple defects is difficult to understand by 2-dimensional (2D) TEE images even in multiple views (A,B) with color flow Doppler (C), however the anatomic characteristics including number of the defect, shape/size of each defect and spatial relationship between the defects are clearly shown on RT3D image (D). RT3D echocardiography also provides excellent images during balloon sizing (E) and post-assessment of the device position (F,G).
LA, left atrium; RA, right atrium.

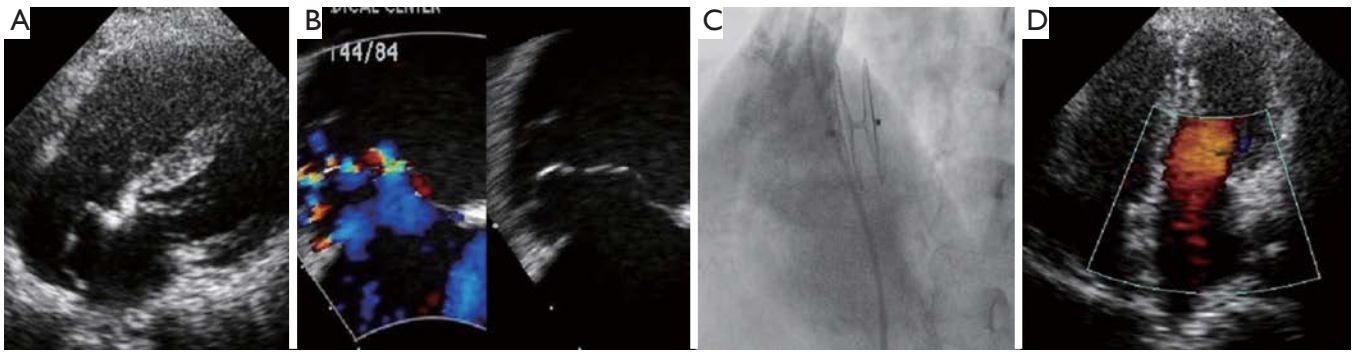


Figure.16: Patch-like closure using non-self-centering device is a good option for multi-fenestrated defects with a large septal aneurysm. Transthoracic echocardiography (A) and transesophageal echocardiography (B) shows multi-fenestrated defects with a large septal aneurysm. A 35mm cribriform device (C) was implanted in the center hole of the aneurysm instead of larger eccentric hole to achieve a complete coverage of base of the septal aneurysm. Follow-up echocardiography shows a patch-like closure of defects and septal aneurysm (D).

C. Indications for ASD closure

Closure of moderate to large ASDs is recommended, even in the absence of symptoms at presentation. The reasons for such recommendations are to 1) prevent the development of pulmonary vascular obstructive disease in adulthood, 2) decrease the chances of supra-ventricular arrhythmias later in life, and 3) preclude the development of symptoms during adolescence and adulthood. Elective occlusion at four to five years of age is usually recommended. Closure during infancy is not required unless the infant is symptomatic.

Small defects (<5 mm) are likely to spontaneously close and do not need occlusion. Evidence for right ventricular volume overloading (dilatation of right atrium and right ventricle with flat or paradoxical interventricular septal motion) by echocardiogram is used by most cardiologists as an indication for closure. If cardiac catheterization is performed, pulmonary to systemic flow ratio ($Q_p:Q_s$) >1.5 is an indication for closure.

The above are developed largely to address secundum ASDs. Similar criteria are used for closure of ostium primum, sinus venosus, and coronary sinus ASDs. The degree of mitral insufficiency is an additional consideration in ostium primum ASDs.

D. TECHNIQUES OF percutaneous ASD closure

Right and left heart cardiac catheterization was performed for hemodynamical study under general anesthesia. Before the procedure, all patients underwent physical examination, ECG, chest X-ray, and complete blood examination. Transthoracic echocardiography was also performed to confirm the diagnosis and assess the suitability of the defect closure. During the procedure transesophageal echocardiography (TEE) was performed. Heparin (100 IU/kg) was administered to prevent clotting and embolism. To visualize the atrial septum and the defect, angiocardiology was performed in the right upper pulmonary vein in the 4-chamber view. The stretched diameter was measured for balloon sizing in the majority of cases. Devices were selected on the basis of the stretched diameter or 1 mm larger. The device was advanced via the long sheath to the left atrium by pushing the delivery cable. The device was then deployed in the left atrium under fluoroscopic and TEE guidance. Intravenous (IV) cefazolin (1 g) was given to prevent bacterial endocarditis and aspirin was prescribed at a dose of 5 mg/kg daily for 3 months to avoid thromboembolic events. Cefazolin was given 30 minutes prior to procedure and followed by 1 g IV every 8 hours for an additional 2 doses. Follow-up studies were done on the 1st day, 1 month, and 6 months after the procedure, and included transthoracic echocardiography, chest X-ray, and electrocardiography.

E. devices for ASD closure (Figure 17)

I. ASO (Figure 17A)

The ASO is the first self-expanding double-disk device with central connecting waist composed of nitinol-wire-mesh. The disks and waist were sewn with a Dacron patch to promote complete occlusion and endothelialization. The device allowed easy and straightforward deployment due to its self-centering, repositionable, and recapturable characteristics. The ASO solved many limitations of previous devices such as the non-negligible rate of residual shunt and frame fracture, and is regarded as a prototype device for many newer devices. The device size is determined by the waist size; there are 27 device sizes from 4 to 40 mm (in 1-mm increments between 4 to 20 mm and 2-mm increments between 20 to 40 mm). The corresponded delivery sheath sizes range from 6 to 12 French (Fr).

The ASO “cribriform” is a specially designed non-self-centering device for multi-fenestrated defects with 4 available sizes from 18 to 40 mm.

II. Occlutech Figulla Flex II ASD Occluder (Figure 17B)

Figulla Flex II ASD Occluder (FSO, Occlutech GmbH, Jena, Germany) is the third generation Occlutech device for ASD closure with a flexible titanium-oxide coated nitinol-mesh and double-disk design similar to ASO. FSO has minimized metal contents especially in the LA disk and no clamping hub on the LA disk, which may provide more flexible and less traumatic feature. The FSO has a distinct release mechanism resembling a bioptome which enables flexible movement between the device and delivery cable. The delivery cable is also shapeable for a better alignment between the device and septum.

There are 20 device size options from 4 to 40 mm (1-1.5-mm increments between 4 and 21 mm, 3-mm increments between 21 and 39 mm, and 40 mm). Retrospective comparison studies showed a compatible efficacy and safety comparing to ASO (58,59).

III. GSO (Figure 17C)

The GO is a non-self-centering double disk device composed of platinum filled nitinol wire framework covered with an expanded polytetrafluoroethylene (ePTFE) membrane to promote rapid endothelialization. The GSO is preloaded as a package of the device and whole delivery system. The delivery system has improved for easier delivery and position compared to that of the previous Helex Septal Occluder (HSO). There are 4 device sizes from 15 to 30 mm with 5-mm increments. It is generally recommended that the device size should be more than twice the defect size and the GSO is not suitable for defects over 18 mm due to the non-self-centering feature. Owing to its flexibility with minimal metal content which may prevent erosion, the device is preferred to close smaller defects especially with aortic rim deficiency or those in small children (60).

The Gore Cardioform ASD Occluder (GAO) is a self-centering version of GSO which consists of a helical nitinol-wire frame covered with ePTFE to treat larger ASDs. The available sizes are 27, 32, 37, 44, and 48 mm and designed to treat defects from 8 to 35 mm. Although this device is not commercially available yet, the initial clinical result showed the safety and efficacy of the GAO (61). The risk factor for procedural failure in GAO implantation was a larger defect size, especially a size larger than 27 mm by balloon sizing.

IV. CeraFlex ASD Occluder (Figure 17D)

CeraFlex (LifeTech Scientific Co., Shenzhen, China), the 4th generation ASD device from LifeTech, is a nitinol-wire-mesh device coated with titanium nitride. This device is preloaded as a package and has a similar feature to other nitinol-wire-mesh devices such as self-expanding property and double-disk design with central waist. Ceraflex has couple of shared features with FSO; a coated surface of nitinol-wire, flexible connection between the device and delivery cable, and no hub on LA disk. A total of 19 sizes are available from 6 to 42 mm with 2-mm increments, and the delivery sheath sizes range from 8 to 14 Fr.

The disadvantages are its relatively limited size options (19 *vs.* 27 sizes in ASO) and the requirement of a slightly larger delivery sheath than with ASO devices.

V. Cocoon Septal Occluder (Figure 17E)

The Cocoon Septal Occluder (Vascular Innovations Co., Nonthaburi, Thailand) is a self-expanding double-disk device consists of a nano-platinum coated nitinol device filled with polypropylene fabric. The device is quite similar to ASO in terms of device design except for the nano-platinum-coated surface which prevents nickel release to the blood stream (62), promotes biocompatibility and enhances radio-opacity on fluoroscopy. There are 17 device options ranging from 8 to 40 mm with 2-mm increments and the delivery sheath sizes range from 7 to 14 Fr.

This device has been described as softest and lightest currently available device with less metal-to-septum ratio than other devices (63). The disadvantages are its relatively limited size options (17 *vs.* 27 sizes in

ASO) and the requirement of a slightly larger delivery sheath than with ASO devices.

VI. Nit-Occlud ASD-R (Figure 17F)

The Nit-Occlud ASD-R (NOA-R) (pfm Medical, Cologne, Germany) is a double-disk, self-expandable, self-centering device; however, the device characteristics are quite different from other nitinol-mesh devices. NOA-R has reduced amount of metal on the left atrial disk without clamping or screwing hub on either side of the atrial disks and has a “reverse configuration” of the single-nitinol-layer on the LA disk (the “R” on the product name indicates this). These characteristics may allow more flexible and conformable device positioning on the septum. The release mechanism is unique as it is “snare-like,” which includes a central locking wire and a pusher with a distal wire noose (64). A total of 12 sizes are available from 8 to 30 mm with 2-mm increments, and the delivery sheath sizes range from 8 to 14 Fr.

The disadvantages (are its relatively limited size options (12 vs. 27 sizes in ASO), and the requirement of a slightly larger delivery sheath than with ASO devices and inability to close larger defects.

VII. Cardi-O-Fix Septal Occluder (Figure 17G)

The Cardi-O-Fix septal occluder (Starway Medical Technology, Beijing, China) is a self expandible double disk design device consists of nitinol wire mesh filled with polyester fabric sewn to waist and each disk. This device is structurally similar to the ASD, however this device has two different versions of products with or without clamping hub on the LA disk. A total of 27 sizes are

available from 4 to 40 mm (1-mm increment between 4 to 20 mm and 2-mm increment between 20 to 40 mm), and the delivery sheath sizes range from 7 to 14 Fr.

The disadvantages may include less experience/data with this device and the requirement of a slightly larger delivery sheath than with ASO.

VIII. Ultracept II ASD Occluder (Figure 17H)

The last generation of CARDIA ASD closure device, the Ultracept II ASD Occluder (Cardia, Eagan, MN, USA) is a double-round disk, self-centering, low profile device. It has a nitinol frame with a polyvinyl alcohol (PVA) coating to reduce thrombus formation. A total of 15 sizes are available from 6 to 34 mm with 2-mm increments, and the delivery sheath sizes range from 9 to 11 Fr. Several cases of PVA-membrane perforation or degradation were reported (65,66), which were also reported with the previous generation device (67). Despite comprehensive investigations on the PVA membrane, the mechanism of degradation has not been identified. Some authors emphasized that the interventionist should be aware of this rare complication (66).

IX. Carag Bioresorbable Septal occluder (Figure 17I)

Carag Bioresorbable Septal Occluder (CBRO) (CARAG AG, Baar, Switzerland) is a self-centering, double disk device without any metal framework, composed of poly lactic-co-glycolic acid (68). Endothelialization of the device seems to be completed within 3 months, while the device usually starts to be resorbed after 6 months and completely resolved within 2 years. CBRO has 3 size options: small for 4–12 mm defects, intermediate for 13–20 mm, and large for 21–25 mm.

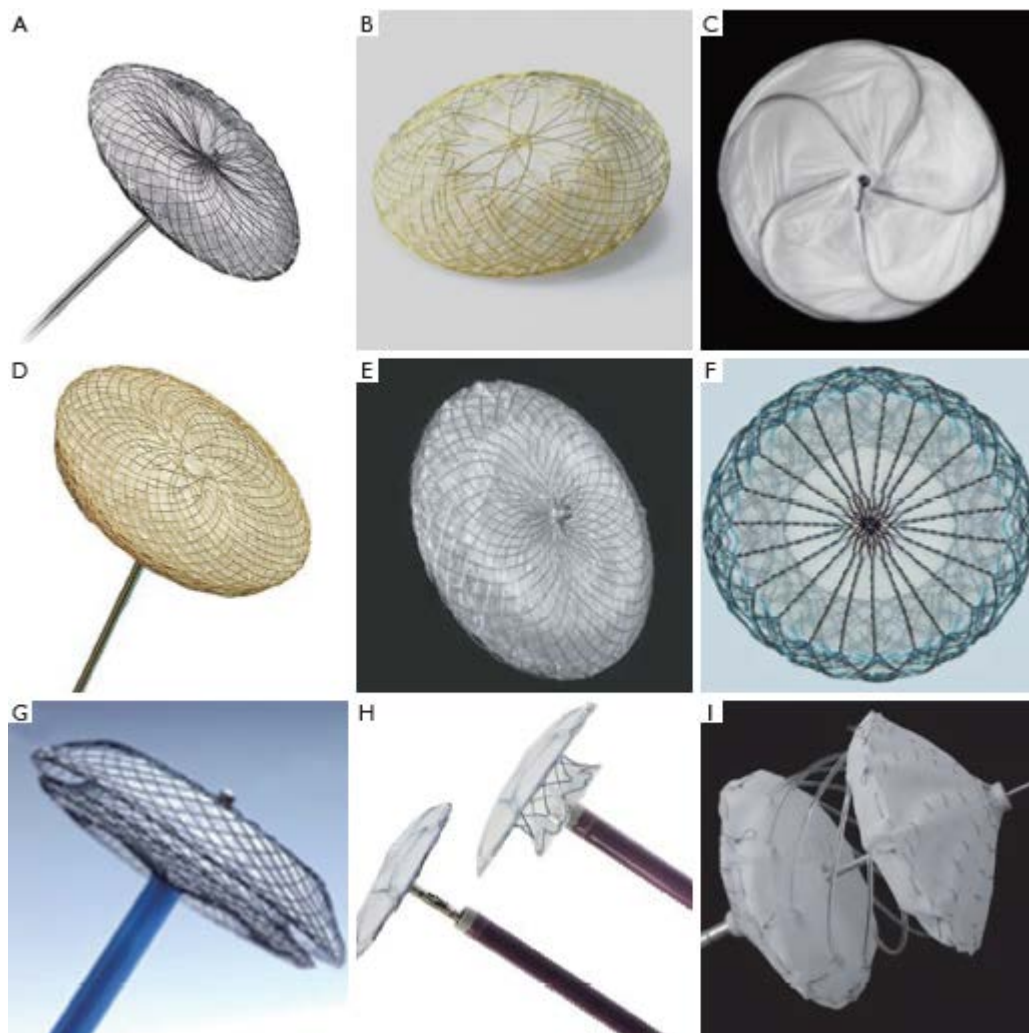


Figure. 17: Currently available devices for atrial septal defect closure. (A) Amplatzer Septal Occluder; (B) Occlutech Figulla Flex II device; (C) Gore Cardioform Septal Occluder; (D) Cocoon Septal Occluder; (E) CeraFlex ASD device; (F) Nit Occlud ASD-R device; (G) Cardi-O-Fix Septal Occluder; (H) Ultracept II ASD Occluder and (I) Carag Bioresorbable Septal occluder.

F. COMPLICATIONS

I. Groin hematoma & femoral arteriovenous fistula

Groin hematoma and femoral arteriovenous fistula are not infrequent and are probably under-reported. They result from inadvertent arterial puncture and/or the introduction of relatively large venous sheaths and an anticoagulation/antiplatelet protocol in the immediate postprocedural period. The post-catheterization groin should be treated with meticulous care.

II. Device embolization

Device embolization is not much of an issue in the PFO group and is mostly a consequence of technical mistakes during manipulation of the device. In the ASD group, correct sizing of the defect and hence device choice is not always easy and can cause the device to be in an unstable position with subsequent embolization. This can be avoided in many cases (but not always) by testing the device's stability before release ('wiggle'). Moreover, deficiency of the posterior rims, especially the posteroinferior rim, renders device stability very unlikely with device embolization within 12–24 h postimplantation. In most reports, device embolization occurs in less than 1% of procedures. Most devices can be retrieved by catheter techniques, but for the larger device in particular, one must be careful not to damage cardiac structures (valves and atrial wall) and surgical retrieval can be a safer alternative [69].

III. Erosion/perforation of the atrial wall with pericardial effusion or tamponade

This potentially lethal complication is rare, but can occur at any moment postimplantation and with any device. The incidence of this complication is estimated to be approximately 0.1%. The majority occurs within 3 days after the procedure, but a delay of several weeks is possible. The erosion can result in perforation of atrial and aortic wall, creating a fistula, but can also affect the atrial free wall, resulting in hemopericardium and eventually tamponade and death. Most patients will complain of chest pain and this specific complaint should always be taken seriously and checked using echocardiography. If a pericardial effusion has been confirmed, a cardiac CT can be ordered to differentiate between a (rare) inflammatory pericardial effusion and hemopericardium. Oversizing of the device is thought to be one of the causes and should be avoided, especially in the presence of deficient rims [70].

IV. Aortic incompetence

One report found an incidence of new or worsening aortic incompetence of approximately 10% after closure of PFO or ASD with the Amplatzer septal occluder or the Cardia PFO/ASD occluder [71]. The incidence seems to increase with the length of follow-up and is thought to result from traction on the noncoronary cusp due to endothelialization and tissue overgrowth. The aortic incompetence does not appear to be hemodynamically significant to date. No other series in the literature mentions this complication. Recently, another study addressed the impact of percutaneous closure of PFO on valve insufficiencies, evaluating the regurgitation fraction of the semilunar and atrioventricular (AV) valves by cardiac magnetic resonance imaging. No significant changes in regurgitation fraction of the four valves were found at 12 months of follow-up [72].

V. Coronary compression

A rare case of coronary insufficiency producing exercise angor has been described after closure of a PFO in a patient with an abnormal course of the circumflex coronary artery originating from the right coronary sinus. The abnormal coronary artery was compressed by the device [73].

VI. New-onset migraine

Although it is known that pre-existing migraine with aura tends to improve in some patients after PFO closure [74], some patients suffer from new-onset migraine after closure of PFO or ASD. Up to 10% of patients develop new-onset migraine in the first month after percutaneous closure of PFO and ASD [75]. Younger patients and those with previous migraine seem to be at risk. And although spontaneous recovery has been described [76], migraine seems to persist in the majority of patients (69%) [75]. Symptoms often respond to the combination of aspirin and clopidogrel.

VII. Arrhythmias

Atrial arrhythmias, supraventricular arrhythmias and transient AV block have been described after ASD and PFO closure. Atrial fibrillation is of particular concern since the occurrence or persistence of atrial fibrillation after the closure of ASD/PFO seems to be associated with an increased risk of device thrombosis and recurrence of thromboembolic events . Atrial fibrillation does not occur in children, but the risk in adults increases with age . In fact, atrial fibrillation is part of the natural history of older patients with ASD. Some devices seem to increase the risk for postprocedural atrial fibrillation, but the data are contradictory . A series of 1349 patients was examined for the incidence and risk factors associated with the development of atrial fibrillation after PFO closure . Over a mean follow-up period of more than 3 years, 3.9% of patients developed new-onset atrial fibrillation. Of these, 62.3% developed

atrial fibrillation within 4 weeks and 15% within 6 months following PFO closure. These account for 3% of the total population studied and probably represent the patients in which the deployment of the device itself influenced the onset of the arrhythmia. Chronic atrial fibrillation was documented in only half of the affected patients. In those with persisting atrial fibrillation, aggressive treatment seems warranted, since persistent atrial fibrillation is associated with thrombus formation and recurrent thromboembolic events. If necessary, cardioversion can be performed safely (under anticoagulation).

Transient AV block is reported in up to 6%, varying from first to third degree. Most patients recover normal AV conduction within 6 months [77]. On rare occasions, temporary or permanent pacing is necessary [78]. A study addressing the association of AV block and closure of ASDs with the Amplatzer septal occluder found a larger shunt and device size to be the only determinant factors for AV block [77]. The variable timing of the occurrence of AV block postdevice implantation (1 day to 1 week) and the predominantly transient nature do not facilitate treatment options [77]. Close follow-up without medication or administration of steroids have been reported. Early device removal is probably not necessary.

VIII. Thrombosis & recurrent thromboembolic events

recurrent thromboembolic events are an important issue after percutaneous closure of a PFO, because closure is aimed at prevention of recurrences after a stroke with paradoxical embolus. A systematic review of nonrandomized studies of transcatheter closure or medical therapy for PFO reported a 1-year rate of recurrent thromboembolism of 0–4.9% with catheter intervention and 3.8–12% with medical therapy [79]. Prospective, randomized trials are still ongoing and the results are not yet available. The mechanism of the recurrences is not clear: thrombosis on the device has been reported, but without an association with clinical

thromboembolic events . As it is never certain in cryptogenic stroke that the PFO is part of the pathogenesis of the stroke, recurrent stroke is much more likely to be due to the original cause, which has not been diagnosed. Atrial fibrillation and increasing age have been identified as predictors of recurrent thromboembolic events. Residual shunting was also presumed to be a risk factor [80], but this was not confirmed in other studies . It has been postulated that the left atrial disk would be the substrate of the thromboembolic events. The missing association between device thrombi and thromboembolic events questions this hypothesis. For that matter, the development of new biodegradable devices such as the BioSTAR [81], designed to diminish the amount of synthetic material in the heart, has not yet provided any evidence that the rate of complications or recurrent thromboembolic events decreases.

IX. Left ventricular dysfunction

In elderly patients in particular, a restrictive physiology of the left ventricle can lead to LV dysfunction and pulmonary edema after ASD closure. In elderly patients, left atrial pressures can be measured during temporary balloon occlusion of the ASD. In patients with normal mean left atrial pressure during occlusion, definitive device closure of the ASD can be performed during the same session. Patients with LV restriction due to increased mean atrial pressures (>10 mmHg) can be preconditioned with intravenous inotropes and diuretics for 2 to 3 days [46]. If during a second session the mean left atrial pressures are significantly decreased with balloon-occluded ASD, permanent device closure can be performed [82]. If mean left atrial pressures remain elevated, the ASD can be closed with a fenestrated device, providing significant reduction of left-to-right shunting and avoiding excessive volume overload of the restrictive left ventricle [83].

Transcatheter closure of ventricular septal defect

A. Introduction

Isolated VSDs are the most common CHDs (provided that subjects with bicuspid aortic valve are excluded) and constitute 20 to 25% of all CHDs. They are most commonly classified on the basis of their location in the ventricular septum and are divided into perimembranous (situated in the membranous ventricular septum in the subaortic region), supracristal (found in the conal septum in the subpulmonary region), atrioventricular (AV) septal (defect located in the posterior septum), and muscular (located in the muscular and apical areas of the ventricular septum)[84,85]. The membranous defects are most common among the VSDs (80% prevalence), and supracristal (5 to 7%), AV septal (8%), and muscular (5 to 20%) defects are much less common. These defects may be large, medium, or small in size. Most of the defects are single; however, multiple defects may be present in the muscular septum, described as the “Swiss cheese” type of VSDs.

Left-to-right shunt across the VSD produces dilatation of the left atrium and left ventricle (LV). Owing to high pulmonary vascular resistance (PVR), this shunt may not manifest in the neonate and during the first weeks of life. As the pulmonary arterioles involute, PVR falls with resultant increase in left-to-right shunt. The right ventricle (RV) and main and branch pulmonary arteries may also be dilated in moderate to large defects. Whereas pulmonary vascular obstructive disease (PVOD) does not manifest until adulthood in patients with ASD, patients with VSD are likely to develop PVOD as early as 18 months to 2 years of age if a large VSD is left unrepaired.

B. Indications for ventricular septal defect closure

The indications for percutaneous closure of congenital VSDs remain and should be the same as for surgical closure.

The indications for fermeture percutanée depend, to a large degree, on the size and type of the VSD[84,86]. Closure of the VSD is not necessary in patients with a small VSD. Assurance of the parents and perhaps subacute bacterial endocarditis prophylaxis and occasional clinical follow-up are suggested. However, if the VSD has become smaller because of its closure by prolapsed aortic valve cusp into the defect with resultant aortic insufficiency, closure of the defect with resuspension of the aortic valve leaflets is recommended. The development of aortic insufficiency is seen in both membranous and supracristal VSDs.

In moderate-sized VSDs, congestive heart failure (CHF), if present, should be treated. In the presence of failure to thrive, markedly enlarged left atrium and LV or elevated pulmonary artery pressures (or both), closure of the defect is generally recommended. An additional criterion is a pulmonary-to-systemic flow ratio ($Q_p:Q_s$) greater than 2:1.

In large VSDs with systolic pressures in the RV and pulmonary artery close to left ventricular and aortic systolic pressures, closure should be undertaken. This should be done prior to 6 to 12 months of age (certainly no later than 18 months of age) irrespective of control of heart failure and adequacy of weight gain. The reason for this recommendation is to prevent irreversible PVOD. In babies with Down syndrome, such closure should be undertaken prior to six months of age since these patients tend to develop PVOD sooner than non-Down babies.

C. Devices for ventricular septal defect

I. Rashkind device

Rashkind double umbrella was the first device used for VSD closure. The device is a single-disk composed of polyurethane foam on a hexagonal stainless steel frame (Figure 18A) [87]. The device was initially designed for closure of patent ductus arteriosus (PDA) or atrial septal defect (ASD) [88]. In 1988, Lock et al [90] reported their attempt on transcatheter closure of VSD using a Rashkind device. At that time, Rashkind double umbrella was the only available device and was used to close various kinds of intracardiac defects [89]. The authors pioneered to close postinfarction VSDs and congenital VSDs with this device. They passed through the VSD via the left ventricle and advanced a guide wire to the right heart.

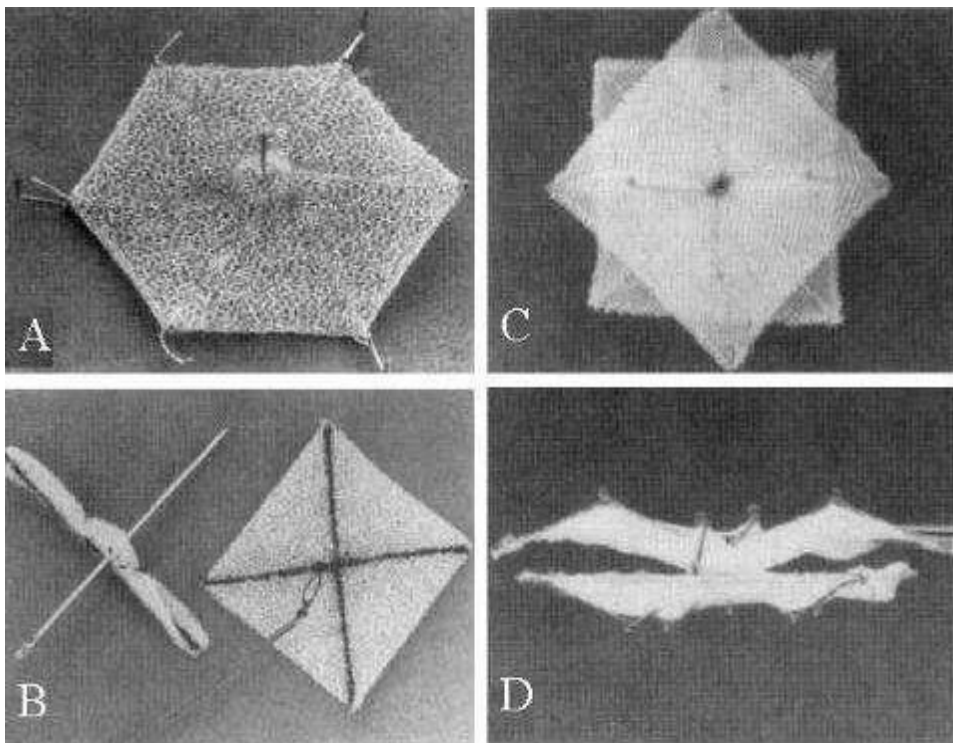


Figure.18 The devices used for transcatheter closure of ventricular septal defects. A, Rashkind double umbrella; B, Sideris Bottomed device; C and D, Clamshell device.

II. Amplatzer devices

The Amplatzer devices included septal occluder for ASD closure, duct occluder for PDA closure, PFO occluder for PFO closure and muscular VSD occluder (AVSDO) for VSD closure (Figure 19). They are made of Nitinol, an alloy of 55% nickel and 45% titanium that has superelastic properties [91]. It also has been proven to have excellent biocompatibility. Amplatzer septal occluder has a 4 mm waist and a relatively larger left atrial disc. The Amplatzer duct occluder is a mushroom shape device. Full description of these two devices was reported in previous literatures [92,93].

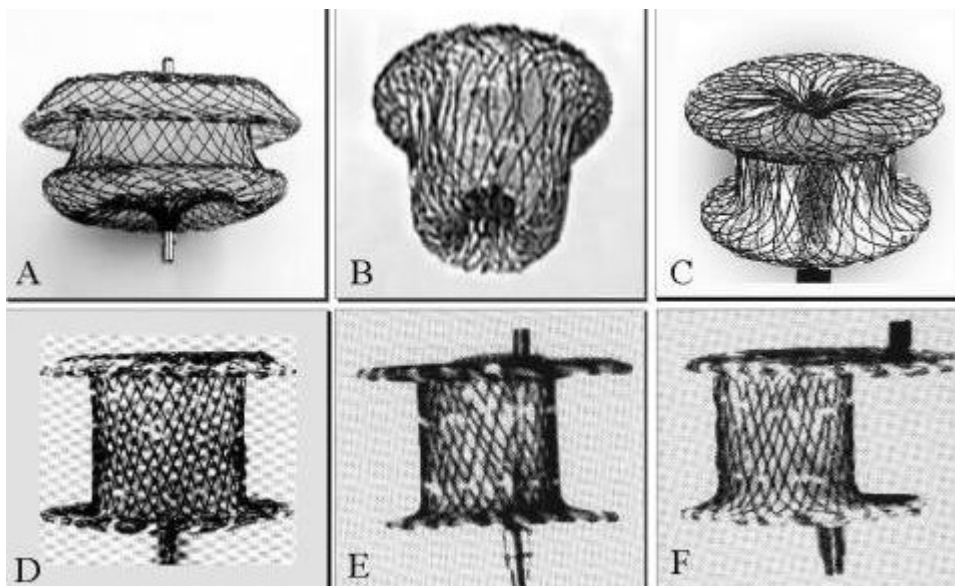


Figure.19 The Amplatzer â devices used for transcatheter closure of ventricular septal defects. **A**, Amplatzer septal occluder; **B**, Amplatzer PDA occluder; **C**, Amplatzer muscular VSD occluder; **D**, new concentric Amplatzer VSD occluder; **E** and **F**, new eccentric Amplatzer VSD occluders.

The AVSDO is also a double disc device. The thickness of the Nitinol wire is 0.004" for devices 10 mm and smaller and 0.005" for larger devices. The leading retention disc is 4–mm larger and the proximal disc is 3–mm larger than the diameter of the waist. To achieve immediate complete closure, three Dacron polyester patches are sewn securely with polyester thread into the two discs and the waist of the device. The device size corresponds to the diameter of the waist. The mechanism of closure involves stenting of the VSD by the device and subsequent thrombus formation within the device with eventual complete neoendothelialization.

The device is available in sizes from 6–24 mm now that are delivered through 6 to 9 French sheaths ([Table 2](#)). The delivery system is prepackaged with a long Mullins type sheath, loader, diaphragm with side arm flush, delivery cable and pin vise.

Table 2. Amplatzer® Muscular Ventricular Septal Occluder

Device Size (waist size)	Device Length	Recommend ed Sheath Size	Large Disc Diameter	Small Disc Diameter	Wire size
6 mm	7 mm	6-7 F	14 mm	12 mm	0.004 inch
8 mm	7 mm	6-7 F	16 mm	14 mm	0.004 inch
10 mm	7 mm	6-7 F	18 mm	16 mm	0.004 inch
12 mm	7 mm	7-8 F	20 mm	18 mm	0.005 inch
14 mm	7 mm	7-8 F	22 mm	20 mm	0.005 inch
16 mm	10 mm	7-8 F	24 mm	22 mm	0.005 inch
18 mm	10 mm	7-8 F	26 mm	24 mm	0.005 inch
20 mm	10 mm	8-9 F	28 mm	26 mm	0.005 inch
22 mm	10 mm	8-9 F	30 mm	28 mm	0.005 inch
24 mm	10 mm	8-9 F	32 mm	30 mm	0.005 inch

The additional advantages of AVSDO are that this device possesses some characteristics rendering it ideal for catheter closure of muscular VSDs in children. It has simple user-friendly delivery system, and requires small delivery sheaths. Therefore, the device can be delivered from the traditional venous route or from the retrograde arterial route. The device is available in many different sizes allowing the operators to close a wide range of defects located in the apical, posterior, anterior or mid-muscular portion of the ventricular septum. The last but the most important feature is the ability to reposition or recapture the device prior to release.

Thus AVSDO seems to be a very good device for transcatheter closure of muscular VSD.

III. Button device

Button device was first introduced by Sideris et al [94] in 1990. This device is composed of a square sheet of polyurethane foam supported by two independent, diagonally situated wire arms and a separate counter occluder ([Figure 18B](#)). The foam occluder can be easily folded into the delivery sheath, and resume its square shape when advanced out of the delivery catheter. The disadvantage of this device is the deployment procedure is complex with a 19%–21% failure rate for ASD closure. This device was initially designed for ASD closure, but it has also been used to occlude PDA. In 1997, Sideris reported their multi-center study of this device to close VSDs [95]. These authors deployed the device through right jugular vein for muscular VSD, and through femoral vein for perimembranous VSD.

IV. Bard Clamshell umbrella

There have been two reports on transcatheter closure of VSD using a Bard Clamshell umbrella [96, 97]. The device was initially designed for ASD closure [98]. It consisted of two opposing self-expanding umbrellas (Figure 18C, D). The device had been withdrawn from investigational studies in 1991 due to arm fracture and high incidence of residual shunt. The manufacturer (Nitinol Medical Technologies Inc, Boston, MA) redesigned the device and now it is called CardioSeal device. Clamshell umbrella had been used for closure of isolated muscular VSD, VSDs associated with other cardiac lesions or post surgery patch leak [96, 97]. Thus the efficacy of closure seems not satisfactory with this device.

Clamshell device is no longer used right now. There has been no report on its successor, CardioSeal, for VSD closure.

V. Gianturco coils

Gianturco coils were originally designed for closure of small to moderate size unwanted vascular communications [99]. Latiff et al used it to close multiple muscular VSDs in a 10-month old boy [100]. These authors successfully deployed 4 and 3 coils, respectively, for a 3.5-mm apical defect and 1.5–2.0 mm mid-muscular defect. A small residual shunt was found at 3-month follow-up with the patient's clinical picture improved significantly. Thus in special situation, Gianturco coils might be also used to close a muscular VSD.

D. DEVICE IMPLANTATION TECHNIQUE

The procedure is done under general endotracheal anesthesia. Access is obtained in the femoral vein, the femoral artery and the right internal jugular vein. The patients are fully heparinized with a target activated clotting time of > 200 seconds at the time of device placement. Routine right and left heart catheterization is performed to assess the degree of shunting and to evaluate the pulmonary vascular resistance. Axial angiography is performed to define the location, size and number of VSDs. For single VSD, the use of transesophageal echocardiographic (TEE) monitoring is optional [101]; however, for catheter closure of multiple muscular VSDs, TEE guidance should be routine. In very small children, TEE may not be well tolerated, transthoracic echocardiographic (TTE) monitoring may be used instead.

E. Percutaneous closure of Muscular VSD's

Amin reported the first use and description of the Amplatzer Muscular VSD occluder in a canine model in 1999. The device (Fig.20) was specifically designed for the muscular septum. It is a self-expandable double-disk device made from a 0.004–0.005 inch nitinol wire mesh with a polyester mesh inside to enhance thrombogenicity. Nitinol is a shape-memory alloy composed of nickel and titanium that is biocompatible and has super elastic properties. The waist of the device is 7 mm long corresponding to the thickness of the muscular septum. The right and left disks are 8 mm larger than this connecting waist. The Amplatzer muscular VSD device is available in sizes ranging from 4 to 16 mm in 2-mm increments. There is a microscrew on one end for attachment to the delivery cable. The device requires a 6–9 Fr sheath for delivery.




Fig.20: *The Amplatzer muscular VSD device shown in different profiles.*

For the procedure the femoral vein and artery are accessed routinely. If the VSD is located in mid, posterior or apical septum, the right internal jugular vein is also accessed. The patient is fully heparinized (100 U/kg) to achieve an activated clotting time greater than 200 seconds at the time of the device implantation. Routine right and left heart catheterization is performed to assess hemodynamics (pressures and pulmonary vascular resistance) and to measure the degree of left-to-right shunt. For single muscular VSD, the procedure can be safely performed without transesophageal echocardiography (TEE) guidance, however for multiple defects (Swiss cheese septum) continuous TEE monitoring and guidance is essential. A complete TEE study is performed including standard imaging views. Nearby structures to the VSD are specifically evaluated including papillary muscles, moderator band and the chordae tendinae. AV valves are interrogated at baseline for any regurgitation. Left ventricle angiography in single plane in the hepatoclavicular projection (350 LAO/350 cranial) for mid/apical/posterior defects is performed to define location, size and number of the defect(s). This projection is used to better profile the muscular septum. For anterior defects, the long axial oblique view is preferred. The appropriate device size is chosen to be 1–2 mm larger than the diameter of the defect as measured by color Doppler TEE or angiography (the bigger of the two diameters) at end diastole. Balloon sizing of muscular defects is not necessary.

Next step in the procedure is to cross the VSD. This is performed using a 4–

5 Fr Judkins right coronary catheter advanced from the LV via the defect into the RV. On occasions, the catheter itself may not cross the defect. In such cases, the catheter tip is orientated towards the defect and an angled tip, 0.035" Terumo glide wire is advanced through the defect to the right side. The catheter is then advanced over this wire to the pulmonary artery. The Terumo wire is removed and a 0.035" J-tipped exchange length guide wire is advanced to either branch pulmonary artery. This wire is snared using a goose-neck (ev3, Plymouth, MN) and exteriorized through the right internal jugular vein (mid, posterior or apical muscular defects) or the femoral vein (anterior defects). This provides a stable arteriovenous loop and allows a 6–8 French long Mullins type sheath to be advanced from the jugular or femoral vein and positioned into the LV apex. On occasions some large mid muscular or apical defects can be crossed from the RV side, however care must be exercised not to go through the trabeculae in the right ventricle. In this case, once a catheter is advanced into the LV an exchange length guide wire is advanced into the LV apex and a 6–8 French long Mullins type sheath is advanced over this wire and positioned into the body of the LV.

If kinking is noted on the distal part of the delivery sheath when removing the dilator and wire from it, a 0.018" Terumo glide-wire is advanced through the sheath and left inside the sheath during advancement of the device. Once the device reaches the tip of the sheath, this wire is removed. A pigtail catheter is positioned in the LV for angiography to guide device deployment. The LV disk is deployed in the middle of the LV. Then, the entire assembly (cable/sheath) is pulled towards the VSD with further retraction of the sheath to deploy the waist inside the septum. Confirming the position of the device with angiography and TEE is of paramount importance before deploying the RV disk. Once the position is confirmed, the RV disk is deployed by further retraction of the sheath. Again TEE and LV angiography are necessary to confirm the device position prior to its release from the cable. If the

position is satisfactory, the device is released by counter-clockwise rotation of the cable using the pin vise. The device orientation commonly changes slightly when it is released from the delivery cable and all the tension on the device is eliminated.

After the release a complete TEE evaluation is performed with additional imaging in multiple views to confirm device placement, to assess residual shunting and any obstruction or regurgitation that may have been induced by the device. Additional defects are then occluded in the same fashion. A last angiogram in the left ventricle is performed 10 minutes after the final device release to assess the result. Figures 21 & 22 demonstrate the closure steps of a muscular VSD by TEE and cine fluoroscopy respectively.

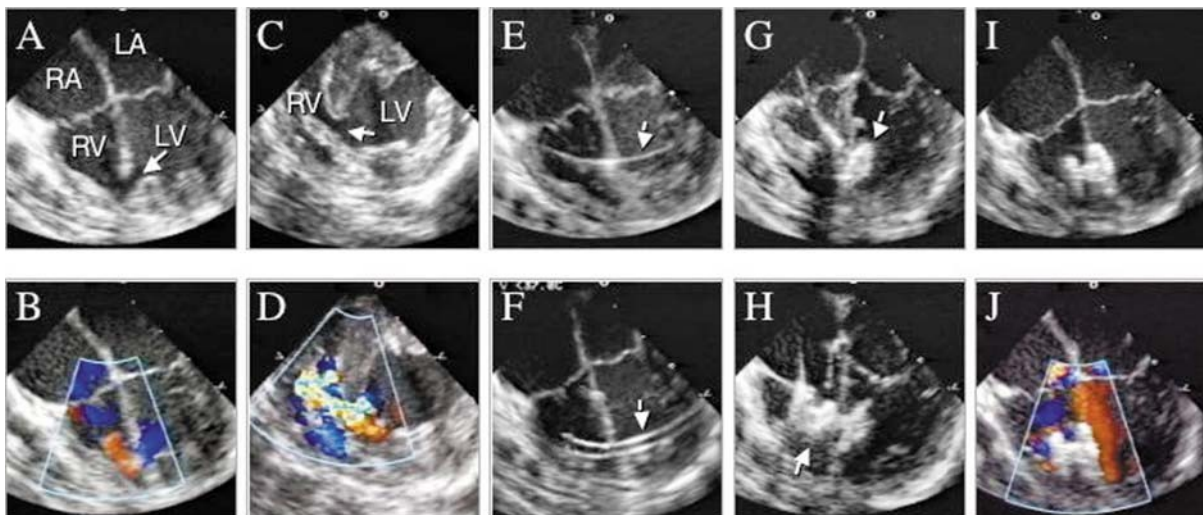


Fig. 21: TEE images of muscular ventricular septal defect closure with an Amplatzer muscular VSD device. A, Apical 4-chamber view of a muscular VSD; B: Color Doppler flow across the VSD; C: The muscular VSD in the short axis view; D: Color Doppler flow across the muscular VSD in the short axis view; E: Wire across the VSD; F: Sheath across the VSD; G: The left ventricular disc is deployed in the left ventricle; H: The right ventricular disc is deployed in the right ventricle; I: The device is released from the delivery cable; J: There is no residual shunt across the VSD by color Doppler. RA – Right atrium; RV – Right ventricle; LA – left atrium; LV – left ventricle.

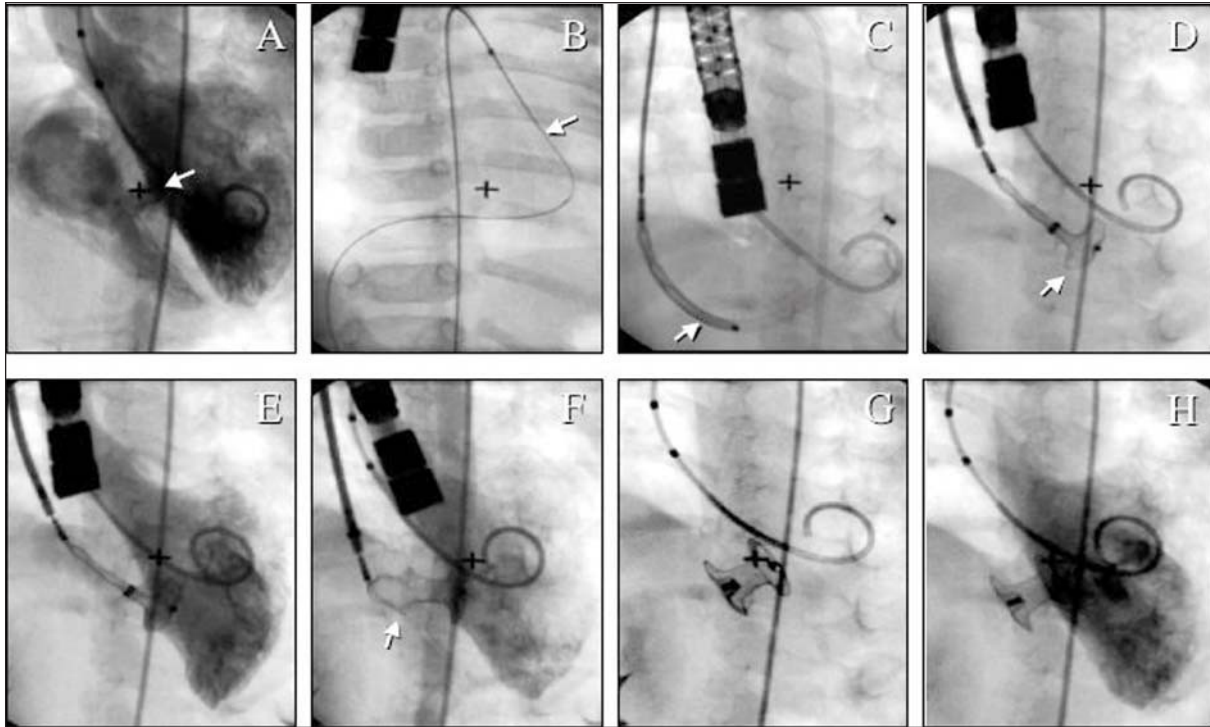


Fig. 22: Fluoroscopic and angiographic steps in the closure of a muscular VSD. A, LV angiogram demonstrates the presence of a single mid-muscular VSD; B. The wire is across the VSD from the left ventricle; C. The delivery sheath is in the left ventricle from the right internal jugular and the device is being advanced; D. The left sided disc is advanced into the left ventricle. E. LV angiogram to confirm the position of the left ventricular disc; F. The right disc is deployed in the right ventricle; G. The device is released from the delivery cable; H. LV angiogram shows complete closure of the muscular VSD with the Amplatzer muscular VSD device.

Patients receive a dose of an appropriate antibiotic, usually cafazolin (20 mg/kg) during the procedure and two additional doses at eight-hour intervals. The patients are recovered at an appropriate setting and are routinely discharged home the following day. Bacterial endocarditis prophylaxis is recommended for six months or until complete closure is obtained. Patients are instructed to avoid contact sports for one month. Follow up includes TTE with color Doppler, chest radiography and EKG at six months post-closure and yearly thereafter.

Several reports have demonstrated the feasibility and effectiveness of Amplatzer muscular VSD occluder for closure of congenital muscular VSD's[102–104]. The closure rate improves as time from closure to follow-up increases, from 58.7% at one month to 92.3% at 12 months. The remaining residual shunt is usually trivial or small. It has been possible to occlude multiple VSDs with a large device or multiple devices in one or repeated procedures^[105]. Rate for major complications is 10.7% including hypotension, arrhythmias and device embolization. Mortality associated with the procedure is 0–2.7%. It is possible to perform this procedure in patients under 5 kg, however, this is technically very difficult and require an experienced operator. Therefore, in such small patients, it is better to consider the perventricular approach.

Perventricular Closure of Muscular VSD's

The use of Amplatzer muscular VSD occluder to close muscular VSDs in patients with low weight (< 5 kg), poor vascular access or poor ventricular function, can be performed using the perventricular technique that permits implantation of the device in the hybrid suite, thus avoiding cardiopulmonary bypass with its sequel[106–108].

For this, the chest is opened through a regular median sternotomy, although a subxiphoid minimally invasive incision without full sternotomy has also been reported. Under continuous TEE guidance, the best location for RV puncture is chosen far enough from the septum so as to approach it from a perpendicular angle with the needle and wire. A 5-0 polypropylene purse-string suture is placed at the chosen location and an 18-G needle is introduced into the RV free wall and directed toward the defect to be closed. A 0.035-inch angled Terumo glide wire is passed through the needle and manipulated into the LV cavity through the defect. The needle is then removed keeping the wire in location. A 7F to 10F short (8–13cm) introducer sheath with a dilator is carefully advanced over the wire into the LV cavity. The dilator is removed and the sheath is de-aired. The appropriate device size is chosen to be 1 to 2mm larger than the VSD size as assessed by color Doppler TEE. The device is then screwed to the cable and pulled inside a 6–9 Fr short sheath or loader. We advocate presoaking the device in non-heparinized blood for 10 minutes to allow the tiny fenestrations of the nitinol mesh to thrombose. The device is then advanced inside the short delivery sheath until it is seen by TEE to be close to the tip of the delivery sheath. The LV disk is deployed in mid-LV cavity by gentle retraction of the sheath over the cable. The entire assembly (cable/sheath) is withdrawn gently until the LV disk is against the septum. Further retraction of the sheath over the cable deploys the waist inside the septum.

Continuous TEE to confirm the device position is again of paramount importance. Once the position is confirmed, further retraction of the sheath to expand the RV disk is performed. If device position is satisfactory, the device is released by counterclockwise rotation of the cable using the pin vise. A complete TEE study in multiple views is performed to confirm the device placement, assess for residual shunting, and any obstruction or regurgitation induced by the device. If the device is relatively large for a small RV (usually near the apex) and or the RV disk

does not expand properly, the device can be recaptured and exchanged for a smaller one or the Amplatzer duct occluder is used instead. On rare occasions, the microscrew of the device may extend through the purse string site, in such cases pledgeted sutures can be used to secure the device in position.

The results with this technique are still limited but encouraging^[107,108]. The largest published series is a multi-center study that included 13 patients in which only two patients had a mild residual shunt during the follow up and no one had echocardiographic or clinical evidence of significant congestive heart failure, volume overload, or pulmonary hypertension. Complications during the procedure have not been serious including transitory ventricular arrhythmias induced by the wire and sheath manipulation during the deployment, RV disk malposition and impingement on the tricuspid subvalvar apparatus. No mortality has been reported related to the procedure.

F. Percutaneous Closure of Perimembranous/membranous VSD

The Amplatzer membranous VSD device (Fig.23) has been previously described^[109]. It consists of an asymmetric self-expandable double-disk device made from a 0.003–0.005 nitinol wire mesh with a waist that is 1.5mm long. The aortic end of the left ventricle disk is 0.5mm larger than the waist and the other end is 5.5mm larger than the waist. The right ventricle disk is 2mm larger at both sides. There is a platinum marker positioned in the left ventricle disk. The screw in the device has a flat part that should be aligned on the flat part of the capsule located at the end of the pusher catheter. By doing so, the device almost always exits the delivery sheath in the correct orientation. The device is currently available in sizes ranging from 4–18mm in 2mm increment and a 6 to 9 French delivery sheath is required for the deployment.




Fig.23: Amplatzer Membranous VSD device. Legends: A– Delivery sheath; B–Pusher cable; C –Metal capsule of pusher cable; D–Delivery cable; 1 to 5 is the right sided disc; 2 is the waist; 3 to 4 is the left sided disc with a platinum marker at 3.

The procedure can be performed under general endotracheal anesthesia with continuous TEE guidance or under local anesthesia with either intracardiac echocardiographic (ICE) or TTE guidance. The vascular access is obtained from the femoral vein and artery. The VSD is crossed from the LV side using a 4 or 5 French Judkins right coronary catheter. A 0.035” Terumo glide wire is used to cross the defect and then it is advanced into the pulmonary arteries or superior vena cava. Then the catheter is advanced over the wire into either branch pulmonary artery or superior vena cava; the wire is removed and exchanged by a noodle wire (AGA Medical Corp., Golden Valley, MN), which is advanced to the tip of the catheter. Then the noodle wire is snared using a gooseneck snare catheter and exteriorized out through the femoral vein. This provides a stable arteriovenous loop. Over this wire, the proper size delivery sheath is advanced from the femoral vein all the way until the tip of the sheath reaches the ascending aorta. Slowly the dilator is pulled back to the inferior vena cava–right atrial junction and with the aid of the Judkins catheter positioned in the ascending aorta with the wire inside the tip of the sheath is pushed

into the left ventricular apex. It may take some maneuvering to achieve this position. Once the tip of the sheath is in the apex of the LV, the dilator and wire are totally removed. A hand injection angiogram using the delivery sheath will confirm its position and more importantly will delineate the location of the VSD. On rare occasions, more than one fenestration can be documented using this angiogram that were not well seen in the baseline angiogram. The proper-size device is screwed into the delivery cable. The flat part of the microscrew is aligned with the flat part of the capsule located at the end of the pusher catheter. Once the device is loaded, the pin vise is securely tightened to the cable at the end of the hub of the pusher catheter. This is done to prevent the premature disengagement of the two flat parts that will aid in the correct orientation of the LV disk. The left ventricle disk is deployed between the anterior mitral valve leaflet and the left ventricle outflow tract. Echocardiography (TEE/TTE/ICE) is essential to make sure that the mitral valve apparatus is not entangled with the left ventricle disk. The entire assembly is withdrawn back to the septum. This can be seen by echocardiography and confirmed by angiography with a pigtail catheter in the left ventricle. The waist of the device is then deployed. Aligning the left ventricle disk so that the aortic end of the disk is toward the aortic valve is of paramount importance. If the device was properly screwed (flat parts aligned) and the sheath was advanced to the apex of the left ventricle, almost always the flat part of the left ventricle disk is adequately deployed toward the aorta. In addition to this, the platinum marker located in the left ventricle disk should be orientated toward the patient's feet. If so, this indicates proper device position. The right ventricle disk can be deployed after an angiogram to ensure good device position. Echocardiography and repeated angiogram can confirm proper device position prior to disengagement of the two flat parts. For this, the pin vise is loosened and the pusher catheter is withdrawn

over the cable. The final step is the release of the device by counter-clockwise rotation of the pin vise. Once the device is released, the cable and the pusher catheter should be brought inside the sheath immediately to prevent any injury from the sharp end of the cable. Repeat echocardiography and an angiogram are performed to assess the final result (closure and residual shunt, assess the function of the tricuspid and aortic valves). As mentioned above, the use of ICE has been reported as an alternative to TEE in guiding the procedure^[110]. Fig. 24 & 25 demonstrate the steps of closure of a perimembranous VSD using TEE and cine fluoroscopy respectively.

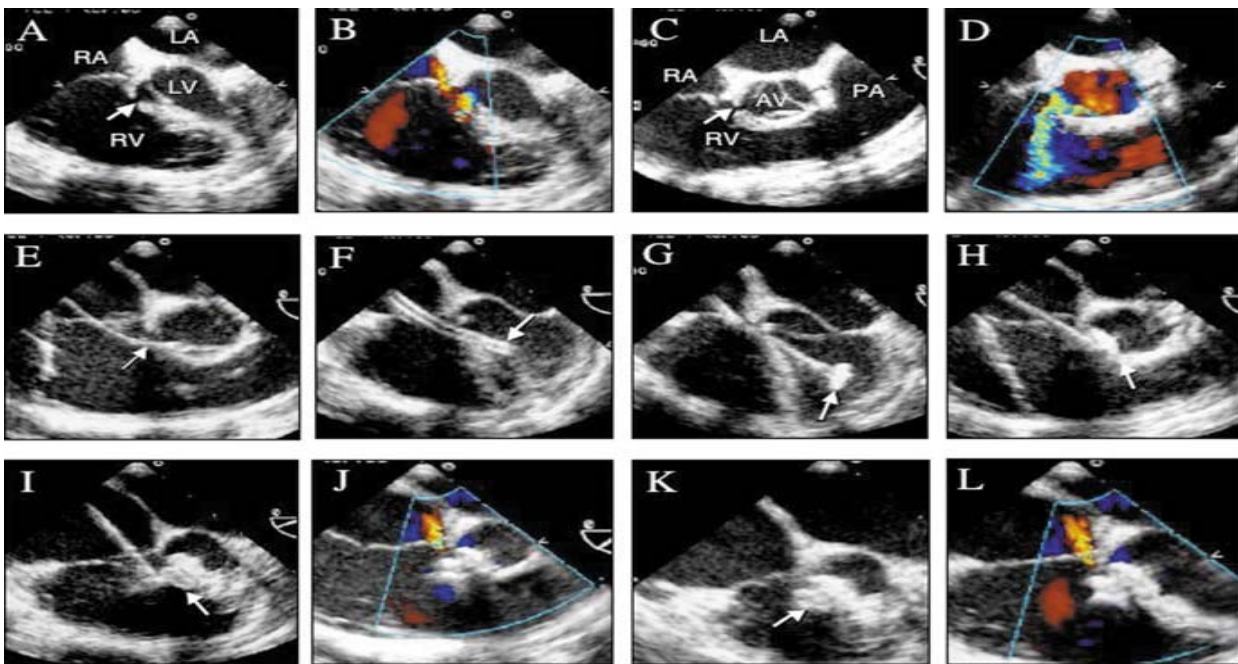


Fig. 24: TEE images of perimembranous VSD closure with an Amplatzer Membranous VSD device. A–D. 2–D and color images of a perimembranous VSD; E. Wire across the perimembranous VSD; F. Sheath through the perimembranous VSD; G–I. Steps of device deployment; J–L. The device is released with no residual shunt. RA – Right atrium; RV – Right ventricle; LA – left atrium; LV – left ventricle.

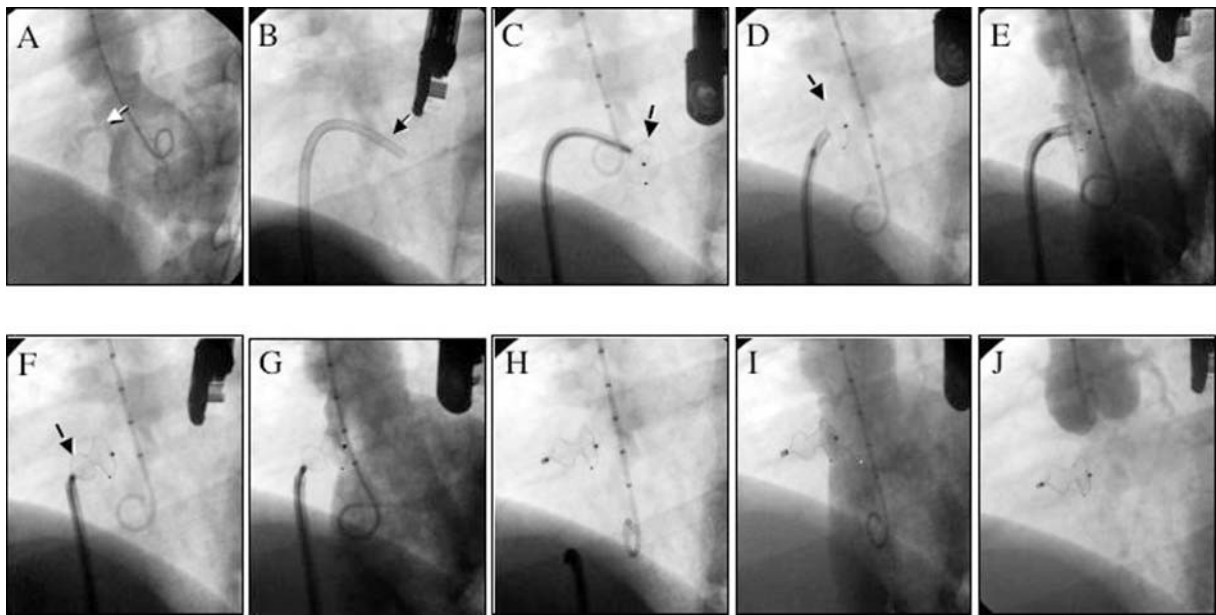


Fig.25: A. LV angiogram demonstrating the perimembranous VSD; B–G. Steps of device deployment; H–I. Release of the device with LV angiogram showing no residual shunt; J. Aortogram with no aortic insufficiency.

Early clinical results with the Amplatzer Membranous VSD occluder have been very encouraging^[111,112]. Closure rates after the procedure have been reported around 90%, and this number increases during the following months to 98–100% due to thrombosis of the polyester material inside the device and to the endothelialization process. No mortality has been reported related to the procedure. Serious complication rate is low (8.6%) corresponding to occasional cases of complete AV block and aortic insufficiency. The heart block issue (around 2–3%) has been the major reason for the reluctance of interventionalists to use this device. Currently, the manufacturer of the device (AGA Medical Corp.) is in the process of redesigning the device. The redesign entails softening the device by decreasing the thickness of the wire. Obviously, only good clinical trials (registries or randomized trials) will answer the question of safety and effectiveness of device closure of perimembranous VSD.

A periventricular approach to close perimembranous VSD has been reported in an animal model demonstrating that this technique could be possible for small patients with poor vascular access and avoiding CPB effects^[113]. Another report in an animal model demonstrated that the periventricular approach to close perimembranous defects could be possible with a robotically assisted technique, thus avoiding the traditional sternotomy incision^[114]. However this remains preliminary and we will have to wait further clinical application.

G. Complications

Despite the technical differences during closure of muscular or membranous VSDs and the differences in the design of the devices, the procedures share the same spectrum of complications.

I. Device embolization

this occurrence is rare if the procedure is performed by an experienced operator and under strict echocardiographic guidance (2.7%)^[115]. The devices can migrate to the left or right ventricles and be subsequently embolized to the ascending aorta or pulmonary artery. The device can be snared and retrieved percutaneously, however larger sheaths will be needed. An experienced operator in snaring techniques is required as well the availability of all types and sizes of snaring systems. The presence of a congenital cardiac surgeon in house is essential for VSD device closure program to be initiated at any institution.

II. Arrhythmias

bradycardia and ventricular arrhythmias can be encountered during the catheter manipulation and the device deployment, particularly in post-infarction patients. They are usually transient but it is essential to have the presence of a congenital cardiac anesthesiologist who can manage all types of rhythm disturbances. Complete AV block after muscular VSD closure has been infrequently observed (1.9%) and is usually transient^[115,116]. Empirical treatment with high-dose intravenous steroids and high-dose oral anti-inflammatory aspirin has resulted in resolution of the heart block after device closure of perimembranous VSD^[117].

III. Air embolism

meticulous techniques of catheter and wire exchanges can minimize this complication.

IV. Hemolysis

this is a rare complication usually associated with residual shunt. We have found that pre-soaking the device with the non-heparinized patient's own blood is effective in reducing residual shunt and achieving complete closure. If hemolysis is to occur, medical management is advised by well hydration and alkalinization of the urine. Usually, this will disappear within few days. If hemolysis is severe and the patient requires multiple blood transfusions, we recommend device removal.

V. Valvular regurgitation

Tricuspid, mitral and aortic valve regurgitation may occur due to impingement of the device or part of it on the tricuspid/mitral subvalvar apparatus or if the device is too close to the aortic valve leaflets. Therefore TEE assessment of the

tricuspid/mitral and aortic valves prior to closure and prior to release of the device is extremely important.

VI. Pericardial effusion

this is a very rare complication that may result from catheter irritation or minute wire perforation during the procedure. TTE after 24 hr is essential prior to the discharge of the patient from the hospital. Tamponade is usually due to frank perforation. There have not been reports of delayed pericardial effusion related to Amplatzer VSD device occluder.

Coarctation of the aorta

A. Introduction

Coarctation of the aorta is a narrowing of the aortic lumen, usually of the thoracic descending aorta in the region just distal to the left subclavian artery. Although there are many variants of the anatomic position and length of the narrowing and associated lesions, such as a bicuspid aortic valve, hypoplastic transverse aortic arch, and aberrancies of the head vessels.

Coarctation of the aorta (Coa) is a congenital cardiac anomaly accounting for 4% to 7% of all congenital heart disease (Chd).[118,119] Most are diagnosed as neonates and infants and undergo corrective surgery as an accepted standard of practice. However, many cases are unrecognized until late childhood or adulthood. Transcatheter therapy in the form of balloon angioplasty was introduced in the 1980s as an alternative approach to treat recurrent coarctation following surgical therapy,[120,121] but both treatment strategies had major drawbacks, including recoarctation, residual hypertension, aortic wall injury causing dissection, and aneurysm formation.[122,123] To overcome some of these limitations, intravascular balloon-expandable stent therapy was introduced in the 1990s.[124,125] The bare metal stents, by providing a rigid endovascular prosthesis, maintained improved vessel diameter compared to balloon angioplasty of the coarctation segment. By providing a scaffold for the weakened aortic wall, many believe that stent placement would decrease the likelihood of aneurysm formation.[126] Over the past decade, use of intravascular stent therapy for native and recurrent Coa has become widely accepted for older children and adults.[118,126,127]

B. INDICATIONS FOR TREATMENT

Coarctation of the aorta, native or recurrent, is diagnosed[128–130] when the following are present:

- There is a difference in systolic blood pressure of 20 mm Hg between the upper and lower limbs.

- There are echocardiographic findings of coarctation, including 2-D imaging of narrowing in the descending aorta, a Doppler gradient with turbulence of color Doppler and persistence of the gradient into diastole, and an abnormal Doppler tracing with damping of the signal in the abdominal descending aorta.
- Hemodynamic evaluation demonstrates a peak-to-peak pressure gradient greater than 20 mm Hg.
- Imaging (aortography, CT, or MRI) demonstrates a significant narrowing in the descending thoracic aorta.

Although it is generally accepted that coarctation should be treated when a pressure gradient greater than 20 mm Hg is recorded, it has been suggested that milder obstructions and gradients may benefit from stent implantation by decreasing left ventricular diastolic pressure and preserving systolic and diastolic left ventricular function in the long term. [131,132] Mild obstructions should be relieved when associated with hypertension at rest, abnormal blood pressure response during exercise, progressive left ventricular hypertrophy, and in cases of complex heart disease, in particular Fontan palliations. The pressure gradient may be less than 20 mm Hg when a large collateral circulation is present or ventricular function is depressed.

Stenting reduces the gradient at the coarctation site more effectively than balloon dilation,[133–135] and, therefore, the authors consider this technique in all patients in whom vascular access appropriate for the required delivery system is available. Exception is made in small children due to the need for repeated reinterventions to match somatic growth. The authors routinely stent patients with coarctation and who weigh more than 20 kg.

Covered stent implantation is indicated in patients with coarctation[136,137]:

- Associated with aneurysm or degenerative changes of the aortic wall suggested by the presence of an aneurysmal ascending aorta or significant aortic tortuosity
- Associated with a PDA
- Critical or atretic obstructions
- Aortitis, Turner syndrome, Williams syndrome
- Aortic wall injury (aneurysm, dissection, or rupture) after balloon dilation, bare stent implantation, or surgery
- Presence of circumferential fractures within a previously implanted stent in the aorta with malalignment or protrusion of the stent struts into the aortic wall on repeat angiography, MRI, or CT

Due to improvements in balloon and stent technologies, which afford lower profile systems and the encouraging results from recent reports, the authors now use covered stents as the first choice for treatment of coarctation of the aorta in suitable patients.

C. Treatment of Coarctation

In 1944, Dr. Clarence Crafoord and Dr. Robert Gross performed the first successful surgical repair of coarctation of the aorta. During the ensuing four decades, surgery remained the only treatment for coarctation. In the late 1970s, percutaneous balloon angioplasty was described as an alternative to surgical repair [138]. Since then, transcatheter interventions have become increasingly popular and in many cases have emerged as the treatment of choice [139, 140].

D. Percutaneous Options and Mechanism of Action

Transcatheter options now include simple balloon angioplasty, angioplasty followed by stenting, primary stenting using bare or covered stents, and rescue stenting with a covered stent. The mechanism of relief involves stretching and tearing of the vessel wall.

By simple balloon angioplasty, the minimum a balloon will do is stretch the target lesion; however, this may be followed by early and late recoil of the lesion, making this technique less satisfactory. A sustained result of balloon dilation typically involves a tear of the intima and partially the media while keeping the adventitia intact; such a therapeutic tear should be contained to the narrowed zone [141–143]. In order to obtain a sustained result, some degree of overdilation with the balloon is frequently required. After dilation, some mechanisms will limit or improve the long-term result: recoil and retraction of nongrowing scar tissue will result in recurrence of the narrowing or stenosis, but catch-up growth and remodeling may occur by release of the stenotic ring and enhanced anterograde flow. However, such tears may predispose to possible complications. These include dissection, false aneurysm, and rupture [144]. A *dissection* is a tear that extends beyond the coarcted segment in the axial dimension, permitting contrast to track extraluminally in a proximal or distal direction. The false lumen of such dissection may be progressive and cause distal tearing of the vessel wall or even occlusion of side vessels. A *false aneurysm* may result from a defect in the aortic wall, with contrast extravasation beyond the adventitial plane with a discrete length; such a false aneurysm may “grow” over time and eventually rupture. An *aortic rupture* is a frank disruption of the aortic wall, which appears angiographically as extravasation of contrast beyond the confines of the aorta into the mediastinum or pleural space. A relatively high incidence of aneurysm formation of between 2 % and 20 % has been reported after balloon dilation [145, 146]. Several techniques

have been described to improve the hemodynamic result and reducing the risk for these complications: these involve low-pressure balloon dilation and interrogation of the stenosed site, progressive and/or stepwise dilation with noncompliant balloons in one or more sessions, and limiting the size of the balloon based on the narrowing itself or adjacent segments.

Since 1989, bare metal stents have been used to treat narrowing in the aorta [147,148]. Stents will overcome many of the shortcomings of simple balloon dilation. A stent will expand and scaffold the target region, thereby avoiding recoil and residual or recurrent stenosis. A good result can be obtained by simple stretching of the wall without a tear as there is no need for overdilation. Stenting may therefore result in lower vessel wall complications: fewer aneurysms, no dissections within the stent as they are automatically contained by sealing the intimal flap, and less rupture. Where intimal tears occur, the stent provides a surface for formation of neointima over the tear and reinforces the weakened areas within the aortic wall reducing the risk of a false aneurysm. However, stent implantation has some shortcomings: the technique is technically more demanding and requires a bigger sheath causing more vascular trauma at sheath insertion point, the foreign metal may induce interactions with surrounding tissues such as coagulation, wall hyperplasia, sharp edges of the stents may protrude and damage the vessel, the stents alter local vascular compliance and impede vessel growth, and stents may fracture and collapse [149]. Overall, the use of bare stents has improved results while lowering the complication rate of vessel wall trauma to 1-5 % [150].

Initially, stent implantation was used only for cases where surgery and balloon angioplasty had failed. However, as experience increased, stenting gradually became the treatment of choice in selected patients with aortic coarctation [151]. This is especially the case when coarctation coexists with hypoplasia of the isthmus or

transverse arch, or when balloon dilation has a high failure rate such as in a tortuous coarctation, a long segment coarctation, or mild discrete coarctation. Stents are particularly helpful in some postsurgical patients [152] where a non-resorbable wire was used: balloon dilation alone may only tear the intima from the vessel with possible major dissection before breaking the wire. In adult patients, stenting is now considered as the treatment of choice in any variant of aortic coarctation. At the other end of the scale, in children less than 10 years of age, it is preferable to avoid stenting, as several redilations may be required until the child is fully grown.

The availability of covered stents has further reduced the incidence of aneurysm formation and vessel rupture to less than 1 % as the covering will seal any tear in the vessel wall [153]. Covered stents can also exclude an unwanted passage to vessels such as an arterial duct or an existing aneurysm [154–156] and allow creating a new vessel segment as in aortic arch atresia [157]. Covered stents typically will require a larger sheath of more than 1 F than the size needed for bare stents, may cover origins of side vessels, may cause flow obstruction if incompletely opened or partially collapsed, and if they migrate to an unwanted location, may be more hazardous than bare stents. Currently, the discussion is still open as to whether covered stents should be used as a routine or only in case of a complication or specific indication. In countries where covered stents are available, there is a clear shift towards more routine use of covered stents in order to reduce the early and late complication rates [158]. Having covered stents available in the catheter laboratory adds to the safety of any aortic procedure: bleeding due to excessive vessel damage can usually be controlled with a covered stent as bail-out procedure.

E. Equipment

I. Balloons for Angioplasty

Many balloons are currently available for angioplasty of the aorta. The differences between balloons include availability in different sizes and lengths; tapering of balloons (the shorter the better, as the nose of the balloon may cause unwanted lesions in the arch); compliance; profile which determines sheath size for vessel entry; mode of refolding, which determines sheath size for removal of the balloon and the extent of damage at distal point of sheath; nominal pressure; burst pressure; inflation and deflation time; resistance to puncturing (stent or calcium); mode of rupture such as a point, longitudinal, and transverse; coating of balloon and shaft properties, and stretchability on retrieval. It is not uncommon to have different types of balloons available on the shelf at all times.

II. Balloons for Stent Delivery

Many balloons are available for stenting of the aorta. Although the same balloon as the ones used for angioplasty may be used, each technique will determine different ideal requirements of the balloon. For stent delivery, additional features such as the balloon size, material, surface, and mode of inflation are important. A shorter balloon will avoid excessive shoulders on inflation which may cause flaring of stent and puncture of the balloon and will enhance stability of the balloon during inflation with reduced inflation time, and less hemodynamic effects, but may make slipping of the stent off the balloon more likely. The balloon material should be non-slippery and puncture resistant, especially when used with stents with “sharp” edges of the crimped stent; sufficient lumen should remain to allow symmetric inflation of the balloon as asymmetric inflation may result in “milking-off” the stent from the balloon during expansion. Several balloons are

currently available from different manufacturers: Powerflex® and Opta Pro® (Cordis, USA), Z-Med® and BIB® (NuMED, USA), Cristal® (Balt, France), and many others.

In the early days, all stents were hand-crimped on single large diameter balloons for expansion and delivery within the coarctation. Large diameter single-balloon catheters tend to expand first at their ends and thereby evert the stent ends such that they protrude radially into the vessel wall, which predisposes to aneurysm or dissection at the edges of the stent. An important development of equipment for delivery of large diameter stents has been the Balloon-in-Balloon (BIB®) catheter (NuMED, USA). These catheters have a small inner balloon and a 1 cm longer outer balloon that is twice the diameter of the inner balloon. The BIB catheters offer the important advantage of opening the stent more uniformly along its length. They do, however, require a larger arterial sheath for introduction: the profile of BIB catheters with outer balloon diameters of 8–14 mm is 9 Fr, of 16 mm is 10 Fr, of 18–20 mm is 11 Fr, and of 24 mm is 12 Fr sheath. Thus, while BIB catheters prevent stent flaring, cause less stent foreshortening, allow repositioning after inflation of the inner balloon, and offer more precise control over stent placement without danger of “milking-off” the stent during inflation, single-balloon catheters are preferable in smaller patients to reduce the risk of injury to the femoral artery at the access site. In order to keep the sheath size as small as possible in smaller children, a single low-profile balloon may be used to deliver the stent and anchor it across the lesion and then further dilate the stent with another noncompliant high-pressure balloon.

III. Stents

Many stents are available for stenting the aorta. Differences between the stents include crimpability with low profile, distensibility, the pressure required to open and deploy the stent, conformability over the full length, foreshortening and

radial strength at different diameters, flaring at the ends, open or closed cell design which determines longitudinal grip and side branch accessibility, sharpness of the edges and the wire within the stent, collapse resistance, wire fracture resistance by metal fatigue or intentional by balloon dilation, membrane covering, radiolucency, and MR compatibility. Less important stent features for aortic application are flexibility and cell area which determines tissue prolapse through the cells. The following balloon dilatable stents are available to treat congenital lesions in different parts of the world: Palmaz® XL 10-series and Genesis® XD (Johnson & Johnson, USA), AndraStent® XL and XXL (Andramed, Germany), IntraStent® LD Mega and Max (ev3, USA), and the Cheatham-Platinum® (CP) stent (NuMED, USA). The Valeo® stent (Bard, USA) and Mounted CP stent® (NuMED, USA) are premounted, the latter within a sheath. Covered stents are available as the Covered CP® (CCP stent) or the Covered Mounted CP® stent (NuMED, USA), the V12 Advanta® stent (Atrium, USA), or can be handmade [29] Figure 26 .




Figure.26 Images of the four most commonly used stents for treatment of coarctation of the aorta worldwide. CP: Cheatham-Platinum, which is available in the United States only under the COAST protocol.

Occasionally, self-expanding stents may be used, but these have a limited role in pediatric cardiology practice when treating narrowed segments. Such stent grafts typically require 22–24 Fr sheaths and are used to treat true aneurysms in adults.

Crimpability of the stent to a low profile determines the minimum sheath size, but this is inversely related to its distensibility, foreshortening, radial strength, and fracture resistance.

The Genesis and the premounted Valeo stent have a low profile of 6 Fr when mounted on a balloon up to 10 mm, and can be dilated up to 18–22 mm, however, with significant foreshortening (>60 %) and fracture rate. Most other stents will require a minimal sheath size of 9–10 Fr, depending on the type of balloon used. The size of an adult aorta varies between 16 and 20 (and may be up to 22 mm), and so sheath size may be up to 14 Fr. In very premature infants, coronary stents can be introduced through a 4 Fr sheath and can eventually be dilated up to 5 mm and so currently these need subsequent surgical removal. The pressure required to open and deploy the stent and the sharpness of the stent wire will determine the required thickness and pressure resistance of the balloon, which determines the profile of the balloon and thus the final profile for insertion. Some conformability is desirable to allow the stent to conform to the curvature of the arch to reduce the likelihood of stent damaging the vessel wall. When partly covering the origin of a head and neck vessel, flaring the end of the stent into the side vessel may be desirable, especially when using a covered stent. Stents may have an open or closed cell design, which determines the maximal size of opening to a neck vessel.

A stent ending with a stiff thin circular wire will offer more grip, but this is not required in the aorta as the stent is usually well fixed by the stenosis, but the wire may cause more vessel damage, both at placement and at redilation, resulting in dissection or aneurysm formation at the ends of the stent.

IV. Guidewires

Most operators use a long stiff 0.03500 guidewire with a soft tip. The guidewire may be positioned in the ascending aorta or the left ventricle; but in order to avoid damage to the left ventricular apex, the aortic valve or a coronary artery, the tip of the guidewire should be curled. Positioning the guidewire in the right subclavian artery may offer more stability during stent deployment, but with some risk of dissection of the brachiocephalic trunk [30]. The left subclavian artery is rarely used due to insufficient space for balloon inflation.

V. Sheaths

Hand-crimped balloon mounted stents should be delivered through a long sheath, keeping the stent covered until positioned across the stenosis. There are several appropriate types of sheath, the most popular being the straight Cook RB-Mullins design sheath (COOK, Denmark), which has a competent hemostatic valve, a radiopaque tip, and a side arm, allowing hand contrast injections during stent positioning. Some covering or a short, cutoff piece of sheath tubing placed over the stent is usually required to pass the stent safely through the valve.

➤ Inflation: Speed by Hand or by Indeflator

Early in everyone's experience, it was felt that the balloon should be inflated as fast as possible to keep the hemodynamic burden on the heart as short as possible. However, this has often resulted in asymmetric expansion and migration of the stent during inflation. Most operators now recommend slow balloon inflation initially, allowing both shoulders of the balloon to rise around the stent, preventing the stent from being "milked" off the balloon. Once in satisfactory position, further balloon inflation may be much faster. The use of a BIB balloon has nearly abolished the risk for asymmetric stent opening and stent dislodgement.

The balloon can be inflated by hand, allowing the operator to continuously observe the stent and the coarctation site, and thus control the dilation, when opening the stent inside the lesion and stretching and tearing the stenotic region. The operator should know by experience the level of pressure that can be achieved with different syringes, keeping in mind that the larger the syringe size, the lower the maximal pressure that can be achieved by manual inflation. For example, a 10 cc syringe typically will allow 6–10 atm pressure to be achieved while a 20 cc syringe allows pressure of 4–6 atm. An inflator device may help achieve better control of the pressure, but ideally one operator should focus on the manometer while another operator focuses on the stent expansion. Most lesions will open with inflation pressures below 6 atm, but when higher pressures are required, an inflator is necessary.

➤ **Stability of Stent**

Adequate stability of the stent on positioning depends on the delivery ensemble such as stiff guidewire, stiff balloon shaft, and long stiff introducer sheath placed just below the balloon. Guidewire position may influence stability such as ascending aorta versus subclavian artery position of the guidewire. Often rapid right ventricular pacing at a rate of 180–240 bpm is used. Rapid pacing may be of importance in adults with a high stroke volume and in particular in the presence of aortic regurgitation, or when deploying a stent in the transverse aortic arch closer to the heart. In exceptional cases, additional stability can be achieved by snaring and externalizing the distal end of the guidewire from the right radial or brachial artery to form a stable circuit for stent deployment.

F. Catheterization Procedure

the procedure is most commonly performed under general anesthesia using the retrograde transfemoral approach. administration of antibiotic prophylaxis and intravenous heparin at 75 to 100 mg/kg to maintain an activated clotting time of > 250 ms throughout the procedure is recommended. all patients should undergo a complete right- and left-heart catheterization. the coarctation segment is most commonly crossed using an angled catheter. once peak-to-peak systolic pressures have been obtained across the coarctation segment, a detailed angiogram using either a pigtail or multitrack catheter is performed. the new dyna computed tomography (Ct)/rotational angiography imaging capabilities, when available, offer important additional imaging details of the aortic arch. details of the entire transverse aortic arch, including brachiocephalic vessel location, isthmus, coarctation segment, and the aortic dimension at the level of the diaphragm, are essential. final stent diameter is based on proximal arch diameter (transverse or distal arch), with the diameter not exceeding the size of aorta at the level of the diaphragm. furthermore, the ratio of stent diameter to preintervention narrowest coarctation segment should be < 3.5 . in taking a page from our adult colleagues, one cannot overemphasize the importance of achieving adequate vascular access and postprocedural hemostasis. during vascular access, we ensure that we enter the femoral artery at the level of the femoral head. immediately upon entry with the arterial sheath, an angiogram is taken to ensure adequate vessel size and appropriate sheath entry site within the vessel. at that time we preclose with the perclose a-t device (abbott vascular device, abbott park, il). a perfect example of how we avoided possible vessel injury is depicted in figure 27 with a recent patient who required covered stent placement for both reobstruction and an aneurysm of her previously repaired coarctation segment.

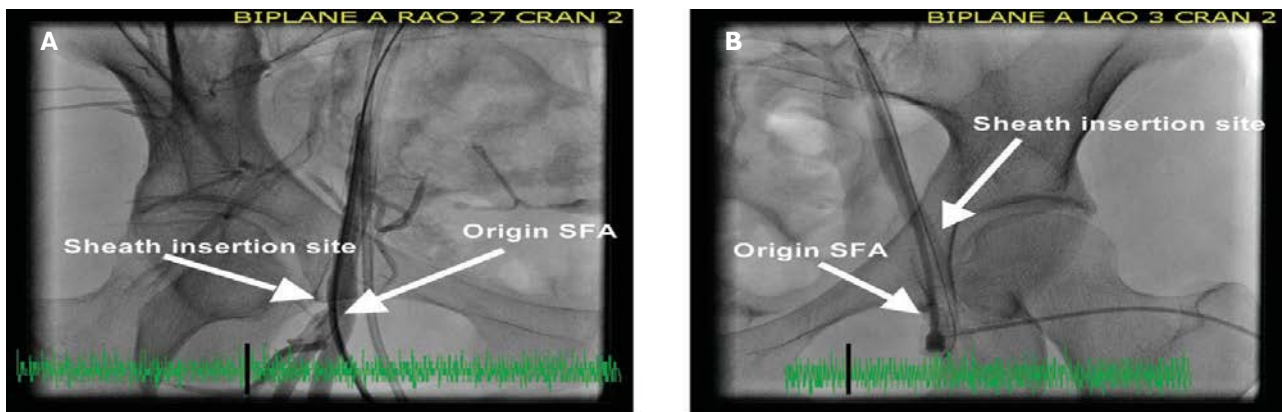


Figure. 27 Importance of imaging the femoral artery before upsizing sheaths.

(A) Note the very small distance between the origin of the SFA and the sheath entry site into the femoral artery (< 5 mm). (B) In the contralateral femoral arterial vessel in the same patient, the sheath entry is superior to the figure on the left (12 mm superior to the origin of the left SFA), thereby allowing the use of a Preclose device and less likely to cause SFA injury when upsizing the sheath for stent placement. SFA: superficial femoral artery.

to provide a stable track to advance and deploy the balloon/stent segment, a rosen wire (Cook Medical, Bloomington, in) or exchange-length amplatzer extra- or super-stiff (st. Jude Medical, st. paul, Mn) wire is positioned in the ascending aorta or right subclavian artery. the stent is hand-crimped on the balloon catheter, with the extremely low profile balloons requiring inflation to 0.6 atm to allow for adequate stent/balloon traction, thereby preventing stent slippage during advancement through the long sheath. from the CCisC consortium, the balloon-in-balloon is by far the preferred delivery balloon when initial stent dilation is ≥ 18 mm as it provides controlled stent expansion, the ability to adjust stent position following inner balloon expansion, and decreased stent foreshortening (figure 28).

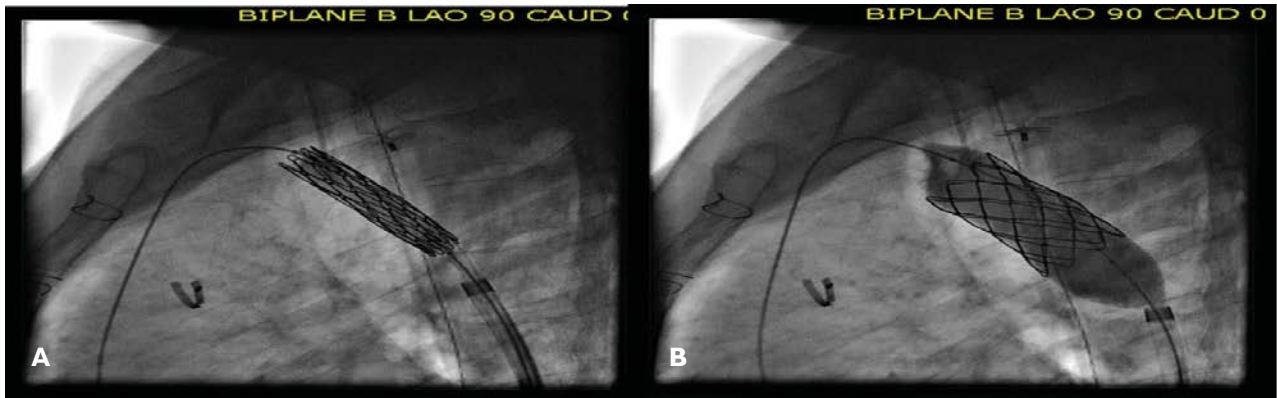


Figure. 28 Use of the balloon-in-balloon catheter for placement of a covered stent across a coarctation aneurysm. The inner balloon is approximately one-half the size of the larger outer diameter balloon. In this particular patient, (A) the inner balloon is inflated to 10 mm, allowing for final stent positioning, before the outer balloon (B) is inflated to 20 mm.

for stents that are initially deployed on ≤ 16 mm balloon catheters, the z-Med ii™ balloon catheters (nuMed inc., hopkinton, ny) are the most widely used. for optimal stent positioning, we cover the proximal balloon with the delivery sheath and slowly expand the distal stent to its full size. We then pull the sheath off of the balloon catheter and deploy the remainder of the stent across the coarctation segment (figure 29). for optimal stent delivery and to prevent stent malposition and migration, right ventricular pacing may be performed. though this is rarely necessary for standard moderate-to-severe coarctations, this technique is essential for stent treatment of transverse aortic arch narrowing and patients with mild coarctation of the aorta. following stent deployment, either a pigtail or multitrack catheter is used to obtain simultaneous pressure measurements across the stent. Multiple angiograms (or rotational angiography) is performed after stent placement. stent implantation is considered successful if a gradient < 10 mm hg and improvement in vessel caliber $> 80\%$ of the normal adjacent aortic arch is achieved. the majority of patients continue their antihypertensive medications and are restricted from contact sports for 1 month after the procedure. they are also placed on antiplatelet medication and are to follow endocarditis precautions for 6 months after stent placement.

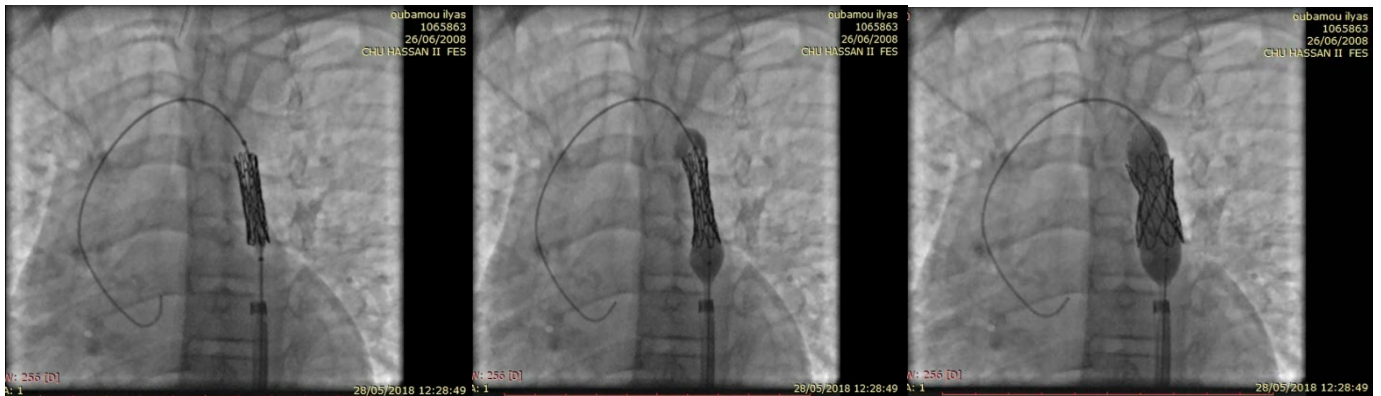


Figure.29 Deployment technique for stents mounted on a single (non-BIB) balloon catheter. (A) The sheath is still covering the proximal balloon/stent catheter. (B) The catheter is gradually inflated, dilating the distal balloon/stent apparatus to its full size. (C) Final inflation of the balloon/stent apparatus is done with the sheath fully withdrawn off of the balloon catheter. This technique allows for controlled and precise stent positioning across the coarctation site. BIB: balloon-in-balloon.

G. Technique of Balloon Angioplasty

The procedure is performed under general anesthesia or heavy sedation as stretching or tearing the aorta is extremely painful for the patient. Vascular access is obtained via the femoral artery. An aortogram is performed with maximal elongation and profiling of the aortic arch. Initially, the plane of the aortic arch is determined. With the catheter in the ascending aorta, the frontal camera is placed in RAO projection until perfect alignment of the ascending and descending arch is obtained. Subsequently, the lateral camera is rotated in LAO projection at exactly 90° to the RAO camera. From this angle, the aortogram will be perpendicular with maximal elongation of the arch. Angiography can be performed using a pigtail catheter with 1 cm radiopaque markers, allowing accurate calibration and exact measurements of the aorta. Alternatively, a Multi-Track® catheter (NuMED, USA) advanced over a 0.03500 exchange guidewire can be used. This catheter has a 1 cm marker for accurate calibration and a monorail system allowing pullback gradients to be measured across the coarctation without losing guidewire position. The measurements of the aorta include systolic diameters of the distal transverse arch just proximal to the origin of the left subclavian artery, the aortic isthmus just distal to the origin of the left subclavian artery, the site of the coarctation, and the descending aorta above the diaphragm.

Different protocols have been reported to select the appropriate balloon size for safe dilation of the coarctation. Balloon size is limited by the neighboring segments such as the transverse aortic arch, the proximal isthmus, or the thoracic aorta at the diaphragm level and/or by the coarcted segment itself. The balloon should be no more than 300 % of the minimal diameter, provided this is well visualized by the aortogram. A low-pressure inflation is recommended to interrogate the compliance and narrowing of the vessel. If the stenosis was

underestimated, a smaller balloon may be preferred for initial dilation. Progressive dilation can be performed, each time preceded by measurement of the residual gradient and a repeat aortogram to assess the result (Fig. 30). Not surprisingly, a bigger balloon will yield a better gradient relief, but may increase the complication rate.

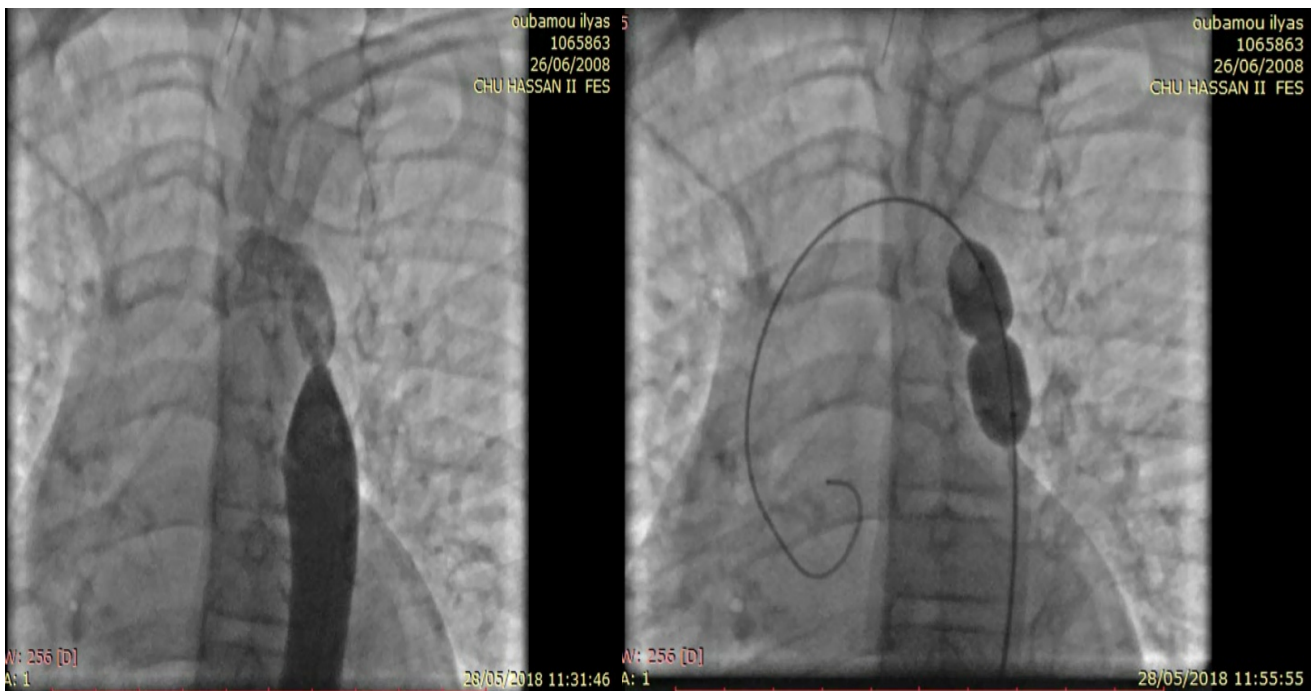


Fig. 30 Balloon dilation of native aortic coarctation (a) Aortogram in the descending aorta shows narrow discrete coarctation. (b) Through a 5 F sheath, balloon dilation shown with an 8 mm balloon.

For a patient younger than 1 year of age, balloon angioplasty is frequently only palliative as the rate of recoarctation has been reported to be more than 50 %. For a patient older than 1 year of age, balloon angioplasty has reasonable immediate results, but the rates of recoarctation are still about 26 % .

Late false aneurysms have been reported in 1.5 % of cases after balloon dilation of a postsurgical coarctation , whereas they seem to occur more frequently (8–35 %) in patients with a native coarctation. The lower incidence of aneurysms in postsurgical coarctation patients may be due to the fact that the aorta is surrounded by postoperative fibrosis and that most of the abnormal aortic wall tissue is removed at the time of surgery.

H. Technique of Stenting

The procedure is similar to balloon dilation in many aspects (Fig. 31). In the presence of a very tight or nearly atretic aortic segment, access may be needed via the right or left radial or brachial artery, allowing a catheter or guidewire to be passed from above through the coarctation site into the descending aorta. Rarely, transcardiac or a carotid arterial access via a surgical arteriotomy may be required. Heparin at a dose of 100 IU/kg is given after access is obtained; the activated clotting time is maintained above 220–250 s throughout the procedure, particularly due to the risk of long clots developing in the long introducer sheath. A Perclose (Abbott Vascular) suture can be inserted at this stage for rapid and lasting hemostasis at the end of the procedure. However, in adolescents and young adults, good hemostasis can be achieved by prolonged manual compression under anesthesia even after removing a 14 Fr sheath. A 5 or 6 Fr end-hole catheter is passed through the aortic coarctation and positioned in the ascending aorta.

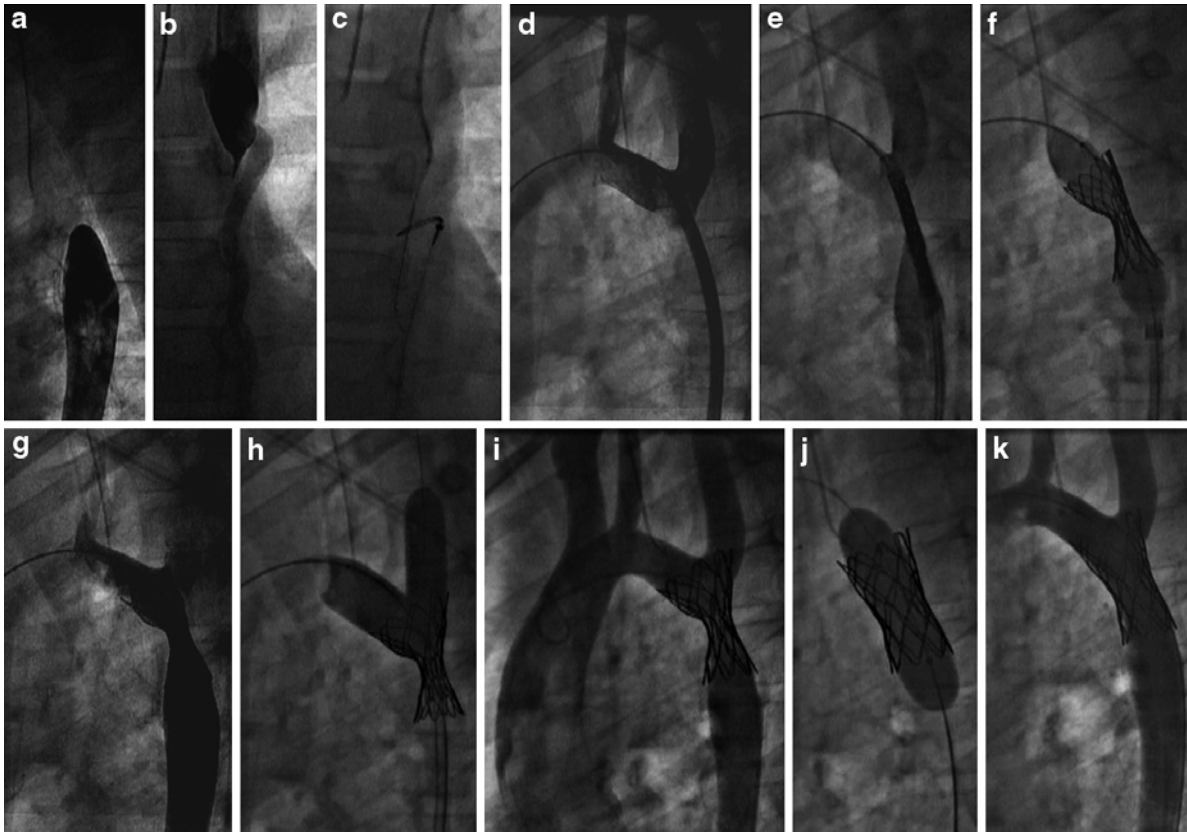


Fig.31 Stenting of near atresia of the aortic arch. Ten- year-old boy with near atresia of the aorta: (a) Aortogram showing no retrograde flow. (b) Aortogram in distal isthmus showing tiny passage of contrast to thoracic aorta. (c) Snaring of 0.014⁰⁰ coronary wire. (d) After arterio-arterial circuit was made, retrograde passage of 11 F sheath and hand injection of contrast through the sheath. (e) 34 mm CCP stent in position on 14 mm BIB balloon. The large origin of left subclavian artery is partly covered but remains accessible after deployment of the stent. (f) Hand inflation of balloon with subtotal opening of stent sufficient for stent anchoring. (g) Flaring of upper end of stent with 10 and 14 mm balloon to open passage to the left subclavian artery and appose the stent maximally to the wall. (h) Stent nicely apposed to the vessel wall, thereby sealing the zone of expected vessel tear at the end of first procedure. (i) After 2 months, dilation with 12 mm high- pressure balloon at 10 atm. (j) Final result with no residual gradient and excellent patency of stent.

In a tight or tortuous coarctation, it is preferable to cross the lesion with a straight tipped guidewire from below. Adequate angiography and accurate measurements are even more important than for simple balloon dilation. Small errors may lead to selection of a wrong balloon size and stent and therefore increase the complication rate significantly. The length of the stent is based on the length of the hypoplastic segment, typically from the left subclavian artery or the left common carotid artery depending on previous surgical technique and/or site of coarctation to about 15 mm beyond the site of the coarctation.

To reduce the small risk of vascular complications with bare stents, it is reasonable to test the compliance of the coarctation lesion. A balloon of similar size or even bigger than the intended stent is inflated at low pressure. This maneuver is intended as a diagnostic measure, not as an angioplasty prior to stent placement. If there is a significant residual waist on the balloon, a slightly smaller balloon is chosen for stenting and complete expansion of the stent is postponed until a second catheterization 2-6 months later. However, a test interrogation of the coarctation site is usually not indicated if a covered stent is used.

The maximum balloon diameter on which the stent is mounted is based on either the transverse or the distal arch diameter, whichever is the larger, and on occasions 1-2 mm larger. A long Mullins sheath is passed over the 0.03500 stiff exchange guidewire. The sheath size ranges between 10 and 14 Fr and is generally 2-3 Fr larger than that required for introduction of the balloon catheter alone. The stent is manually crimped tight on to the selected balloon, so as to ensure that it does not slip off the balloon. To facilitate introduction of the stent/balloon assembly through the diaphragm of the sheath, to prevent the stent from slipping off the balloon, and to protect the covering of the stent from being removed inadvertently, a cutoff short sheath tubing of similar size and sufficient length or a dedicated introducer is placed over the stent. The stent/balloon assembly is

advanced through the long sheath and positioned across the site of the coarctation. Optimal positioning is confirmed by small hand injections of contrast through the side arm of the Mullins sheath. Alternatively, injections can be made through a second catheter placed in the transverse aortic arch.

While maintaining the balloon catheter and guidewire position, the Mullins sheath is withdrawn to expose the stent/balloon assembly in position at the site of the coarctation. Keeping the sheath just below the balloon will enhance the stability during inflation. Care must be taken to withdraw the sheath sufficiently below the balloon to allow the balloon inflation in an unstrained manner. Failure to do so may cause the balloon/stent assembly to move during inflation, or milk the stent off the balloon because of asymmetric inflation. Rapid right ventricular pacing is used if desired. The balloon is initially inflated slowly to allow the shoulders of the balloon to distend and to immobilize the stent on the balloon, and then faster inflation is performed until the stent is anchored at the stenosis site with both ends of the stent widely open and the stenosis sufficiently relieved, or the maximal balloon pressure reached. Once the stent is deployed, the balloon is deflated and pacing is stopped. If a BIB balloon is used, the inner balloon is inflated first, followed by the outer balloon, and for fast deflation, both balloons can be deflated simultaneously. A bare stent can be expanded to the diameter of the normal vessel at either side of the coarctation; however, in case of a tight coarctation, an undersized balloon should be chosen or the balloon not fully expanded in order to reduce the likelihood of aortic wall damage. After deflation, the balloon is withdrawn carefully so as not to dislodge the stent. The gradient across the stent is then measured and an aortogram is repeated to exclude dissection or aneurysm formation.

Further dilation with a larger balloon is performed in some cases until satisfactory relief of the stenotic waist is obtained. Flaring of the ends of a bare stent to achieve contact with the aortic wall at all points is not usually performed. In

contrast, flaring of the ends of a covered stent allows adhesion and sealing of the wall, which will prevent a tear from creating an aneurysm or extravasation of contrast. In complex lesions in small patients, it is not uncommon to use one low-profile balloon to deliver a stent across a stenosis through a small sheath, another larger balloon to flare and appose the ends of the covered stent to the wall to obtain maximal sealing, and one or more high-pressure noncompliant balloons to progressively dilate the stenotic region.

Patients are usually discharged the day after the procedure and reevaluated clinically and echocardiographically 4 weeks, 6 months, and 1 year after the procedure. Spiral CT scanning is performed 4–6 weeks after the intervention to exclude aneurysm formation, dissection, and stent thrombosis.

I. Complications

Some complications of coarctation stenting have already been discussed. In general, they can be classified into technical, aortic wall or peripheral vascular complications, or post-procedural hypertension and pain.

I. Technical complications

include stent migration on the balloon in the sheath, during deployment on the balloon, migration after deployment, stent fracture, balloon rupture, and covering of the brachiocephalic vessels. While passing the stent/balloon assembly through the valve or the sheath, the stent may migrate off the balloon; radiopaque markers on the balloon allow confirmation of correct position of the stent on the balloon before withdrawal of the sheath to uncover the stent in the aorta. If the stent has moved, the stent-balloon sheath can be removed leaving the guidewire in place, remove the stent from the front of the sheath and start the procedure again.

- **Stent migration** off the balloon during inflation can occur if the balloon is inflated asymmetrically. This can be avoided by minimal inflation of the balloon before introduction through the sheath, creating small shoulders on both sides of the stent. This is relatively easily done with an indeflator. During stent deployment, balloon inflation should be started slowly, allowing both shoulders of the balloon to expand, thereby immobilizing the stent on the balloon. Stent migration can be avoided further by using a BIB balloon, especially when using the bigger sized balloons of >15 mm, the inner balloon is typically within the stent and cannot milk the stent off the balloon and the outer balloon will inflate symmetrically after the inner balloon has been inflated. During or after deployment, the stent may migrate more proximally or distally. Often the stent can be recaptured with a balloon and repositioned. If it cannot be repositioned safely within the coarctation, it should be expanded in the safest location available, away from side branches if possible.
- **Balloon rupture** may be avoided by using an appropriate balloon for a given stent. Stents with sharp edges require thicker, puncture-resistant

balloons. Balloon rupture occurred in 13/588 (2.2 %) of cases in the CCISC cohort predominantly when using older stents such as the now-abandoned Palmaz 8-series stents. Balloon rupture may result in other complications involving the aortic wall, or embolization of balloon fragments, and if the balloon ruptures prior to full expansion, it will carry a high risk of stent migration.

- **Brachiocephalic vessels** constitutes a complication is debatable. There have been no demonstrated harmful sequelae from doing so, except at redilation.
- **stent fracture** may occur at the transition of the mobile segment of the aortic arch to the fixed retropleural thoracic aorta. Currently, stent fractures may occur in stents with thinner metal, e.g., Genesis and Valeo stents, when expanded to larger diameters.

II. Aortic wall complications

at or around the site of the coarctation include intimal tears, dissection, aneurysm formation, and rupture either within the stent or at the edges or at a distance. Vascular complications are more prone to develop in patients with connective tissue disease such as Turner syndrome. Most of these complications can be treated, or are better avoided, by using covered stents. The general rule of "it is easier to stay out of trouble than get out of trouble" certainly applies to these situations.

It is important to have large diameter covered stents available for use in emergency situations as the covered CP stent can be dilated up to 24 mm and Atrium stent up to 20–22 mm, but for some emergencies, larger self-expanding excluder stent grafts (from Boston Scientific, Gore, Medtronic) should be available.

Aortic aneurysm is infrequently encountered, but it may be a harbinger of aortic rupture and is therefore a potentially dangerous complication. It may be seen at the time of the procedure or on follow-up. If a large or growing aneurysm occurs at the time of the stent placement, it must be excluded with a covered stent to prevent progression and possible rupture .

III. Peripheral vascular complications

include cerebrovascular accidents, peripheral emboli, and injury to access vessels. Neurologic events including cerebrovascular accidents occurred in the CCISC group in 6/588 procedures. Adequate anticoagulation during the procedure is essential as the head and neck vessels are crossed with wires for a prolonged time and long sheaths are used where clots may form. Horner syndrome was reported due to a carotid artery dissection by the guidewire .

VI. Post-procedural rebound hypertension

is sometimes observed in adult patients immediately after the procedure. Patients with systolic blood pressures greater than 99th centile for age should be monitored carefully, and infusions of nitroprusside or esmolol or both should be used, if there is severe rebound hypertension. These patients can generally be switched to oral antihypertensive medications within 24 h after the procedure.

IV. Thoracic pain and abdominal discomfort

can occur early after the procedure. This pain may only become evident when the analgesics from the anesthesia fade away. Thoracic pain remains an alarming symptom, so dissection, aneurysm formation, bleeding from the aorta, or torn intercostal arteries must be excluded by observing peripheral pulses and assessing by echocardiography and CT scan. Such pain is most likely due to

stretching of the aorta and requires adequate analgesia in the form of opiates and is usually relieved after some hours. Some adult patients may complain of abdominal discomfort early after the procedure because better pulsatile flow may cause bowel irritability within the first few hours after the intervention.

PATIENTS AND METHODS

I. Patients and Inclusion / Exclusion criteria

this retrospective study carried out in the cardio-pediatric medical-surgical unit, pediatric ward, CHU Hassan II Fès, between June 2015 and November 2019.

This study investigates 127 patients who have undergone interventional catheterization for percutaneous closure of intracardiac shunts and dilated coarctations of the aorta with or without stents.

Patients were diagnosed with intracardiac shunts and aortic coarctations based on evaluation with a physical examination, CXR and transthoracic

Echo/Doppler study were planned to undergo cardiac catheterization to close the intracardiac shunt by transcatheter blocking device and dilation of coarctations of the aorta with stent or not.

All procedures was performed according to a standard technique by single operator (Pr Samir Atmani). ADO I and ASD prosthesis was used in our series represented by Amplatzer and Occluder devise.

All Procedure are performed during a short stay in hospital, prophylactic antibiotics are administrated.

General exclusion criteria include:

Any cases with Incomplete useful information.

Patient with pelvic vein or inferior vena cava thrombosis, sepsis (local and generalized), any type of serious infection less than one month prior to procedure, and demonstrated intracardiac thrombi on echocardiography.

2. The parameters studied

1. Study of epidemiological data

- a. age
- b. sex
- c. weight

d. Personal history

2. Diagnosis

2.1. clinic

- a. functional signs
- b. physical examination

2.2. Radiography

- a. chest X-rays data
- b. transthoracic Echo/Doppler data

3. Treatment, Evolution and Post-operative care

The devices used in our series are represented by:

- ADO I : amplatzer and occlutech 3,5/5 to 12-14.
- ASD occluder : amplatzer and occlutech.
- ADO 2 : Amplatzer.
- VSD device: amplatzer.
- CP stent and BIB Balloon.

3. Difficulties of the study

Like any retrospective study, the major difficulties we encountered were related to the study of records. Some records are incomplete; in these cases it was based on the register of echocardiography to complete the missing data on clinical information and evolution.

RESULTS

I. PATENT DUCTUS ARTERIOSUS

1. Study of epidemiological data

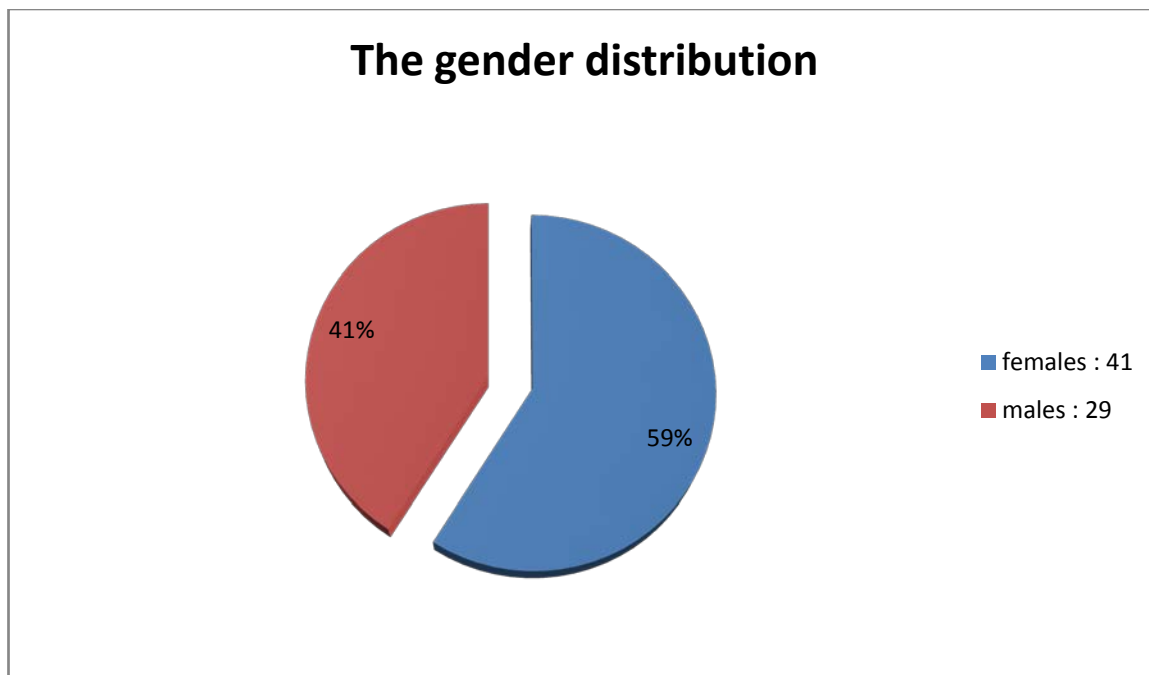
a. Age distribution

We analyzed the medical records of 70 patients , The patients were aged between 1 month and 16 years (mean age 5.4 year)

b. Gender distribution

Of the patients, 41 (59%) were females and 29 (41%) were males, sex ratio M /

F 0.70 distribution



c. Distribution by weight

The patients were weighed between 4 kg and 53 kg. and their mean weight was 17 kg.

d. Genetic syndromes

thirteen patients had Down syndrome

e. Intracardiac disease and PDA

Patent ductus arteriosus presented as an isolated lesion in 62(89%) patients. PDA-associated heart lesions were as follows: 4 cases of interventricular communication, 3 cases of pulmonary stenosis, 1 case of interatrial communication.

f. Etiological factors

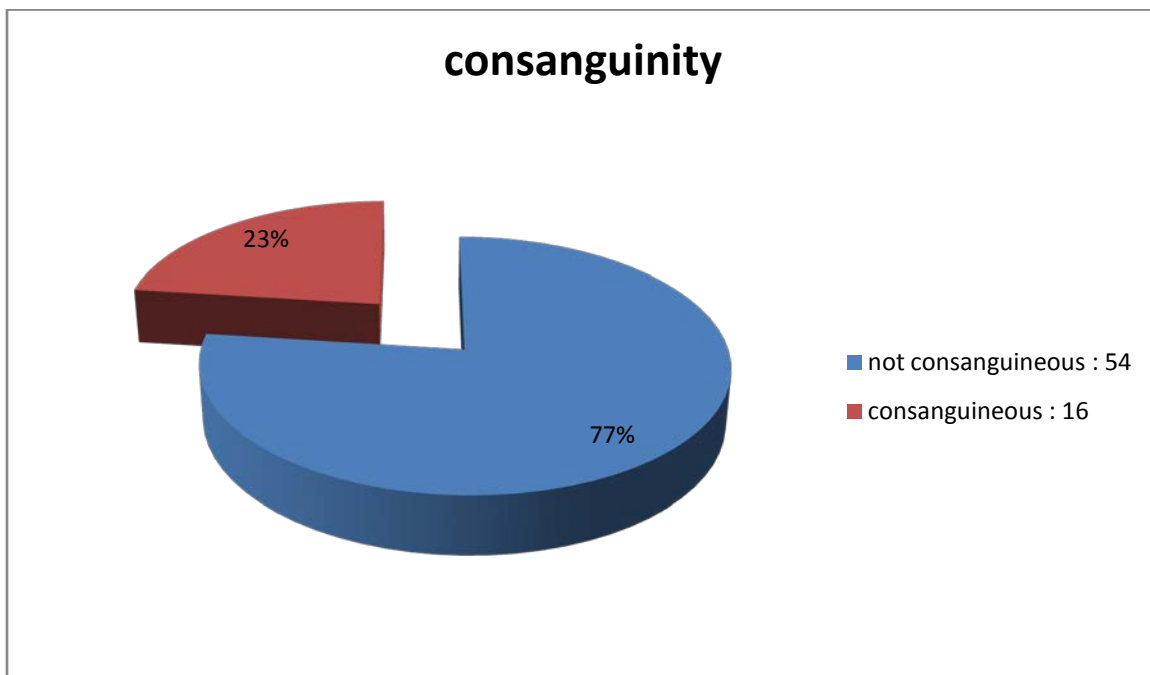
Consanguinity

The notion of parental consanguinity is noted in 16 patients or 23% of cases.

Of these:

ten cases have inbreeding 1st degree.

six cases have a second degree of consanguinity.



Personal history

Table 3: Pathological Personal history

Personal history	Number of cases
Down syndrome (Trisomy 21)	13
rheumatic fever	2
SGA at birth (Small for gestational age)	2
congenital rubella syndrome	1
Hypothyroidism	1
atresia of the bile duct	1
atresia of the esophagus (VACTERL)	1
thoracic deformity	1
posterior urethral valve	1
occipital meningoencephalocele	1

2.Diagnosis

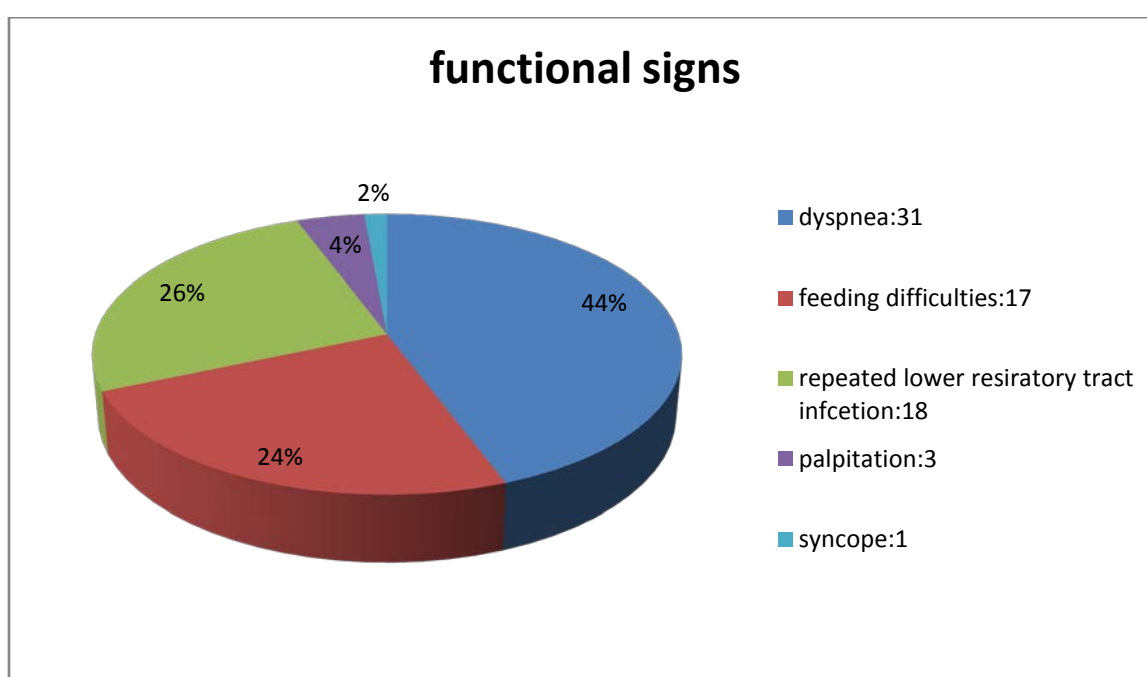
2.1. clinic

2.1.1. functional signs

The clinical symptoms in reported cases in our study are very variable, dominated by dyspnea, feeding difficulties, and repeated lower respiratory tract infections.

Table 4: Distribution of cases according to functional signs

Functional sign	Number of cases	Percentage
dyspnea	31	44%
feeding difficulty	17	24%
repeated lower respiratory tract infections	18	26%
palpitation	3	4%
Syncope	1	2%



2.1.2 cardiovascular examination

a. Pulse Examination:

The pulse is present and symmetrical in 70 patients; representing 100% of the cases have been studied.

b. Blood pressure:

No patient of our cases has a pressure gradient between upper and lower extremities.

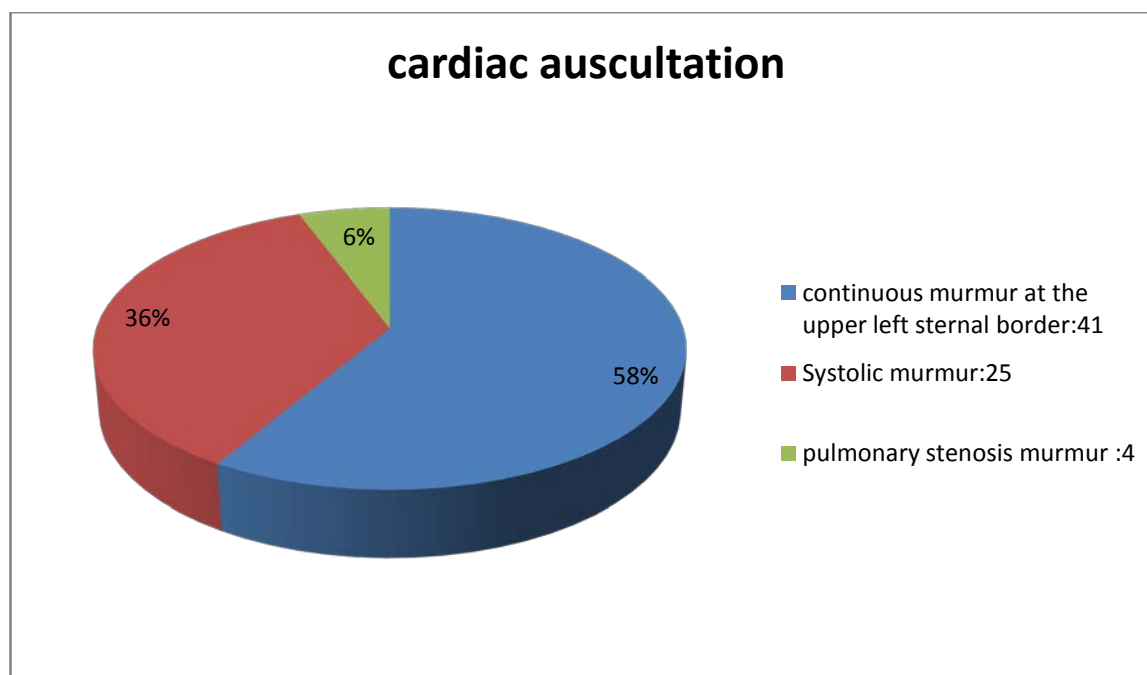
c. Cardiac auscultation:

A heart murmur was found in 70 cases, representing 100% of the cases have been studied.

The data of auscultation are reported in the following table:

Table 5: Result of cardiac auscultation

Result of cardiac auscultation	Number of cases	Percentage
continuous murmur at the upper left sternal border	41	58%
Systolic murmur	25	36%
pulmonary stenosis murmur	4	6%



d. Signs of heart failure

No one of our patients has signs of heart failure.

e. The arterial oxygen saturation

The arterial oxygen saturation in ambient air has varied between 91 % and 100%.

2.2. Radiography

2.2.1. Chest X-rays

a. cardiothoracic ratio (CTR)

The CTR in our series ranged between 0.4 and 0.57.

Cardiomegaly was found in 12 patients, or 17% of the cases have been studied.

b. The pulmonary vasculature

The analysis of chest radiographs of patients noted in our series:

A pulmonary hypervascularity in 36 cases.

A normal pulmonary vascularity in 34 cases.

c. Left mid-cardiac border

In our series, left mid-cardiac border is straight in 11 cases.

It is convex in 4 cases, and normal in 55 cases

2.2.2. Transthoracic Echo/Doppler

All patients included in our study benefited from ETT, it was used to study the following parameters:

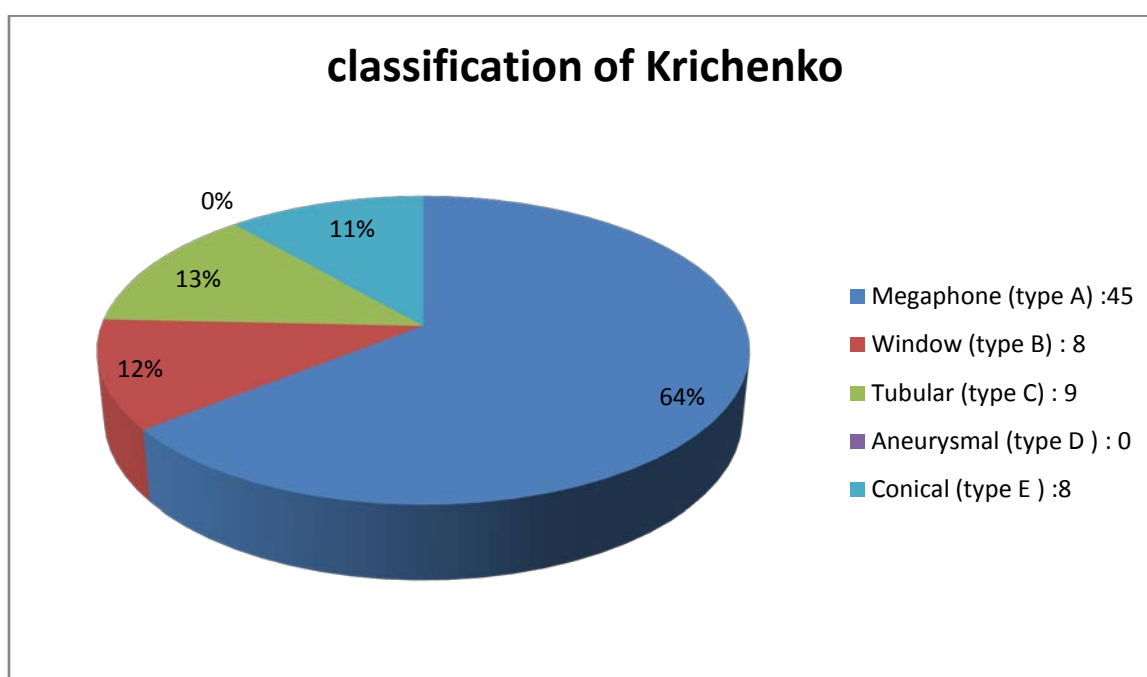
a. Study of the ductus arteriosus

a.1. The channel diameter

The diameter of the ductus arteriosus in our cases ranged between 2mm and 12 mm

Table 6: According to the classification of Krichenko

PDA type	Number of patients	Percentage
Megaphone (type A)	45	64%
Window (type B)	8	12%
Tubular (type C)	9	13%
Aneurysmal (type D)	0	-
Conical (type E)	8	11%



a.2. maximum Doppler velocity

It varied between 3 and 4.57 m/s .

a.3. shunt direction

The shunt is left -right in 70 cases, or 100 % of the cases have been studied .

b. Left heart chambers

The left heart chambers are dilated in 59 cases, or 84% of the studied.

c. Right heart chambers

The right heart chambers are dilated in 5 cases, or 7% of the cases described in our series.

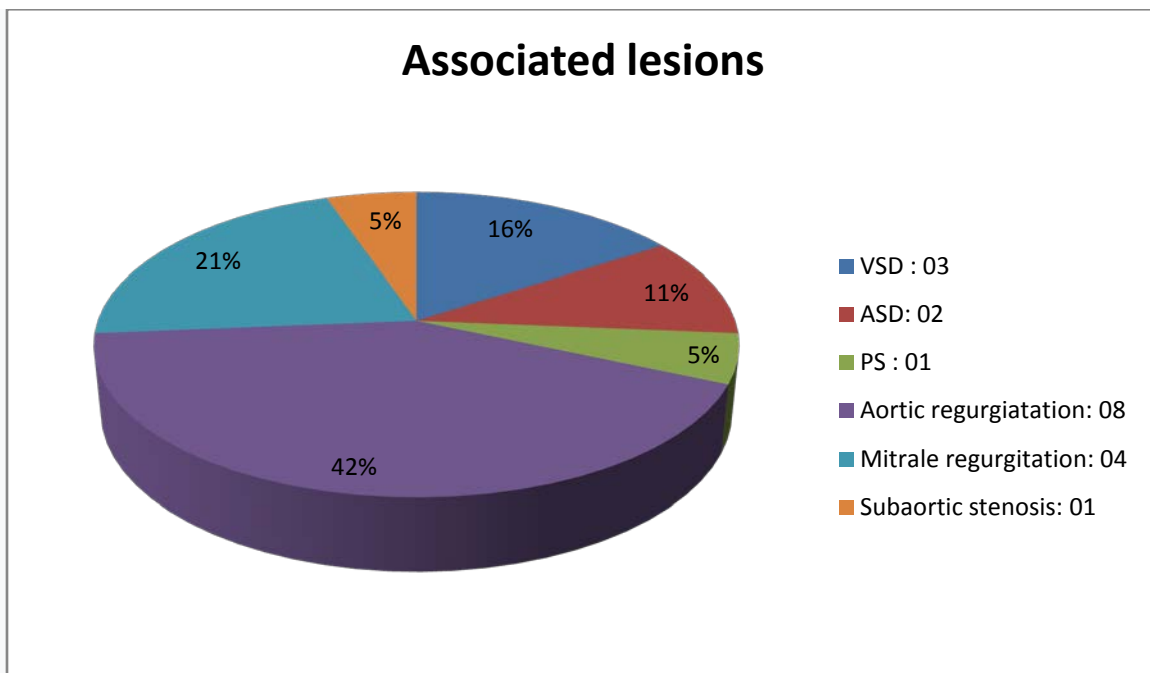
d. Pulmonary arterial hypertension

PAH was found in 25 cases, or 36 % of the cases described in our series.

e. Associated lesions

Are found in 19 patients is a rate of 27%. They are divided as follows:

- VSD : 03
- ASD: 02
- PS : 01
- Aortic regurgiation: 08
- Mitrale regurgitation: 04
- Subaortic stenosis: 01



3. Treatment, Evolution and Post-operative care

Successful PDA closure from 70 patients with ADO device had been achieved in 68 patients (97 %) , unsuccessful attempts was because of the device does not fit the PDA (1 cases). And non disponibility of the adequate device or the PDA is very large with hight risk of the prosthesis migration in other patient.

The success and safety of the procedure in older children contrasts with the difficulties in the youngest babies, mostly less than a year old or less than 5 kg weight.

-The first one, five years old, had large type A ductus with iso-systemic pulmonary hypertension in whom balloon occlusion test was negative (Pulmonary pressure did not fall without decreased aortic pressure). Hence, pulmonary vasodilator test was performed which were positive. Then after the patient underwent surgical PDA ligation later successfully.

-The second patient is 9 months old with large PDA had insufficient ampulla. the large disk protruding in the descending aorta has caused large residual shunting with significant gradient requiring surgical intervention done one two day later.

Results of transcatheter occlusion of PDA have been excellent, and follow-up generally excellent.

Follow-up:12-40 months

II. atrial septal defect

1. Study of epidemiological data

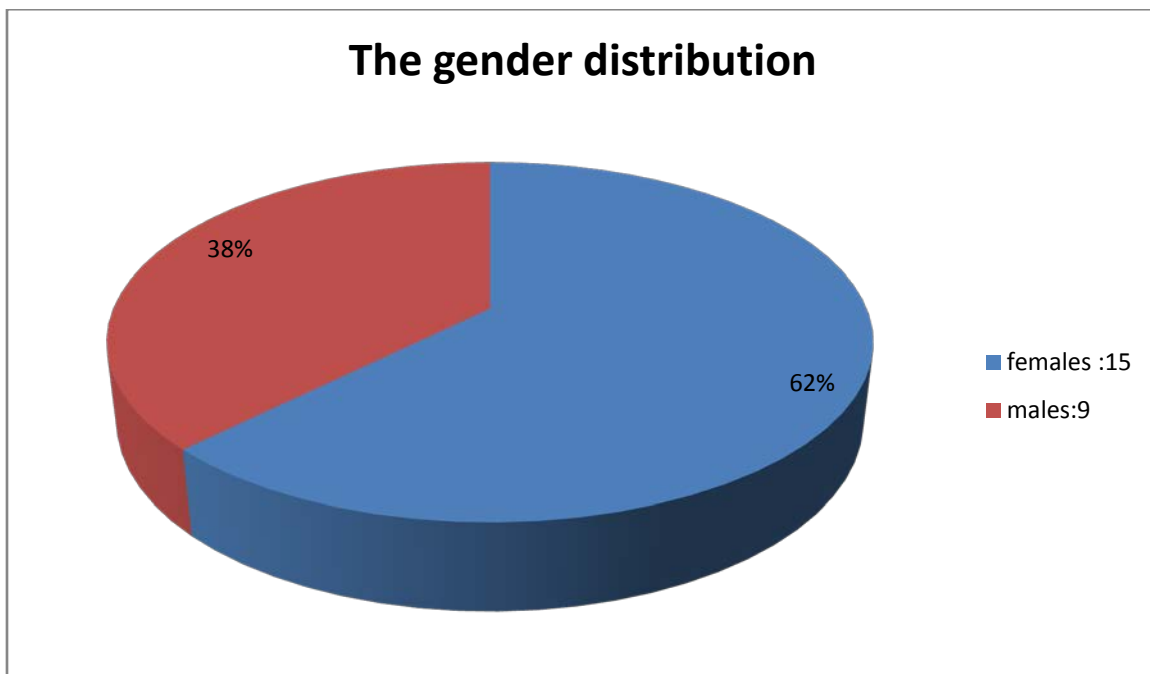
a. Age distribution

We analyzed the medical records of 24 patients , The patients were aged between 3year and 16 years (mean age 8.3 year)

b. Gender distribution

Of the patients,15 (62%) were females and 9 (38%) were males, sex ratio M / F

0.60 distribution



c. Distribution by weight

The patients were weighed between 10 kg and 80 kg. and their mean weight was 26 kg.

d. Genetic syndromes

seven patients had Down syndrome.

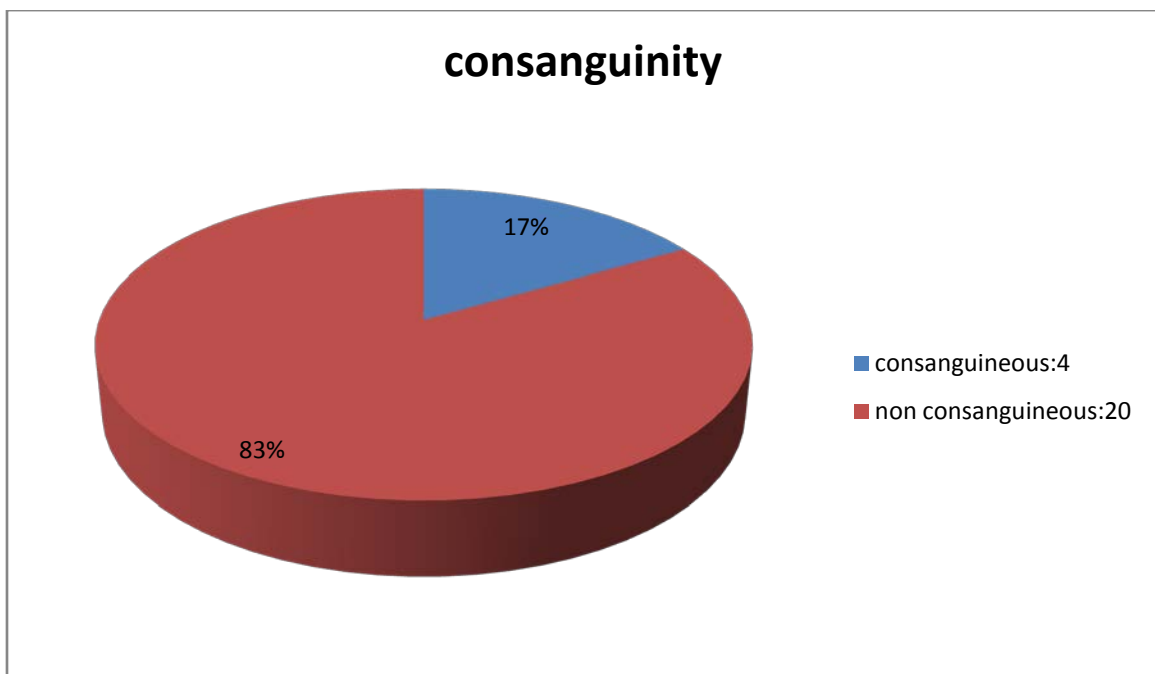
e. Intracardiac disease and ASD

atrial septal defect presented as an isolated lesion in 18 (75%) patients. ASD-associated heart lesions were as follows: 5 cases of pulmonary stenosis, 1 case of PDA.

f. Etiological factors

Consanguinity

The notion of parental consanguinity is noted in 4 patients or 17% of cases.



Personal history

Table 7: Pathological Personal history

Personal history	Number of cases
Down syndrome (Trisomy 21)	7
DiGeorge syndrome (del 22q11)	2
cleft palate	1
choane atresie	1
rheumatic fever	1
facial dysmorphism	1

2.Diagnosis

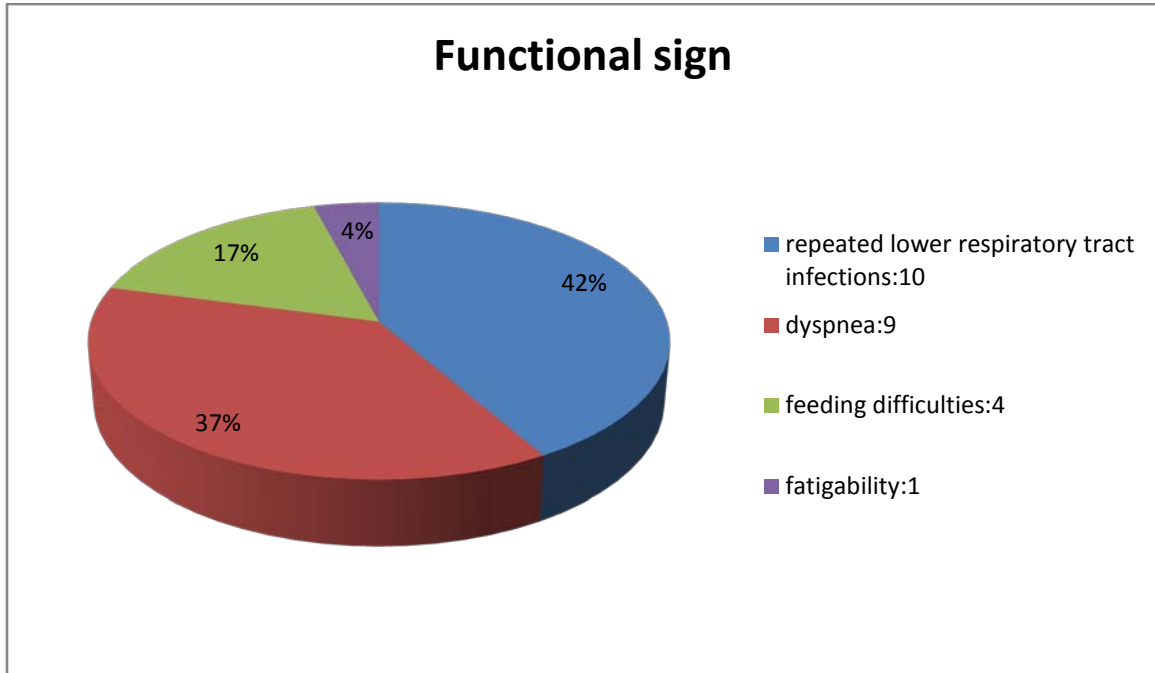
2.1. clinic

2.1.1. functional signs

The clinical symptoms in reported cases in our study are very variable, dominated by dyspnea, feeding difficulties, and repeated lower respiratory tract infections.

Table 8: Distribution of cases according to functional signs

Functional sign	Number of cases	Percentage
repeated lower respiratory tract infections	10	42%
dyspnea	9	37%
feeding difficulty	4	17%
fatigability	1	4%



2.1.2 cardiovascular examination

a. Pulse Examination:

The pulse is present and symmetrical in 24 patients; representing 100% of the cases have been studied.

b. Blood pressure:

No patient of our cases has a pressure gradient between upper and lower extremities.

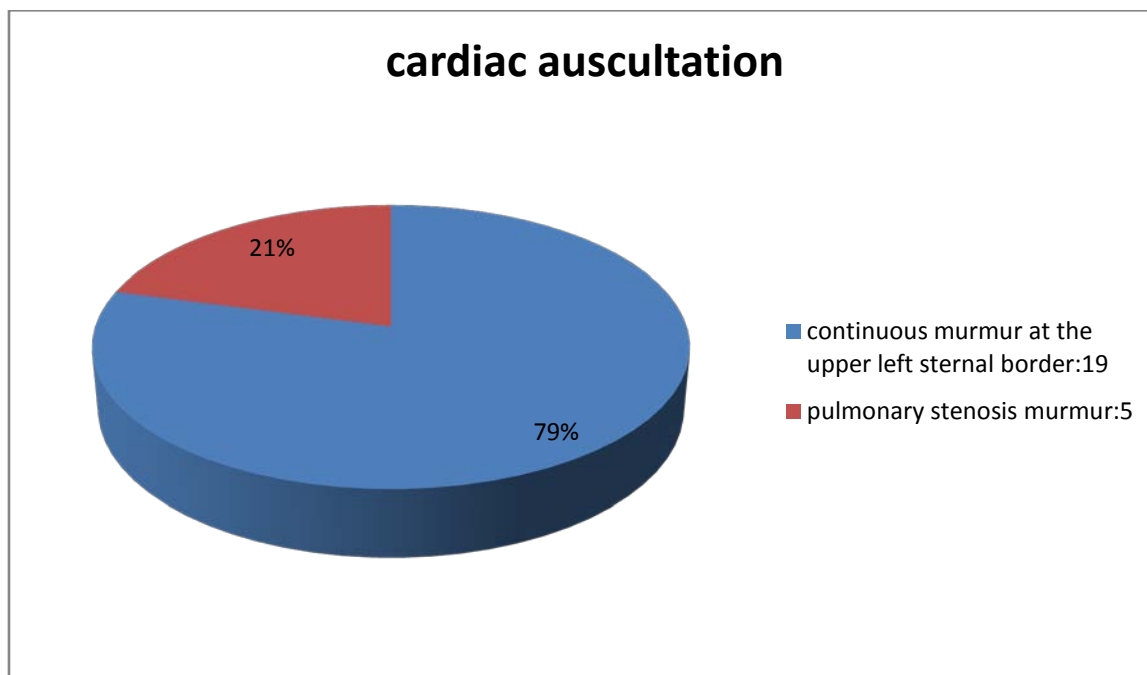
c. Cardiac auscultation:

A heart murmur was found in 24 cases, representing 100% of the cases have been studied.

The data of auscultation are reported in the following table:

Table 9: Result of cardiac auscultation

Result of cardiac auscultation	Number of cases	Percentage
continuous murmur at the upper left sternal border	19	79%
pulmonary stenosis murmur	5	21%



d. Signs of heart failure

No one of our patients has signs of heart failure .

e. The arterial oxygen saturation

The arterial oxygen saturation in ambient air has varied between 95 % and 100%.

2.2. Radiography

2.2.1.Chest X-rays

a. cardiothoracic ratio (CTR)

The CTR in our series ranged between 0.4 and 0.54.

Cardiomegaly was found in 3 patients, or 12.5% of the cases have been studied.

b. The pulmonary vasculature

The analysis of chest radiographs of patients noted in our series:

A pulmonary hypervascularity in 5 cases.

A normal pulmonary vascularity in 19 cases.

c. Left mid-cardiac border

In our series, left mid-cardiac border is straight in 3 cases.

It is convex in 1 cases, and normal in 20 cases

2.2.2. Transthoracic Echo/Doppler

All patients included in our study benefited from ETT, it was used to study the following parameters:

a. Study of the atrial septal defect

All of the ASD are ostium secundum 100 %.

No aortic rim found in 5 cases.

a.1. The channel diameter

The diameter of the atrial septal defect in our cases ranged between 5mm and 24 mm

a.2. maximum Doppler velocity

It varied between 3 and 4.50 m/s .

a.3. shunt direction

The shunt is left –right in 24 cases, or 100 % of the cases have been studied .

b. Left heart chambers

The left heart chambers are dilated in 12 cases, or 50% of the studied.

c. Right heart chambers

The right heart chambers are dilated in all cases, or 100% of the cases described
in our series.

d. Pulmonary arterial hypertension

PAH was found in 3 cases related to respiratory origin, or 13 % of the cases described in our series.

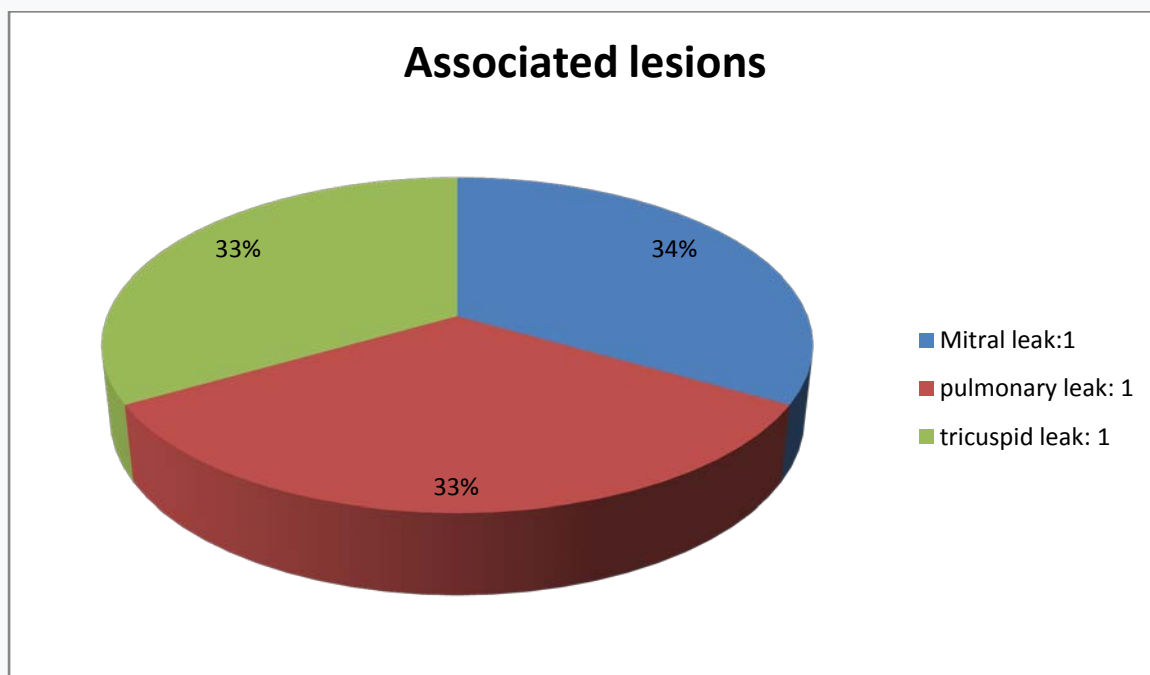
e. Associated lesions

Are found in 3 patients is a rate of 13%. They are divided as follows:

Mitralleak:1

pulmonary leak: 1

tricuspid leak: 1



3. Treatment, Evolution and Post-operative care

Successful ASD closure from 24 patients with ASD device had been achieved in 24 patients (100 %)

Results of transcatheter occlusion of ASD have been excellent, and follow-up generally excellent.

Follow-up:12-36 months

III. ventricular septal defect

1. Study of epidemiological data

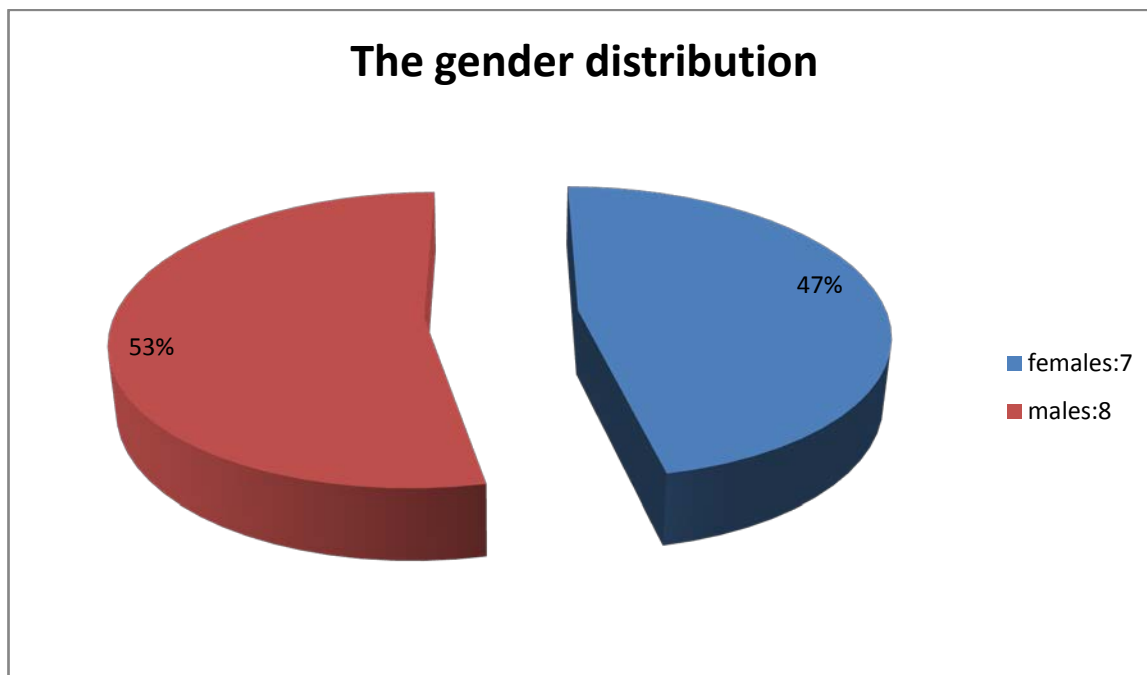
a. Age distribution

We analyzed the medical records of 15 patients , The patients were aged between 1 year and 13 years (mean age 7.6 year)

b. Gender distribution

Of the patients,7(47%) were females and 8 (53%) were males, sex ratio M / F

1.14 distribution



c. Distribution by weight

The patients were weighed between 6 kg and 39 kg. and their mean weight was 22.7 kg.

d. Genetic syndromes

No patient of our cases has Down syndrome

e. Intracardiac disease and VSD

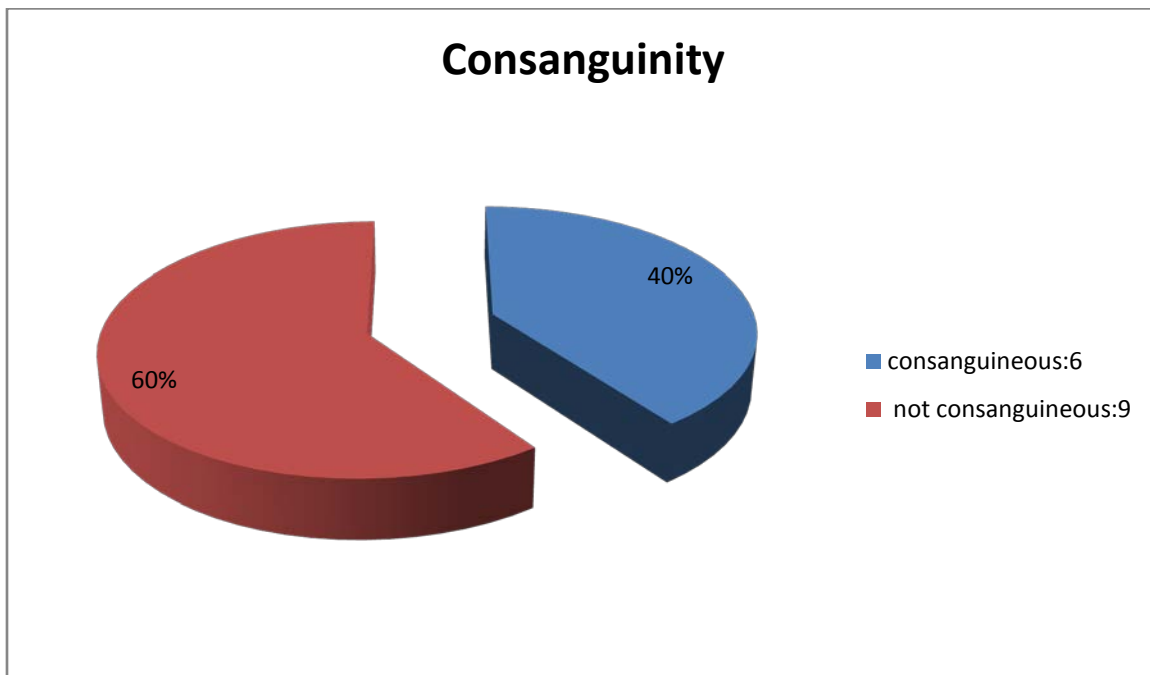
ventricular septal defect presented as an isolated lesion in 14(93%) patients.

VSD-associated heart lesions were as follows: 1 cases of pulmonary stenosis.

f. Etiological factors

Consanguinity

The notion of parental consanguinity is noted in 6 patients or 40% of cases.



Personal history

Table 10: Pathological Personal history

Personal history	Number of cases
atresia of the esophagus	1
cryptorchidism	1
Transposition of the great vessels operated	1

2.Diagnosis

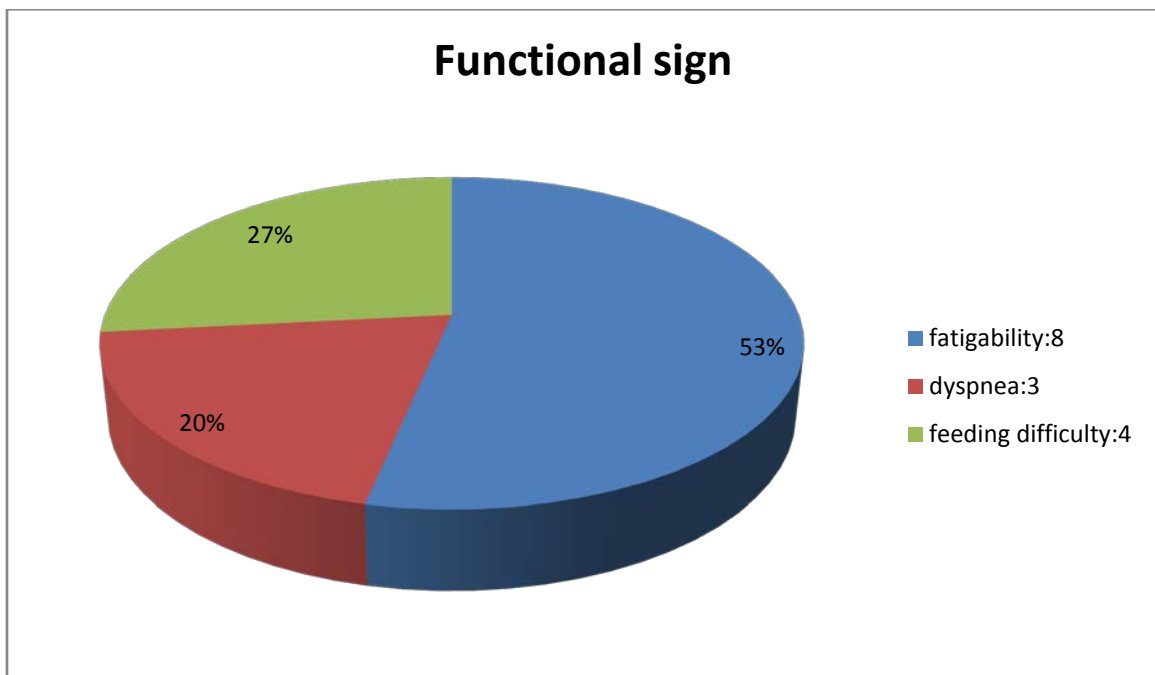
2.1. clinic

2.1.1. functional signs

The clinical symptoms in reported cases in our study are very variable, dominated by dyspnea, feeding difficulties, and fatigability.

Table 11: Distribution of cases according to functional signs

Functional sign	Number of cases	Percentage
fatigability	8	53%
dyspnea	3	20%
feeding difficulty	4	27%



2.1.2 cardiovascular examination

a. Pulse Examination:

The pulse is present and symmetrical in 15 patients; representing 100% of the cases have been studied.

b. Blood pressure:

No patient of our cases has a pressure gradient between upper and lower extremities.

c. Cardiac auscultation:

A systolic heart murmur was found in 15 cases, representing 100% of the cases have been studied.

d. physic Signs of heart failure

one patients of our cases has signs of heart failure or 7%

e. The arterial oxygen saturation

The arterial oxygen saturation in ambient air has varied between 96 % and 100%.

2.2. Radiography

2.2.1.Chest X-rays

a. cardiothoracic ratio (CTR)

The CTR in our series ranged between 0.3 and 0.55.

Cardiomegaly was found in 2 patients, or 13% of the cases have been studied.

b. The pulmonary vasculature

The analysis of chest radiographs of patients noted in our series:

A pulmonary hypervascularity in 12 cases.

A normal pulmonary vascularity in 3 cases.

c. Left mid-cardiac border

In our series, left mid-cardiac border is straight in 2 cases.

and normal in 13 cases

2.2.2. Transthoracic Echo/Doppler

All patients included in our study benefited from ETT, it was used to study the following parameters:

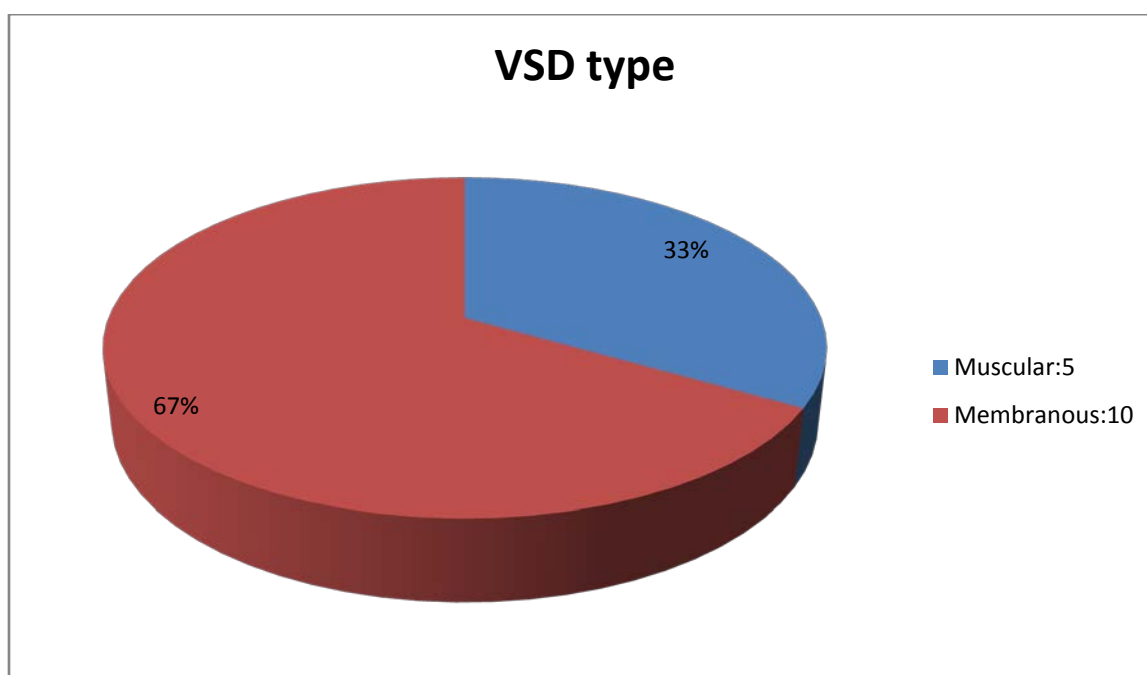
a. Study of the ventricular septal defect

a.1. The channel diameter

The diameter of the ventricular septal defect in our cases ranged between 3mm and 8 mm, the diameter recorder is the right ventricular border.

Table 12: According to the localization

VSD type	Number of patients	Percentage
Membranous	10	67%
Muscular	5	33%



a.2. the number of the VSD

three patients had additional two or more muscular VSD.

a.3. maximum Doppler velocity

It varied between 3.2 and 4.67 m/s .

a.4. shunt direction

The shunt is left –right in 15 cases, or 100 % of the cases have been studied .

b. Left heart chambers

The left heart chambers are dilated in all cases, or 100% of the studied.

c. Right heart chambers

The right heart chambers are dilated in 2 cases, or 13% of the cases described in our series.

d. Pulmonary arterial hypertension

PAH was found in 4 cases, or 27 % of the cases described in our series.

e. Associated lesions

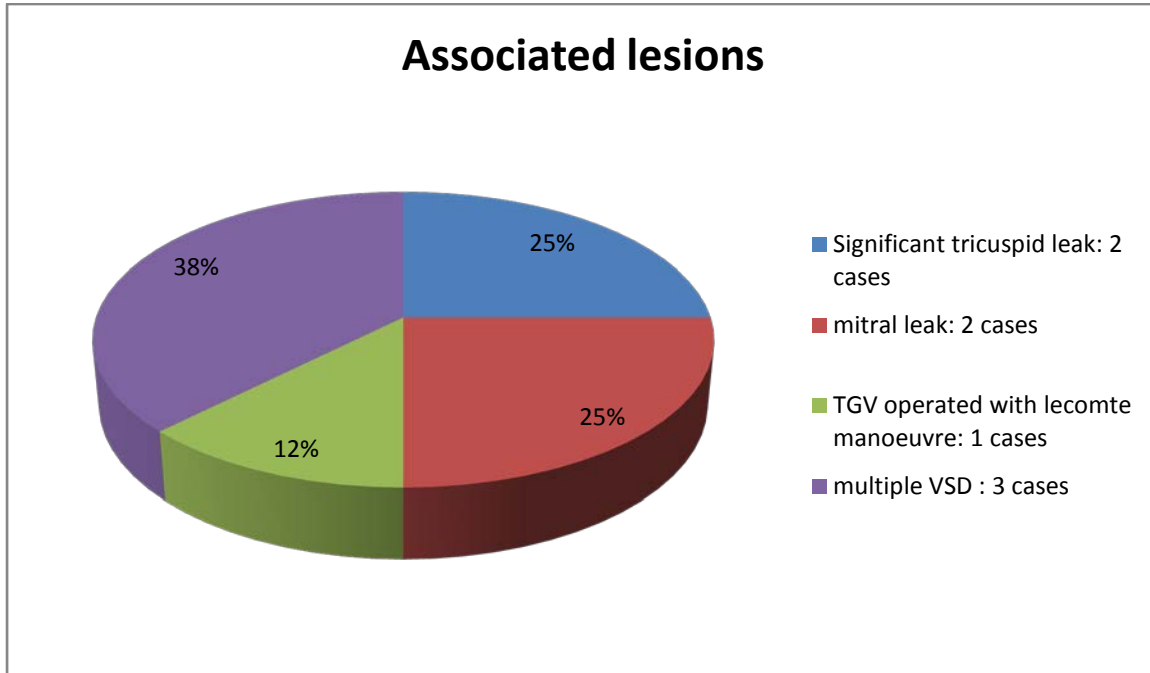
Are found in 8 patients is a rate of 53%. They are divided as follows:

Significant tricuspid leak: 2 cases

mitral leak: 2 cases

TGV operated with lecomte manoeuvre: 1 cases

multiple VSD : 3 cases



3. Treatment, Evolution and Post-operative care

Successful VSD closure from 15 patients with AVSDO device had been achieved

In 15 patients (100%).

Results of transcatheter occlusion of VSD have been excellent, and follow-up generally excellent.

Follow-up: 3-24 months

Coarctation of the aorta

1. Study of epidemiological data

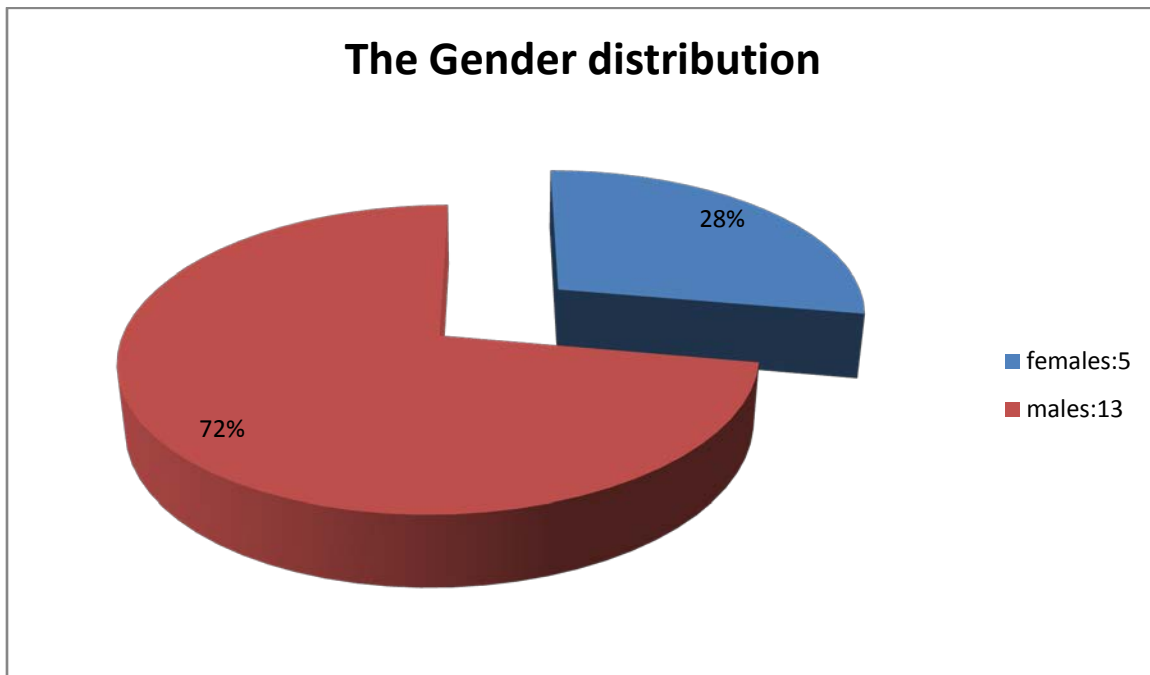
a. Age distribution

We analyzed the medical records of 18 patients , The patients were aged between 2 month and 15 years (mean age 8 year)

b. Gender distribution

Of the patients,5 (28%) were females and 13 (72%) were males, sex ratio M / F

2.60 distribution



c. Distribution by weight

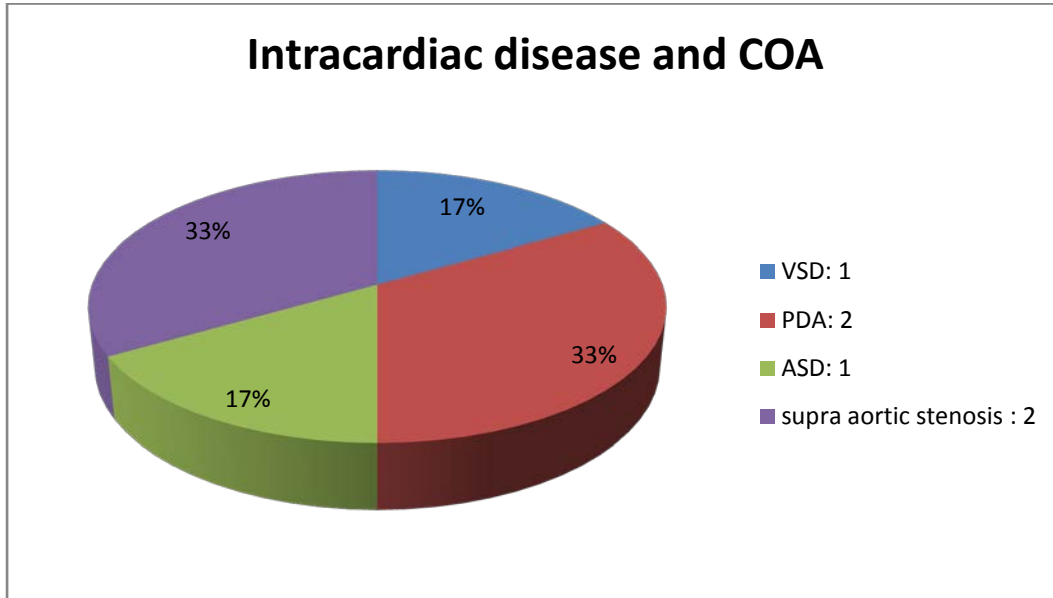
The patients were weighed between 4 kg and 52 kg. and their mean weight was 25.6 kg.

d. Genetic syndromes

No patient of our cases has Down syndrome

e. Intracardiac disease and COA

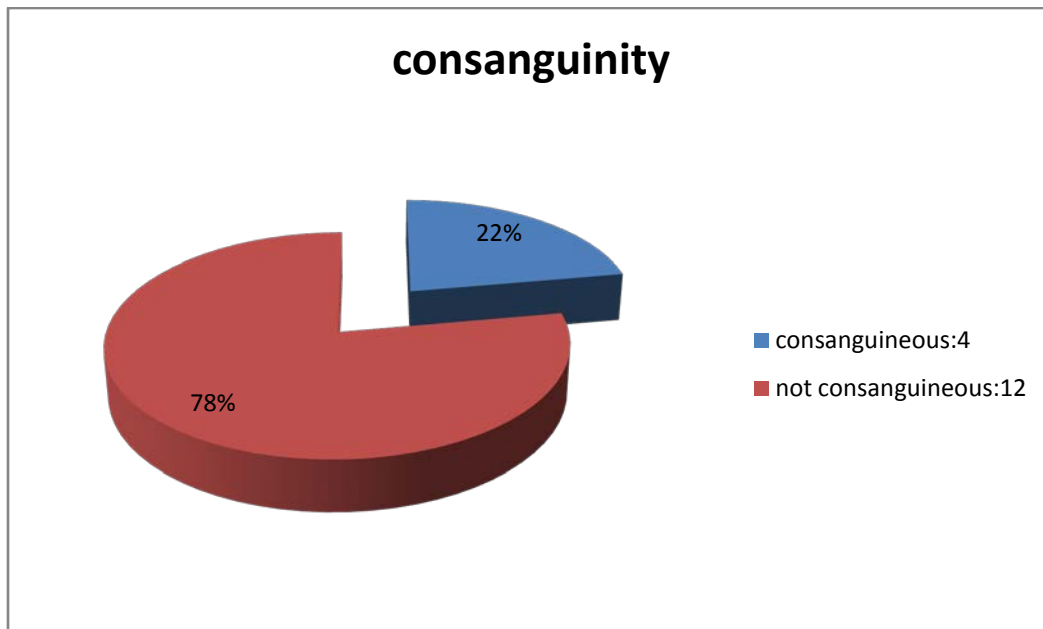
Coarctation of the aorta presented as an isolated lesion in 12(67%) patients, COA-associated heart lesions were as follows: 1 case of VSD, 2 cases of PDA, 1 case of ASD, 2 case of supra aortic stenosis (Williams Beuren syndrome) .



f. Etiological factors

Consanguinity

The notion of parental consanguinity is noted in 4 patients or 22% of cases.



Personal history

Table 13: Pathological Personal history

Personal history	Number of cases
Asian facies	1
Turner syndrome	1
Williams beuren syndrome	2
imperforation anal	1

2.Diagnosis

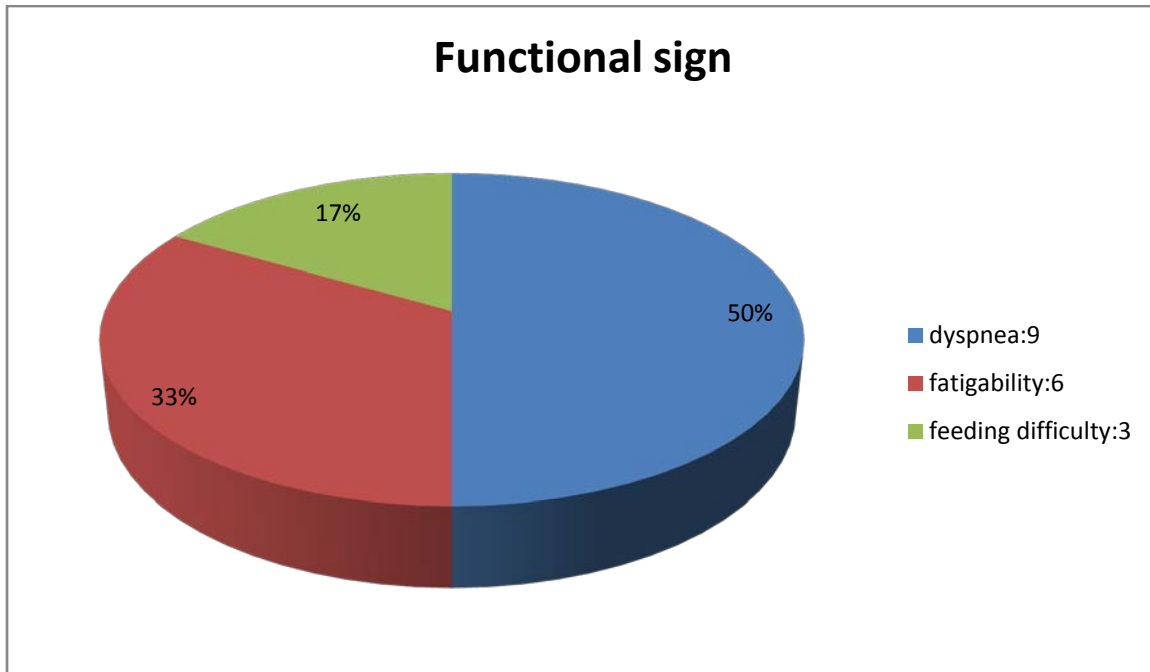
2.1. clinic

2.1.1. functional signs

The clinical symptoms in reported cases in our study are very variable, dominated by dyspnea, feeding difficulties, and fatigability.

Table 14: Distribution of cases according to functional signs

Functional sign	Number of cases	Percentage
dyspnea	9	50%
fatigability	6	33%
feeding difficulty	3	17%



2.1.2 cardiovascular examination

a. Pulse Examination:

The pulse is present and symmetrical in 18 patients; representing 100% of the cases have been studied.

b. Blood pressure:

All patient has a pressure gradient between upper and lower extremities up to 30 mmhg.

c. Cardiac auscultation:

A systolic heart murmur was found in 18 cases, representing 100% of the cases have been studied.

d. Signs of heart failure

No patients of our cases has signs of heart failure

e. The arterial oxygen saturation

The arterial oxygen saturation in ambient air has varied between 91 % and 100%.

2.2. Radiography

2.2.1. Chest X-rays

a. cariorthoracic ratio (CTR)

The CTR in our series ranged between 0.43 and 0.60.

Cardiomegaly was found in 5 patients, or 28% of the cases have been studied.

The pulmonary vasculature

The analysis of chest radiographs of patients noted in our series:

pulmonary hypervascularity in 3 cases.

A normal pulmonary vascularity in 15 cases.

b. Left mid-cardiac border

In our series, left mid-cardiac border is straight in 3 cases.

and normal in 15 cases

2.2.2. Transthoracic Echo/Doppler

Thoracic thoracic ultrasound was performed in all our patients. This examination has the advantage of being non-invasive and repetitive. The ultrasound signs found are summarized in Table 3.

TABLE 15: The main ultrasound signs

Echo-cardiographic signs	Number of cases	Percentage
HVG	11	61%
VG dysfunction	5	28%
Dilation of the aorta	0	0%
Horizontal aortic hypoplasia	0	0%
High gradient up to 30 mmhg	18	100%
OG dilation	1	5%
HVD	2	11%
Aortic bicuspid	4	22%
PAH	5	28%
Pericardial effusion	1	5%
supra aortic stenosis	1	5%
aortic leak	2	11%
mitral leak	3	17%

The mensuration of the aorta in our cases are represented us bellow :

- Horizontal aorta between 7mm and 13mm
- Diaphragm aorta between 11mm and 16mm
- Isthmus aorta between 2mm and 7mm

3. Treatment, Evolution and Post-operative care

8 patients of our cases having benefited for dilation of coarctations of the aorta with stent or 44%

Successful Coarctation of the aorta from 18 patients with Balloon dilation and stent or not had been achieved In 17 patients (94%), unsuccessful attempts was due to the presence of lusoria and the mitigated severity of coarctation .

Results of transcatheter occlusion of Coarctation of the aorta have been excellent, and follow-up generally excellent.

Post-treatment blood pressure gradient reduction to ≤ 20 mm Hg was achieved in 90 %. We noted significant improvement in symptomatology especially in five patients. Clinical and Echo-Doppler follow-up shows good result without restenosis after 10 to 23 months.

Global epidemiological profile of our study (table 16)

parameters	PDA	ASD	VSD	COA	Total number	Mean
Number of cases	70	24	15	18	127	-
mean age	5.4	8.3	7.6	8	29.3	7.32
sex ratio M / F	0.70	0.60	1,10	2.60	-	0.86
mean weight	17	26	22.7	25.6	91.3	22.82
Consanguinity	16	4	6	6	32	25.19%
Down syndrome	13	7	0	0	20	15.74%

Global functional sign of our study (table 17)

Functional sign	PDA	ASD	VSD	COA	Number of cases	Percentage
dyspnea	31	9	3	9	52	40.94%
feeding difficulty	17	4	4	3	28	22%
repeated lower respiratory tract infections	18	10	0	0	28	22%
palpitation	3	0	0	0	3	2.36%
Syncope	1	0	0	0	1	0.78%
fatigability	0	1	8	6	15	11.81%

Radiography of our study (table 18)

Radiography	PDA	ASD	VSD	COA	Number of cases	Percentage
Cardiomegaly	12	3	2	5	22	17.32%
pulmonary hypervascularity	36	5	12	3	56	44%

Transthoracic Echo of our study (table 19)

Transthoracic Echo	PDA	ASD	VSD	COA	Number of cases	Percentage
left heart chambers dilated	59	12	15	11	97	76.37%
right heart chambers dilated	5	24	2	2	33	25.98%
PAH	25	3	4	5	37	29.13%

Treatment results of our study (table 20)

results	success	Percentage
PDA(70 cases)	68	97%
ASD(24 cases)	24	100%
VSD (15 cases)	15	100%
COA(18 cases)	17	94%
		Total success rate: 97.75%

DISCUSSION

PATENT DUCTUS ARTERIOSUS

Since Portsmann et al. placed first Evalonfoam plug prosthesis in 1967, every effort had been done to develop a perfect transcatheter method for PDA occlusion. Diverse devices have been designed and some undergone modification according to the experience in their use and effectiveness. The use of these devices avoids the complications related to surgical procedure, diminishes hospitalization time by immediate recovery. It considers that ideal device is the device that uses catheters of low caliber, that has the capacity of retrieving, that with a delivery system which is effective and easily handled, besides to have the smaller percentage of residual shunts. The amplatzer duct occluder device was designed to provide the most desirable characteristics for percutaneous closure device.

Main characteristics according to others authors

I. Study of epidemiological data

1. Age distribution

In our series the mean age of 70 patients are 5.4 years

In previous series by Kim et al.[159], mean age of 150 patients was 2.6 years, the series by Parra–Bravo JR et al. [160], mean age of 39 patients was 1.8 year ,and the series by Jin M, Liang YM[161] mean age of 1526 patients was 4 years .

This proportion is high compared to the literature data .

2. Gender distribution

In our series there is a female predominance with a sex ratio F / M 1.41

These results confirm the literature data

In previous series by Kim et al [159] sex ratio F/M 1.34

In previous series by Parra–Bravo JR [160] sex ratio F/M 1.43

In previous series by Jin M, Liang YM [161] sex ratio F/M 1.84

3. Distribution by weight

In our series the mean weight are 17 kg .

Lowest weight is 4kg .

In previous series by Kim et al [159]mean weight is 10.2 kg

In previous series by Jin M, Liang YM [161] Mean weight is 15.3 kg

In previous series by Koch A [162] mean weight of 160 patients is 24.3 kg

4. PDA and notion of consanguinity

In our series, the concept of parental consanguinity was observed in 16 patients or 23% of cases.

These results confirm the literature data

In the study of Mani A, Meraji SM [163],they found that patent ductus arteriosus

(PDA), a common congenital heart disease, accounts for a higher fraction of congenital heart disease in Iran (15%) than in the United States (2–7%). Moreover, Iranian PDA cases demonstrated a marked increase of parental consanguinity (63%),compared with the general Iranian population (25%)

In the series of Bouchta.N. [164], 18 % of cases (80 patients) had a parental consanguinity.

II. Diagnosis

1.clinic

a. functional signs

The clinical symptoms vary depending on the importance of the shunt, on the size of the channel and the level of pulmonary vascular resistance.

Table 21: The clinical symptoms according to others authors

Authors	Repeated lower respiratory tract infections	Dyspnea
Chaara [165]	35,2%	35,29%
Laraaki [166]	34,7%	60,86%
Bencherif [167]	19%	38%
Kettani [168]	31,7%	63,41%
Faik [169]	36%	28%
Elmamoun [172]	17,7%	53,2%
Our series	26 %	44 %

b. cardiac auscultation

A typical continuous murmur can be heard at the patients with patent ductus arteriosus, which is the most frequently described in literature.

It was first described in 1847 in "London Medical Gazette" as "murmur that accompanying first sound...extended to the second sound, so there is no interruption of the murmur before the second sound had already started".

Later, in 1900, George Gibson presented a more precise description. "It persists trough the second sound and dies away gradually during the long pause.

The murmur is rough and trembling. It begins softly and increases in intensity so as to reach its acme just about, or immediately after, the incidence of the second sound, and from that point gradually wanes until its termination"

Continuous murmurs of patent ductus arteriosus consists of two components: a crescendo systolic one and a decrescendo diastolic one, with a peak of intensity around second sound [170]. It is best heard at second left intercostals space or immediately left infraclavicular. It is continuous because the ductus arteriosus provides a permanent communication between the systemic circulation, with high pressure, and the pulmonary circulation, where pressure level is much lower.

About half of patent ductus arteriosus murmurs in children are not truly continuous and many are only systolic. This is because with the pulmonary vasoconstriction secondary to a large shunt, there is often a moderate degree of pulmonary hypertension, which decreases the aortic-pulmonary artery gradient more in diastole than in systole.

Those with large ductus have been described by Eddy sounds, clicks or crackles at the end of systole and at the beginning of the diastole [171].

Table 22: Result of cardiac auscultation according to others authors

Result of cardiac auscultation	Our series	Elmamoun [172]	Faik[169]
continuous murmur at the upper left sternal border	41 (58 %)	28 (45,16%)	17(34%)
Systolic murmur	25 (36 %)	21 (33,87%)	14 (28%)
pulmonary stenosis murmur	4 (6 %)	-----	-----

2.Radiography

a. Transthoracic Echo/Doppler data

The echocardiographic findings are typically diagnostic for patent ductus arteriosus (PDA). High velocity jets of turbulent flow in the pulmonary artery can be reliably detected by color flow Doppler imaging; this technique is sensitive in detecting even the small PDA. Relying on alternative imaging techniques to make the diagnosis of this condition is unusual. Additionally, echocardiography provides important diagnostic information regarding associated congenital cardiovascular malformations.

By 2-dimensional (2-D) echocardiography, the aortic end of the patent ductus arteriosus (PDA) is localized first, and then it is tracked back to the pulmonary artery. Precisely documenting the size, shape, and course of the ductus is difficult.

The patent ductus arteriosus (PDA) can be seen most easily in the parasternal short axis view and from the suprasternal notch. The classic patent ductus arteriosus (PDA) connects the junction of the main pulmonary artery and the left pulmonary artery with the aorta just below and opposite the left subclavian artery.

If no other abnormalities are present, Doppler echocardiography reveals

continuous flow from the aorta into the main pulmonary artery. If the magnitude of the left-to-right shunt is large, continued flow around the aortic arch into the ductus arteriosus in diastole and flow reversal in the descending aorta are evident.

Also, variable levels of continuous flow in the branch pulmonary arteries related to the magnitude of the shunt are observed. As the shunt magnitude increases,

increased flow in the pulmonary veins is evident and the left atrium enlarges. With a small or moderate-sized patent ductus arteriosus (PDA), the left ventricular size is often normal, but as shunt magnitude increases, the left ventricular diastolic size also increases. (Q_p/Q_s can be calculated using Doppler velocity and left ventricular/right ventricular (LV/RV) outflow tract dimensions).

Table 23: Transthoracic Echo/Doppler features according to others authors

Transthoracic echo/ Doppler features	Our series (25 cases)		Zarriq.s. (90 cases)	Elmamoun (62 cases)
	the channel diameter	<4mm	39	66
>4mm		31	44	54
maximum Doppler velocity	<4 m/s	47	36	-
	>4 m/s	23	74	-
dilated left heart chambers		59	38	46
Dilated right heart chambers		5	8	9
PAH		25	34	45

b.Chest ray x features

Chest radiographic features may vary depending on whether it is isolated or associated with other cardiac anomalies and with the direction of shunt flow (right to left or left to right). Can have cardiomegaly (predominantly left atrial and left ventricular enlargement if not complicated). Obscuration of the aortopulmonary window and features of pulmonary oedema may be evident.

III. Treatment, Evolution and Post-operative care

The first transcatheter closure of PDA was performed by Portsman et al. in late 1960s. This initial work was continued by Rashkind et al. in late 1970s, after which it is performed and developed worldwide.

We found that PDA transcatheter closure has a high success rate and rarely causes major complication in most of the cases.

Successful PDA closure from 70 patients with ADO device had been achieved in 68 patients (97 %) , unsuccessful attempts was because of the device does not fit the PDA (1 cases), And non disponibility of the adequate device or the PDA is very large with hight risk of the prosthesis migration in other patient.

The success and safety of the procedure in older children contrasts with the difficulties in the youngest babies, mostly less than a year old or less than 5 kg weight,

the mismatch between the baby weight and the devices should be recorded.

-The first one, five years old, had large type A ductus with iso-systemic pulmonary hypertension in whom balloon occlusion test was negative (Pulmonary pressure did not fall without decreased aortic pressure). Hence, pulmonary vasodilator test was performed which were positive. Then after the patient underwent surgical PDA ligation later successfully.

-The second patient is 9 months old with large PDA had insufficient ampulla. the large disk protruding in the descending aorta has caused large residual shunting with significant gradient requiring surgical intervention done one two day later.

Results of transcatheter occlusion of PDA have been excellent, and follow-up generally excellent.

Previous studies have shown that transcatheter closure of PDA is quite an established technique with no reported mortality and low morbidity.

A retrospective case series of 1808 patients undergoing transcatheter closure of PDA showed that overall PDA closure rate was 94 %, and the rate of major average events were 1.5 % [173].

atrial septal defect

Since King and colleagues reported the first transcatheter device closure of a secundum defect in 1976, the development of fluoroscopically guided catheter-based interventions has revolutionised the management of congenital heart disease. The transcatheter occlusion procedure has been considered the primary mode of treatment for patients with secundum ASD in many centres , because it has been regarded as generally safe and effective. The traditional intervention is performed under fluoroscopic and angiographic guidance, which can offer excellent visualisation and tracking performance. However, the radiation exposure issue in cardiac catheterisations, especially therapeutic cardiac catheterisation, is particularly relevant for infants and children because of their higher radiosensitivity compared with adults, the large fraction of the body irradiated by the X-ray beam, and the probable need to repeat the procedure. Moreover, radiation exposure in childhood may significantly increase lifetime cancer risk concern because children have immature developing organ and tissue structures, and may potentially have a longer lifespan.

Main characteristics according to others authors

1. Age distribution

In our series the mean age of 24 patients are 8.3 years

In previous series by Yifeng Yang.[174], mean age of 114 patients was 5.4years,

the series by John F. Rhodes Jr. [175], mean age of 435 patients was 6.5 year

2. Gender distribution

In our series there is a female predominance with a sex ratio F / M 1.66

These results confirm the literature data

In previous series by Yifeng Yang [174] sex ratio F/M 1.07

In previous series by John F. Rhodes Jr. [175] sex ratio F/M 1.66

3. Distribution by weight

In our series the mean weight are 26 kg .

Lowest weight is 10kg .

In previous series by Yifeng Yang [174]mean weight is 23.5 kg

In previous series by John F. Rhodes Jr [175] Mean weight is 22.6 kg

4. Transthoracic Echo/Doppler data

The diameter of the atrial septal defect in our cases ranged between 5mm and 24 mm

The diameter of the atrial septal defect In previous series by Yifeng Yang[174]ranged between 6mm and 24 mm

The diameter of the atrial septal defect In previous series by John F. Rhodes Jr[175]ranged between 1.7mm and 25 mm

5. RESULTATS

Successful ASD closure in our cases had been achieved in 24 patients (100 %)

Successful ASD closure in previous series by Yifeng Yang[174] had been achieved in 110 patients (96.5%)

Successful ASD closure in previous series by John F. Rhodes Jr [175]had been achieved in 414 patients (95%)

ventricular septal defect

Ventricular septal defect (VSD) is the most common congenital heart disease. Surgery has been performed for many years and is considered to be the gold standard for the treatment of VSD. However, it is associated with morbidity and mortality. Percutaneous closure of VSDs is performed under general anesthesia and with fluoroscopic and transesophageal echocardiographic guidance. Two devices of the Amplatzer family are currently used to close percutaneously muscular and perimembranous VSD with a closure rate of 97% (incidence of major complication 2.2%) and 97.5% (major acute complications in 1.2%), respectively. Occurrence of complete atrioventricular block is reported in 1% of subjects. Acquired VSD can occur as post-surgical residual leak, as a traumatic event or as consequence of a myocardial infarction. There are few data about percutaneous closure of post-surgical residual VSD and of traumatic VSD. As for the surgical approach, in patients with post-myocardial infarction VSD success rate of percutaneous closure is around 88% with a mortality of 22%. The currently available data show that, in experienced hands, percutaneous closure is a safe and effective procedure. Device closure of muscular and perimembranous VSD is a real alternative to the standard surgical approach with the advantage of a significantly reduced rate of mortality and complications.

Main characteristics according to others authors

1. Age distribution

In our series the mean age of 15 patients are 7.6 years

In previous series by Mario Carminati.[176], mean age of 430 patients was 8years,

the series by Sahar El Shedoudy. [177], mean age of 80 patients was 5.3 year

2. Gender distribution

In our series there is a male predominance with a sex ratio M / F 1.14

These results confirm the literature data

In previous series by Mario Carminati [176] sex ratio M/F 1.04

In previous series by Sahar El Shedoudy. [177] sex ratio M/F 0.6

3. Distribution by weight

In our series the mean weight are 22 kg .

Lowest weight is 6kg .

In previous series by Mario Carminati [176] mean weight is 28kg.

In previous series by Sahar El Shedoudy [177] Mean weight is 17.24 kg.

4. Transthoracic Echo/Doppler data

The diameter of the ventricular septal defect in our cases ranged between 3mm and 8 mm.

The diameter of the ventricular septal defect In previous series by Mario Carminati[176] ranged between 3mm and 22 mm

The diameter of the ventricular septal defect In previous series by Sahar El Shedoudy[177] ranged between 6mm and 13 mm

Table 24: VSD types according to others authors

<u>VSD types</u>	<u>Our series</u> <u>(15cases)</u>	<u>Mario</u> <u>Carminati(430cases)</u>	<u>Sahar El</u> <u>Shedoudy(80)</u>
muscular	5	119	2
membranous	10	250	77
Multiple VSD	3	16	----
Residual post-surgery	----	45	----
Gerbode	----	----	1

5.RESULTATS

Successful VSD closure in our cases had been achieved in 15 patients (100 %)

Successful VSD closure in previous series by Mario Carminati[176] had been achieved in 410 patients (95.3%).

Successful ASD closure in previous series by Sahar El Shedoudy[177] had been achieved in 79 patients (98.7%).

Coarctation of the aorta

Surgical repair for coarctation of the aorta has been the only treatment of choice since 1945. Balloon angioplasty emerged as an alternative therapy for coarctation of the aorta in 1982. However, residual/recurrent coarctation, aneurysm formation and aortic dissection are the main disadvantages of balloon angioplasty. Moreover, elastic recoil of vessels and unfavorable anatomy such as long tubular narrowing or hypoplasias of the isthmus are the main causes of failure³. Balloon expandable endovascular stents have been used in various locations since the 1980, and have been used in coarctation of the aorta in humans since 1989. The most common criteria for treating coarctation of the aorta with stents have been previous surgical repair, high surgical risk, refusal of consent for surgical intervention and unfavorable anatomy for balloon angioplasty (tubular long segment, hypoplastic isthmus and hypoplastic distal arch). Stents provide a homogeneous framework for smooth endothelial growth along the aortic wall that reduces the risk of thrombosis, neointimal hyperplasia and subsequent restenosis. Young age, hypoplastic isthmus and distal aortic arch represent the major drawbacks for balloon angioplasty and also stent implantation. In the present study, the patients had undergone previous balloon angioplasty or surgery and had residual or recurrent coarctation. There are some complications with endovascular stents related with technique, and these affect the aorta and other vasculature. Technique complications are migration or fracture of the stent, rupture of the balloon, and brachiocephalic vessel obstructions⁹. Aortic dissection or rupture of the intima media and aneurysm formation are rare but important complications. Although emergent surgical intervention can be lifesaving in the case of severe dissections, dissections may be treated successfully with placement of additional stents, especially covered stents. In the present study, since covered stents were not available during the study period in

our center, stent implantation was considered in a very select group of patients with native coarctation to avoid these kinds of complications. In other words, patients with severe and/or very long segment coarctations having a high risk of aneurysm or aortic rupture during bare stent implantation were directly referred to surgery. Complications related with vascular access are vascular injury, embolism and cerebrovascular attacks. During stent implantation, the vascular injury rate is higher than with balloon angioplasty because of the larger diameter of the material used in stenting. However, lower restenosis risk and aneurysm rates, and re-dilatability make the stent implantation popular. In our series, balloon rupture occurred during the re-dilatation of the Palmaz stent for neointimal hyperplasia. Restenosis may be seen in stents due to the growth of the child, intimal hyperplasia and fracture or compression of the stent. In recent studies, research is underway on breakable and bioabsorbable-biodegradable stents for clinical use. Newer biodegradable stents are being used in infants today. In conclusion, stent implantation may be a feasible alternative to balloon angioplasty and surgery in adolescents. Patients with previous surgical repair, high surgical risk, unfavorable anatomy, or refusal of consent for surgical intervention are the best candidates for stent implantation. However, longer follow-up and new studies are necessary especially in younger patients.

Main characteristics according to others authors

1. Age distribution

In our series the mean age of 18 patients are 8 years

In previous series by Ali Baykan.[178], mean age of 10 patients was 12.4years,

the series by John P. Cheatham. [179], mean age of 21 patients was 12 years

2. Gender distribution

In our series there is a male predominance with a sex ratio M / F 2.60

These results confirm the literature data

In previous series by Ali Baykan [178] sex ratio M/F 9

In previous series by John P. Cheatham. [179] sex ratio M/F 2.50

3. Distribution by weight

In our series the mean weight are 25.6 kg .

Lowest weight is 4kg .

In previous series by Ali Baykan [178] mean weight is 35.8kg.

In previous series by John P. Cheatham [179] Mean weight is 46.2 kg.

4. Distribution by native coarctation

In our series, 13 patients had native aortic coarctation, while 5 patients had recurrent aortic obstruction after earlier attempted surgical and/or transcatheter therapy.

In previous series by John P. Cheatham[179], 8 patients had native aortic coarctation, while 13 patients had recurrent aortic obstruction after earlier attempted surgical and/or transcatheter therapy.

In previous series by Sara Bondanza[180], 23 patients had native aortic coarctation of 34 patients, while 11 patients had recurrent aortic obstruction after earlier attempted surgical and/or transcatheter therapy.

5. Transthoracic Echo/Doppler data

The diameter of the coarctation of the aorta in our cases revealed minimum coarctation size of 7 mm and maximum of 13 mm, isthmus size of 2 to 7 mm , and descending aorta size at diaphragm level of 11 to 16 mm.

The diameter of the coarctation of the aorta In previous series by Ali Baykan[178] revealed minimum coarctation size of 5 mm and maximum of 12 mm, isthmus size of 7 to 17 mm , and descending aorta size at diaphragm level of 10 to 25 mm.

6. RESULTATS

Successful Coarctation of the aorta in our cases had been achieved in 17 patients (94 %).

Successful Coarctation of the aorta in previous series by Ali Baykan[178] had been achieved in 10 patients (100%).

Successful Coarctation of the aorta in previous series by John P. Cheatham[179] had been achieved in 21 patients (100%).

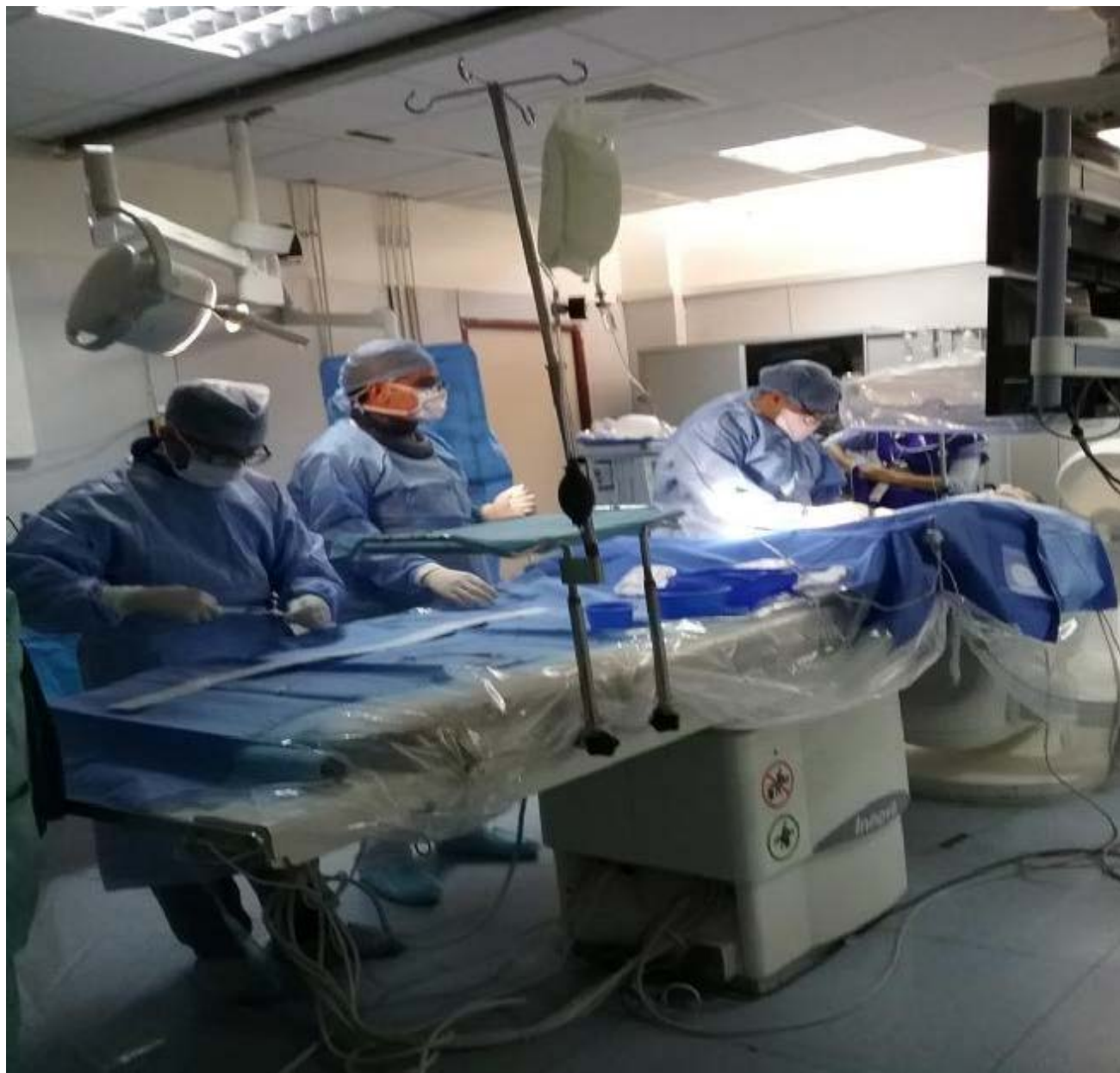

Figure.32 Salle de KT Interventionnel -CHU HASSAN II- FES



Figure.33 Equipe de cathé pédiatrique

Médecins:

Pr Atmani Samir	Professeur agrégé de pédiatrie .
Pr Harrandou Mustapha	Chef de service de reanimation mere–enfant
Pr Labib Smail	Service de reanimation mere–enfant
Pr Berdai Adnan	Service de reanimation mere–enfant
Dr Berrada Aicha	Résidente de service de reanimation M–E
Dr Bazine myriame	Résidente de service de reanimation M–E
Dr Touzani soumaya	Résidente de service de reanimation M–E

Infirmier :

Mr Abdelali Mahfoud	Infirmier polyvalent
Mlle Qadida Khadija	Aide soignante

CONCLUSION

Our work focused on 127 cases of percutaneous closure of intracardiac shunts(70 PDA,24 ASD,15 VSD) using the Amplatzer device and dilated coarctations of the aorta with or without stents(28cases) , in Pediatric Medical and Surgical Unit – University Hospital Hassan II –Fez , from June 2015 to November 2019.

Epidemiological Aspect

PDA

The patients were aged between 1 month and 16 years, with mean age (5.4 year).

A female predominance with a sex ratio F/M 1.41.

The patients were weighed between 4kg and 53 kg, with mean weight (17 kg).

ASD

The patients were aged between 3 years and 16 years, with mean age (8.3 year).

A female predominance with a sex ratio F/M 1.66.

The patients were weighed between 10kg and 80 kg, with mean weight (26 kg).

VSD

The patients were aged between 1 years and 13 years, with mean age (7.6 year).

A male predominance with a sex ratio M/F 1.14.

The patients were weighed between 6kg and 39 kg, with mean weight (22.7 kg).

COA

The patients were aged between 2 month and 15 years, with mean age (8 year).

A male predominance with a sex ratio M/F 2.60.

The patients were weighed between 4kg and 52 kg, with mean weight (25.6 kg).

Etiological Aspect

PDA

The notion of parental consanguinity is noted in 23% of cases.

thirteen patients had Down syndrome (Trisomy 21) .

Two cases had a SGA at birth (Small for gestational age) .

Two cases had rheumatic fever.

ASD

The notion of parental consanguinity is noted in 17% of cases.

seven patients had Down syndrome (Trisomy 21) .

Two cases had DiGeorge syndrome.

one case had choane atresie.

VSD

The notion of parental consanguinity is noted in 40% of cases.

No patient had Down syndrome (Trisomy 21) .

one case had atresia of the esophagus.

one case had Transposition of the great vessels.

COA

The notion of parental consanguinity is noted in 22% of cases.

No patient had Down syndrome (Trisomy 21) .

one case had Turner syndrome.

Two cases had Williams beuren syndrome.

Clinical Outcomes

PDA

The clinical symptoms dominated by dyspnea, feeding difficulties, and repeated lower respiratory tract infections.

The outcome of cardiac auscultation, 58% of cases had a continuous murmur at the upper left sternal border ,36 % had a systolic murmur .

ASD

The clinical symptoms dominated by dyspnea, feeding difficulties, and repeated lower respiratory tract infections.

The outcome of cardiac auscultation, 79 % of cases had a continuous murmur at the upper left sternal border ,21 % had a pulmonary stenosis murmur.

VSD

The clinical symptoms dominated by dyspnea, feeding difficulties, and fatigability.

The outcome of cardiac auscultation,100 % of cases had a systolic murmur .

COA

The clinical symptoms dominated by dyspnea, feeding difficulties, and fatigability.

The outcome of cardiac auscultation, 100% of cases had a systolic murmur.

Transthoracic Echo/Doppler & chest ray X outcomes

PDA

Cardiomegaly was found in 12 patients, or 17% of the cases .

The diameter of the ductus arteriosus in our cases ranged between 2mm and 12 mm.

The shunt is left-right in 100 % of our cases.

The left heart chambers are dilated in 59 cases.

PAH was found in 25 cases.

ASD

Cardiomegaly was found in 3 patients, or 17% of the cases .

The diameter of the atrial septal defect in our cases ranged between 5mm and 24 mm.

The shunt is left–right in 100 % of our cases.

The left heart chambers are dilated in 12 cases.

PAH was found in 3 cases.

VSD

Cardiomegaly was found in 2 patients, or 13% of the cases .

The diameter of the ventricular septal defect in our cases ranged between 3mm and 8 mm.

The shunt is left–right in 100 % of our cases.

The left heart chambers are dilated in 15 cases.

PAH was found in 4 cases.

COA

Cardiomegaly was found in 5 patients, or 28% of the cases .

The mensuration of the aorta in our cases are represented us bellow :

- Horizontal aorta between 7mm and 13mm
- Diaphragm aorta between 11mm and 16mm
- Isthmus aorta between 2mm and 7mm

The left heart chambers are dilated in 11 cases.

PAH was found in 5cases.

Treatment, Evolution

PDA

Successful PDA closure from 70 patients with ADO device had been achieved in 68 patients (97 %) , unsuccessful attempts was because of the device does not fit the PDA (1 cases), And non disponibility of the adequate device or the PDA is very large with high risk of the prosthesis migration in other patient.

Results of transcatheter occlusion of PDA have been excellent, and follow-up generally excellent.

ASD

Successful ASD closure from 24 patients with ASO device had been achieved in 24 patients (100 %)

Results of transcatheter occlusion of ASD have been excellent, and follow-up generally excellent.

VSD

Successful VSD closure from 15 patients with AVSDO device had been achieved

In 15 patients (100%).

Results of transcatheter occlusion of VSD have been excellent, and follow-up generally excellent.

COA

8 patients of our cases having benefited for dilation of coarctations of the aorta with stent or 44%.

Successful Coarctation of the aorta from 18 patients with Balloon dilation and stent or not had been achieved In 17 patients (94%), unsuccessful attempts was due to the presence of lusoria and the mitigated severity of coarctation .

Results of transcatheter occlusion of Coarctation of the aorta have been excellent, and follow-up generally excellent.

ABSTRACT

Summary

Title : interventional catheterization treatment in view of a percutaneous closing of the intracardiac shunts and a dilation of the coarctations of the aorta with stent or not.

Author : Amr Noor aldin .

KEYWORDS : Patent ductus arteriosus; atrial septal defect; ventricular septal defect; coarctation of the aorta; Diagnosis; Transcatheter occlusion; Amplatzer duct occluder; Amplatzer Septal Occluder; balloon angioplasty; Stent.

Percutaneous closure by pediatric interventional catheterization using implantable devices is a safe and effective approach for the treatment of intracardiac shunts, it offers several advantages compared to surgical closure of Patent ductus arteriosus, atrial septal defect and in certain ventricular septal defect.

Percutaneous dilation with or without stent placement is a good alternative to surgery for the treatment of coarctation of the aorta.

This is a retrospective study in the medical and surgical pediatric cardiovascular unit, pediatrics, CHU Hassan II Fez, between June 2015 and November 2019.

This study is interested in 127 patients having benefited from interventional catheterization treatment in view of a percutaneous closing of the intracardiac shunts and a dilation of the coarctations of the aorta with stent or not.

These 127 cases are divided according to the gender into 68 girls and 59 boys

with a sex ratio of 1.15 .

The age varies from 1 month to 16 years with an average age of 7.3 years.

The weight varies from 4 kg (lowest weight) to 80 kg with an average age of 22.8 kg.

On the etiological aspect , the concept of consanguinity was found in 25.19 % of cases .

Trisomy 21 is the most common chromosomal aberration in our study 15.7 % .

The clinical symptoms are variable according to the importance of the left to right shunt and the coarctation of the aorta .

Echocardiography is an important diagnostic tool and is a mainstay for the diagnosis and evaluation prior to management .

The treatment is essentially by transcatheter approach using amplatzer occluder device and balloon angioplasty/ Stent.

This Device and balloon/stent was successfully deployed in 97.75 % of patients .

short- and long-term outcomes following transcatheter are generally excellent.

Resume :

Titre : Traitement par cathétérisme interventionnel en vue d'une fermeture percutanée des shunts intracardiaques et d'une dilatation des coarctations de l'aorte avec stent ou pas.

Auteur : Amr Noor aldin .

Mots-clés: canal artériel; communication interauriculaire ; communication interventriculaire; coarctation de l'aorte ;Diagnostic ;KT interventionnel ; prothèse d'amplatz ; ballon d'angioplastie ; stent.

La fermeture percutanée par cathétérisme interventionnel pédiatrique à l'aide de dispositifs implantables est une approche sur et efficace pour le traitement des shunts intracardiaques, elle offre plusieurs avantages par rapport à la fermeture chirurgicale d'un canal artériel, d'une communication inter auriculaire et dans certaines communications interventriculaires.

La dilatation percutanée avec ou sans mise en place de stent est une bonne alternative au chirurgie pour le traitement de la coarctation de l'aorte.

Il s'agit d'une étude rétrospective réalisée dans l'unité médicochirurgicale cardio-pédiatrique, service de pédiatrie, CHU Hassan II Fès, entre juin 2015 et novembre 2019.

Cette étude s'intéresse à 127 patients ayant bénéficié d'un traitement par cathétérisme interventionnel en vue d'une fermeture percutanée des shunts intracardiaques et d'une dilatation des coarctations de l'aorte avec stent ou pas.

Ces 127 cas sont répartis selon le sexe en 68 filles et 59 garçons avec un sex-ratio de 1,15.

L'âge varie de 1 mois à 16 ans avec une moyenne d'âge de 7,3 ans.

Le poids varie de 4 kg (poids le plus bas) à 80 kg avec un âge moyen de 22,8 kg.

Sur l'aspect étiologique, le concept de consanguinité a été retrouvé dans 25,19% des cas.

La trisomie 21 est l'aberration chromosomique la plus courante dans notre étude 15,7%.

Les symptômes cliniques sont variables selon l'importance de la shunt gauche à droit et la coarctation de l'aorte.

L'échocardiographie est un outil de diagnostic important et un pilier de la diagnostic et évaluation avant la prise en charge.

Le traitement est essentiellement par approche transcathéter à l'aide d'un amplificateur dispositif d'occlusion et angioplastie par ballonnet / stent.

Cet appareil et ce ballon / stent ont été déployés avec succès chez 97.75% des patients.

les résultats à court et à long terme après transcathéter sont généralement excellent.

ملخص :

العنوان: علاج القسطرة التداخلية من أجل الإغلاق عن طريق الجلد للمهمات داخل القلب وتمدد احتقان الشريان الأورطي مع أو بدون دعامات.

المؤلف: عمرو نور الدين.

الكلمات الرئيسية: القناة الشريانية السالكة. عيب الحاجز الأذيني. عيب الحاجز البطيني. تضيق في الشريان الأورطي؛ التشخيص.

؛ بالون، أنجيوبلاستي؛ الدعامات Amplatzer Septal مطهر Amplatzer انسداد الفتحة مطبق القناة.

الإغلاق عن طريق الجلد عن طريق القسطرة التداخلية للأطفال باستخدام الأجهزة المزروعة هو طريقة آمنة وفعالة لعلاج القطع داخل القلب ، وهو يوفر العديد من المزايا مقارنة بالإغلاق الجراحي لشرايين القناة الشريانية ، وعيوب الحاجز الأذيني وبعض عيوب الحاجز البطيني.

التمدد عن طريق الجلد مع أو بدون وضع الدعامة هو بديل جيد لعملية جراحية لعلاج انسداد الشريان الأورطي هذه دراسة بأثر رجعي في وحدة القلب والأوعية الدموية الطبية والجراحية للأطفال ، طب الأطفال ، المستشفى الجامعي حسن الثاني فاس ، بين يونيو 2015 و نوفمبر 2019.

تهتم هذه الدراسة بـ 127 مريضاً استفادوا من علاج القسطرة التداخلية في ضوء الإغلاق عن طريق الجلد للمهمات

داخل القلب وتمدد احتقان الشريان الأورطي مع الدعامات أم لا.

وتنقسم هذه الحالات 127 وفقاً لنوع الجنس إلى 68 فتاة و 59 فتى

مع نسبة الجنس من 1.15.

يتراوح العمر بين شهر و 16 سنة بمتوسط 7.3 سنوات.

يتراوح الوزن من 4 كجم (أقل وزن) إلى 80 كجم بمتوسط عمر

22.8 كجم

على الجانب المسبب للمرض ، تم العثور على مفهوم التقارب في 25.19 % .

هو انحراف الكروموسومات الأكثر شيوعاً في دراستنا بنسبة 15.7%. متلازمة داون

تختلف الأعراض السريرية حسب أهمية التحويلة من اليسار إلى اليمين وتقييد الشريان الأورطي.

تخطيط صدى القلب هو أداة تشخيصية مهمة وهو الدعامة الأساسية للتشخيص والتقييم قبل الإدارة.

يتم العلاج بشكل أساسي عن طريق نهج القسطرة باستخدام جهاز مطهر. amplatzer و قسطرة البالون / الدعامات

تم نشر هذا الجهاز وبالون / الدعامة بنجاح في 97.75 % من المرضى.

النتائج قصيرة وطويلة الأجل بعد القسطرة هي بشكل عام ممتازة.

BIBLIOGRAPHY

1. Mitchell SC, Korones SB, Berendes HW (1971) Congenital heart disease in 56,109 births. Incidence and natural history. *Circulation* 43: 323–332.
2. Krichenko A, Benson LN, Burrows P, Möes CA, McLaughlin P, et al. (1989) Angiographic classification of the isolated, persistently patent ductus arteriosus and implications for percutaneous catheter occlusion. *Am J Cardiol* 63: 877–880.
3. Conti CR, Faxon DP, Gruentzig A, Gunnar RM, Lesch M, Reeves TJ. 17th Bethesda Conference: adult cardiology training. Task Force III: training in cardiac catheterization. *J Am Coll Cardiol*. 1986;7:1205–1206.
4. Ryan TJ, Bauman WB, Kennedy JW, Kereiakes DJ, King SB III, McCallister BD, Smith SC Jr, Ulliyot DT. Guidelines for percutaneous transluminal coronary angioplasty: a report of the American Heart Association/American College of Cardiology Task Force on Assessment of Diagnostic and Therapeutic Cardiovascular Procedures (Committee on Percutaneous Transluminal Coronary Angioplasty). *Circulation*.. 1993;88:2987–3007
5. Rao PS. Transcatheter occlusion of patent ductus arteriosus: Which method to use and which ductus to close? (Editorial). *Am Heart J* 1996; 132: 905– 907
6. Rao PS (2001) Summary and Comparison of Patent Ductus Arteriosus Closure Devices. *Curr Interv Cardiol Rep* 3: 268–274.
7. Rao PS, Kern MJ (2003): Catheter Based Devices for the Treatment of Noncoronary Cardiovascular Disease in Adults and Children. Lippincott, Williams & Wilkins, Philadelphia, PA, 145–153.
8. Rao PS (2102) Historical aspects of transcatheter treatment of heart disease in children. *Pediatr Therapeut*.
9. Laborde F, Noirhomme P, Karam J, Batisse A, Bourel P, et al. (1993) A new video-assisted thoracoscopic surgical technique for interruption of patent ductus arteriosus in infants and children. *J Thorac Cardiovasc Surg* 105: 278–280.

10. Rao PS (1996) Transcatheter occlusion of patent ductus arteriosus: which method to use and which ductus to close. *Am Heart J* 132: 905–909.
11. Gianturco C, Anderson JH, Wallace S (1975) Mechanical device for arterial occlusion. *Am J Roentgenol* 124: 428–435.
12. Cambier PA, Kirby WC, Wortham DC, Moore JW (1992) Percutaneous closure of the small (less than 2.5 mm) patent ductus arteriosus using coil embolization. *Am J Cardiol* 69: 815–816.
13. Hijazi ZM, Geggel RL (1994) Results of anterograde transcatheter closure of patent ductus arteriosus using single or multiple Gianturco coils. *Am J Cardiol* 74: 925–929.
14. Sommer RJ, Gutierrez A, Lai WW, Parness IA (1994) Use of preformed nitinol snare to improve transcatheter coil delivery in occlusion of patent ductus arteriosus. *Am J Cardiol* 74: 836–839.
15. Hays MD, Hoyer MH, Glasow PF (1996) New forceps delivery technique for coil occlusion of patent ductus arteriosus. *Am J Cardiol* 77: 209–211.
16. Berdjis F, Moore JW (1997) Balloon occlusion delivery technique for closure of patent ductus arteriosus. *Am Heart J* 133: 601–604.
17. Dalvi B, Goyal V, Narula D, Kulkarni H, Ramakantan R (1997) A new technique using temporary balloon occlusion for transcatheter closure of patent ductus arteriosus with Gianturco coils. *Cathet Cardiovasc Diagn* 41: 62–70.
18. Rao PS, Balfour IC, Chen S (1997) Effectiveness of five-loop coils to occlude patent ductus arteriosus. *Am J Cardiol* 80: 1498–1501.
19. Rao PS, Balfour IC, Jureidini SB, Singh GK, Chen SC (2000) Five-loop coil occlusion of patent ductus arteriosus prevents recurrence of shunt at follow-up. *Catheter Cardiovasc Interv* 50: 202–206.

20. Kuhn MA, Latson LA (1995) Transcatheter embolization coil closure of patent ductus arteriosus--modified delivery for enhanced control during coil positioning. *Cathet Cardiovasc Diagn* 36: 288–290.
21. Prieto LR, Latson LA, Dalvi B, Arbetman MM, Ebeid MR, et al. (1999) Transcatheter coil embolization of abnormal vascular connections using a new type of delivery catheter for enhanced control. *Am J Cardiol* 83: 981–983.
22. Owada CY, Teitel DF, Moore P (1997) Evaluation of Gianturco coils for closure of large ($>$ or $=$ 3.5 mm) patent ductus arteriosus. *J Am Coll Cardiol* 30: 1856–1862.
23. Grifka MD RG, Jones TK (2000) Transcatheter closure of large PDA using 0.052" gianturco coils: controlled delivery using a biptome catheter through a 4 French sheath. *Catheter Cardiovasc Interv* 49: 301–306.
24. Liang CD, Wu CJ, Fang CY, Ko SF, Wu YT (2001) Retrograde transcatheter occlusion of patent ductus arteriosus: preliminary experience in Gianturco coil technique without heparinization. *J Invasive Cardiol* 13: 31–35.
25. Cambier PA, Stajduhar KC, Powell D (1994) Improved safety of transcatheter vascular occlusion utilizing a new retrievable coil device. *J Am Coll Cardiol* 23: 359A.
26. Uzun O, Hancock S, Parsons JM, Dickinson DF, Gibbs JL (1996) Transcatheter occlusion of the arterial duct with Cook detachable coils: early experience. *Heart* 76: 269–273.
27. Rao PS (2001) Coil occlusion of patent ductus arteriosus. *J Invasive Cardiol* 13: 36–38.
28. Grifka RG, Vincent JA, Nihill MR, Ing FF, Mullins CE (1996) Transcatheter patent ductus arteriosus closure in an infant using the Gianturco–Grifka Vascular Occlusion Device. *Am J Cardiol* 78: 721–723.

29. Grifka RG (2001) Transcatheter PDA closure using the Gianturco–Grifka vascular occlusion device. *Current Intervent Cardiol Reports* 3: 174–182.
30. Magal C, Wright KC, Duprat G Jr, Wallace S, Gianturco C (1989) A new device for transcatheter closure of the patent ductus arteriosus. A feasibility study in dogs. *Invest Radiol* 24: 272–276.
31. Sharafuddin MJ, Gu X, Titus JL, Sakinis AK, Pozza CH, et al. (1996) Experimental evaluation of a new self–expanding patent ductus arteriosus occluder in a canine model. *J Vasc Interv Radiol* 7: 877–887.
32. Masura J, Walsh KP, Thanopoulous B, Chan C, Bass J, et al. (1998) Catheter closure of moderate– to large–sized patent ductus arteriosus using the new Amplatzer duct occluder: immediate and short–term results. *J Am Coll Cardiol* 31: 878–882.
33. Rao PS (2011) Percutaneous closure of patent ductus arteriosus—current status. *J Invasive Cardiol* 23: 517–520.
34. Mavroudis C, Backer CL, Gevitz M (1994) Forty–six years of patent ductus arteriosus division at Children’s Memorial Hospital of Chicago. Standards for comparison. *Ann Surg* 220: 402–409.
35. Bensky AS, Raines KH, Hines MH (2000) Late follow–up after thoracoscopic ductal ligation. *Am J Cardiol* 86: 360–361.
36. Henry G, Danilowicz D, Verma R. Severe hemolysis following partial coil–occlusion of patent ductus arteriosus. *CathetCardiovascDiagn.* 1996;39:410–2.
37. van der Linde D, Konings EE, Slager MA, et al. Birth prevalence of congenital heart disease worldwide: a systematic review and meta–analysis. *J Am Coll Cardiol* 2011;58:2241–7.

38. Al-Qbandi M, Cao QL, Hijazi ZM. Atrial septal defect: Amplatz-type ASD Occluders. In: Sievert H, Qureshi SA, Wilson N, et al. editors. Interventions in structural, valvular, and congenital heart disease. 2nd ed. CRC Press, 2015:437-47.
39. Praz F, Wahl A, Schmutz M, et al. Safety, feasibility, and long-term results of percutaneous closure of atrial septal defects using the amplatzer septal occluder without periprocedural echocardiography. *J Invasive Cardiol* 2015;27:157-62.
40. Tzifa A, Gordon J, Tibby SM, et al. Transcatheter atrial septal defect closure guided by colour flow Doppler. *Int J Cardiol* 2011;149:299-303.
41. Baruteau AE, Hascoet S, Fraise A. Transthoracic echocardiography is a safe alternative for assessment and guidance of transcatheter closure of secundum atrial septal defect in children. *J Thorac Dis* 2017;9:1247-56.
42. Wang JK, Tsai SK, Lin SM, et al. Transcatheter closure of atrial septal defect without balloon sizing. *Catheter Cardiovasc Interv* 2008;71:214-21.
43. Kazmouz S, Kenny D, Cao QL, et al. Transcatheter closure of secundum atrial septal defects. *J Invasive Cardiol* 2013;25:257-64.
44. Amin Z, Hijazi ZM, Bass JL, et al. Erosion of Amplatz septal occluder device after closure of secundum atrial septal defects: review of registry of complications and recommendations to minimize future risk. *Catheter Cardiovasc Interv* 2004;63:496-502.
45. Søndergaard L, Loh PH, Franzen O, et al. The first clinical experience with the new GORE(R) septal occluder (GSO). *EuroIntervention* 2013;9:959-63.
46. Smith B, Thomson J, Crossland D, et al. UK multicenter experience using the Gore septal occluder (GSO(TM)) for atrial septal defect closure in children and adults. *Catheter Cardiovasc Interv* 2014;83:581-6.

47. Varma C, Benson LN, Silversides C, et al. Outcomes and alternative techniques for device closure of the large secundum atrial septal defect. *Catheter Cardiovasc Interv* 2004;61:131–9.
48. Podnar T, Martanovic P, Gavora P, et al. Morphological variations of secundum-type atrial septal defects: feasibility for percutaneous closure using Amplatzer septal occluders. *Catheter Cardiovasc Interv* 2001;53:386–91.
49. Mathewson JW, Bichell D, Rothman A, et al. Absent posteroinferior and anterosuperior atrial septal defect rims: Factors affecting nonsurgical closure of large secundum defects using the Amplatzer occluder. *J Am Soc Echocardiogr* 2004;17:62–9.
50. Koenig P, Cao QL, Heitschmidt M, et al. Role of intracardiac echocardiographic guidance in transcatheter closure of atrial septal defects and patent foramen ovale using the Amplatzer device. *J Interv Cardiol* 2003;16:51–62.
51. Remadevi KS, Francis E, Kumar RK. Catheter closure of atrial septal defects with deficient inferior vena cava rim under transesophageal echo guidance. *Catheter Cardiovasc Interv* 2009;73:90–6.
52. Kammache I, Mancini J, Ovaert C, et al. Feasibility of transcatheter closure in unselected patients with secundum atrial septal defect, using Amplatzer devices and a modified sizing balloon technique. *Catheter Cardiovasc Interv* 2011;78:665–74.
53. Amin Z. Echocardiographic predictors of cardiac erosion after Amplatzer septal occluder placement. *Catheter Cardiovasc Interv* 2014;83:84–92.
54. Santoro G, Bigazzi MC, Lacono C, et al. Transcatheter closure of complex atrial septal defects: feasibility and mid-term results. *J Cardiovasc Med (Hagerstown)* 2006;7:176–81.

55. Johri AM, Witzke C, Solis J, et al. Real-time three-dimensional transesophageal echocardiography in patients with secundum atrial septal defects: outcomes following transcatheter closure. *J Am Soc Echocardiogr* 2011;24:431–7.
56. Silvestry FE, Cohen MS, Armsby LB, et al. Guidelines for the Echocardiographic Assessment of Atrial Septal Defect and Patent Foramen Ovale: From the American Society of Echocardiography and Society for Cardiac Angiography and Interventions. *J Am Soc Echocardiogr* 2015;28:910–58.
57. Szkutnik M, Masura J, Bialkowski J, et al. Transcatheter closure of double atrial septal defects with a single Amplatzer device. *Catheter Cardiovasc Interv* 2004;61:237–41.
58. Godart F, Houeijeh A, Recher M, et al. Transcatheter closure of atrial septal defect with the Figulla((R)) ASD Occluder: a comparative study with the Amplatzer((R)) Septal Occluder. *Arch Cardiovasc Dis* 2015;108:57–63.
59. Roymanee S, Promphan W, Tonklang N, et al. Comparison of the Occlutech (R) Figulla (R) septal occluder and Amplatzer (R) septal occluder for atrial septal defect device closure. *Pediatr Cardiol* 2015;36:935–41.
60. Grohmann J, Hohn R, Fleck T, et al. Transcatheter closure of atrial septal defects in children and adolescents: single-center experience with the GORE(R) septal occluder. *Catheter Cardiovasc Interv* 2014;84:E51–7.
61. de Hemptinne Q, Horlick EM, Osten MD, et al. Initial clinical experience with the GORE(R) CARDIOFORM ASD occluder for transcatheter atrial septal defect closure. *Catheter Cardiovasc Interv* 2017;90:495–503.
62. Lertsapcharoen P, Khongphatthanayothin A, Srimahachota S, et al. Self-expanding platinum-coated nitinol devices for transcatheter closure of atrial septal defect: prevention of nickel release. *J Invasive Cardiol* 2008;20:279–83.

63. Thanopoulos BD, Biasco L, Dardas P, et al. Catheter closure of atrial septal defects using the Cocoon septal occluder: preliminary results of a European multicenter study. *Int J Cardiol* 2014;177:418–22.
64. Peirone A, Contreras A, Ferrero A, et al. Immediate and short-term outcomes after percutaneous atrial septal defect closure using the new nit-occlud ASD-R device. *Catheter Cardiovasc Interv* 2014;84:464–70.
65. Ramoğlu MG, Ucar T, Tutar E. Early malfunction of polyvinyl alcohol membrane of septal occluder. *Catheter Cardiovasc Interv* 2016;87:E151–3.
66. Labombarda F, Roule V, Beygui F. Delayed spontaneous perforation of polyvinyl alcohol membrane-Covered atrial septal defect closure devices. *Catheter Cardiovasc Interv* 2017;89:E141–4.
67. Bartel T, Bonaros N, Muller S. Device failure weeks to months after transcatheter closure of secundum type atrial septal defects. *Heart* 2010;96:1603.
68. Nassif M, Abdelghani M, Bouma BJ, et al. Historical developments of atrial septal defect closure devices: what we learn from the past. *Expert Rev Med Devices* 2016;13:555–68.
69. Costache V, Chavanon O, Thony F, Blin D: Aortic arch embolization of an Amplatzer occluder after an atrial septal defect closure: hybrid operative approach without circulatory arrest. *Eur. J. Cardiothorac. Surg.* 28,340–342 (2005).
70. Amin Z, Hijazi Z, Bass J, Cheatham J, Hellenbrand W, Kleinman C: Erosion of Amplatzer septal occluder device after closure of secundum atrial septal defects: review of registry of complications and recommendations to minimize future risk. *Catheter Cardiovasc. Interv.* 63, 496–502 (2004).
71. Schoen SP, Boscheri A, Lange SA *et al.*: Incidence of aortic valve regurgitation and outcome after percutaneous closure of atrial septal defects and patent foramen ovale. *Heart* 94, 844–847 (2008).

72. Wörhle J, Kochs M, Spiess J, Nusser T, Hombach V, Merkle N: Impact of percutaneous device implantation for closure of patent foramen ovale on valve insufficiencies. *Circulation* 119, 3002–3008(2009).
73. Casolo G, Gensini GF, Santoro G, Rega L: Anomalous origin of the circumflex artery and patent foramen ovale: a rare cause of myocardial ischaemia after percutaneous closure of the defect. *Heart* 89,E23 (2003).
74. Mortelmans K, Post M, Thijs V, Herroelen L, Budts W: The influence of percutaneous atrial septal defect closure on the occurrence of migraine. *Eur. Heart J.* 26, 1533–1537(2005).
75. Rodes-Cabau J, Mineau S, Marrero A *et al.*: Incidence, timing, and predictive factors of new-onset migraine headache attack after transcatheter closure of atrial septal defect or patent foramen ovale. *Am. J. Cardiol.* 101,688–692 (2008).
76. Fernandez-Mayoralas DM, Fernandez-Jaen A, Muñoz-Jareño N, Gutierrez-Larraya F, Calleja-Perez B, San Antonio Arce V: Migraine symptoms related to the percutaneous closure of an ostium secundum atrial septal defect: report of four paediatric cases and review of the literature. *Cephalalgia* 27, 550–556 (2007).
77. Suda K, Raboisson M, Piette E, Dahdah N, Miro J: Reversible atrioventricular block associated with closure of atrial septal defects using the Amplatzer device. *J. Am. Coll. Cardiol.* 43, 1677–1682 (2004).
55 Celiker A, Ozkutlu S, Karakurt C, Karagoz T: Cardiac dysrhythmias after closure of ASD with Amplatzer device. *Turk. J. Pediatr.* 47, 323–326 (2005).
78. Nehgme R, Huddleston A, Cheatham J: Progression to late complete atrioventricular block following Amplatzer device closure of atrial septal defect in a child. *Pediatr. Cardiol.* 30, 367–370 (2009).

79. Khairy P, O'Donnell C, Landzberg M: Transcatheter closure versus medical therapy of patent foramen ovale and presumed paradoxical thromboemboli: a systematic review. *Ann. Intern. Med.* 139, 753–760 (2003).
80. Windecker S, Wahl A, Chatterjee T *et al.*: Percutaneous closure of patent foramen ovale in patients with paradoxical embolism: long-term risk of recurrent thromboembolic events. *Circulation* 101, 893–898 (2000).
81. Mullen MJ, Hildick-Smith D, De Giovanni JV *et al.*: BioSTAR Evaluation Study (BEST): a prospective, multicenter, Phase I clinical trial to evaluate the feasibility, efficacy, and safety of the BioSTAR bioabsorbable septal repair implant for the closure of atrial-level shunts. *Circulation* 114, 1962–1967 (2006).
82. Schubert S, Peters B, Abdul-Khaliq H, Nagdyman N, Lange P, Ewert P: Left ventricular conditioning in the elderly patient to prevent congestive heart failure after transcatheter closure of atrial septal defect. *Catheter Cardiovasc. Interv.* 64, 333–337 (2005).
83. Peters B, Ewert P, Schubert S *et al.*: Self-fabricated fenestrated Amplatzer occluders for transcatheter closure of atrial septal defect in patients with left ventricular restriction: midterm results. *Clin. Res. Cardiol.* 95, 88–92 (2006).
84. Fyler DC: Nadas' Pediatric Cardiology. Hanly & Belfus, Inc., Philadelphia, PA. 1992.
85. Rao PS: Congenital heart defects – A review. In: Rao PS, ed. *Congenital Heart Disease – Selected Aspects*. InTech, ISBN 978-953-307-472-6, Rijeka, Croatia, 2011; 3–44.
86. Rao PS: Consensus on timing of intervention for common congenital heart diseases: part I – cyanotic heart defects. *Indian J Pediatr.* 2013; 80(1): 32–8.
87. Rashkind WJ. Interventional cardiac catheterization in congenital heart disease. *Int J Cardiol* 1985;7:1–10.

88. Beekman RH, Rocchini AP, Rosenthal A. Transcatheter atrial septal defect closure: preliminary experience with the Rashkind occluder device. *J Intervent Cardiol* 1989;2:35–38.
89. Lock JE, Cockerham JT, Keane JF, Finley JP, Wakely PE, Fellows KE. Transcatheter umbrella closure of congenital cardiac defects. *Circulation* 1987;75:593–599.
90. Lock JE, Block PC, McKay RG, Baim DS, Keane JF. Transcatheter closure of ventricular septal defects. *Circulation* 1988;78:361–368.
91. Liu X, Stice JD. Shape-memory alloys and their applications. *J Appl Manufactur Syst* 1990;3:65–72.
92. Faella HJ, Hijazi ZM. Closure of the patent ductus arteriosus with the amplatzer PDA device: immediate results of the international clinical trial. *Catheter Cardiovasc Interv* 2000;51:50–54.
93. Masura J, Gavora P, Formanek A, Hijazi ZM. Transcatheter closure of secundum atrial septal defects using the new self-centering Amplatzer septal occluder: initial human experience. *Cathet Cardiovasc Diagn* 1997;42:388–393.
94. Sideris EB, Sideris SE, Fowlkes JP, Ehly RL, Smith JE, Gulde RE. Transvenous atrial septal defect occlusion in piglets with buttoned double disk device. *Circulation* 1990;81:312–318.
95. Sideris EB, Walsh KP, Haddad JL, Chen CR, Ren SG, Kulkarni H. Occlusion of congenital ventricular septal defects by the buttoned device. "Buttoned device" Clinical Trials International Register. *Heart* 1997;77(3):276–9.
96. van der Velde ME, Sanders SP, Keane JF, Perry SB, Lock JE. Transesophageal echocardiographic guidance of transcatheter ventricular septal defect closure. *J Am Coll Cardiol* 1994;23:1660–1665.
97. Kumar K, Lock JE, Geva T. Apical muscular ventricular septal defects between the left ventricle and the right ventricular infundibulum. Diagnostic and interventional considerations. *Circulation* 1997;95:1207–1213.

98. Lock JE, Rome JJ, Davis R, Van Praagh S, Perry SB, Van Praagh R, Keane JF. Transcatheter closure of atrial septal defects: experimental studies. *Circulation* 1989;79:1091–1099.
99. Lloyd TR, Fedderly R, Mendelsohn AM, Sandhu SK, Beekman RH 3rd. Transcatheter occlusion of patent ductus arteriosus with Gianturco coils. *Circulation* 1993;88:1412–20.
100. Latiff HA, Alwi M, Kandhavel G, et al. Transcatheter closure of multiple muscular ventricular septal defects using Gianturco coils. *Ann Thorac Surg* 1999; 68: 1400–1401.
101. Lock JE, Cockerham JT, Keane JF, Finley JP, Wakely PE, Fellows KE. Transcatheter umbrella closure of congenital cardiac defects. *Circulation* 1987;75:593–599.
102. Chessa M, Carminati M, Cao QL, Butera G, Giusti S, Bini RM, Hijazi ZM. Transcatheter closure of congenital and acquired muscular ventricular septal defects using the Amplatzer device. *J Invasive Cardiol*. 2002;14(6):322–327.
103. Thanopoulos BD, Karanassios E, Tsaousis G, Papadopoulos GS, Stefanadis C. Catheter closure of congenital/acquired muscular VSDs and perimembranous VSDs using the Amplatzer devices. *J Interv Cardiol*. 2003;16(5):399–407.
104. Carminati M, Butera G, Chessa M, Drago M, Negura D, Piazza L. Transcatheter closure of congenital ventricular septal defect with Amplatzer septal occluders. *Am J Cardiol*. 2005;96(12A):52L–58L.
105. Waight DJ, Bacha EA, Kahana M, Cao QL, Heitschmidt M, Hijazi ZM. Catheter therapy of Swiss cheese ventricular septal defects using the Amplatzer muscular VSD occluder. *Catheter Cardiovasc Interv*. 2002;55(3):355–361.
106. Amin Z, Gu X, Berry JM, Titus JL, Gidding SS, Rocchini AP. Percutaneous closure of ventricular septal defects without cardiopulmonary bypass. *Ann Thorac Surg*. 1999;68(1):149–153.

107. Bacha EA, Cao QL, Galantowicz ME, Cheatham JP, Fleishman CE, Weinstein SW, Becker PA, Hill SL, Koenig P, Alboliras E, Abdulla R, Starr JP, Hijazi ZM. Multicenter experience with periventricular device closure of muscular ventricular septal defects. *Pediatr Cardiol.* 2005;26(2):169–175.
108. Bacha EA, Cao QL, Starr JP, Waight D, Ebeid MR, Hijazi ZM. Periventricular device closure of muscular ventricular septal defects on the beating heart: technique and results. *J Thorac Cardiovasc Surg.* 2003;126(6):1718–1723.
109. Hijazi ZM, Hakim F, Haweleh AA, Madani A, Tarawna W, Hiari A, Cao QL. Catheter closure of perimembranous ventricular septal defects using the new Amplatzer membranous VSD occluder: initial clinical experience. *Catheter Cardiovasc Interv.* 2002;56(4):508–515.
110. Cao QL, Zabal C, Koenig P, Sandhu S, Hijazi ZM. Initial clinical experience with intracardiac echocardiography in guiding transcatheter closure of perimembranous ventricular septal defects: feasibility and comparison with transesophageal echocardiography. *Catheter Cardiovasc Interv.* 2005;66(2):258–267.
111. Thanopoulos BD, Tsaousis GS, Karanasios E, Eleftherakis NG, Paphitis C. Transcatheter closure of perimembranous ventricular septal defects with the Amplatzer asymmetric ventricular septal defect occluder: preliminary experience in children. *Heart.* 2003 Aug;89(8):918–922.
112. Fu YC, Bass J, Amin Z, Radtke W, Cheatham JP, Hellenbrand WE, Balzer D, Cao QL, Hijazi ZM. Transcatheter closure of perimembranous ventricular septal defects using the new Amplatzer membranous VSD occluder: results of the U.S. phase I trial. *J Am Coll Cardiol.* 2006;47(2):319–325.
113. Amin Z, Danford DA, Lof J, Duncan KF, Froemming S. Intraoperative device closure of perimembranous ventricular septal defects without cardiopulmonary bypass: preliminary results with the periventricular technique. *J Thorac Cardiovasc Surg.* 2004;127(1):234–241.

114. Amin Z, Woo R, Danford DA, Froemming SE, Reddy VM, Lof J, Overman D. Robotically assisted periventricular closure of perimembranous ventricular septal defects: preliminary results in Yucatan pigs. *J Thorac Cardiovasc Surg.* 2006;131(2):427–432.
115. Holzer R, Balzer D, Cao QL, Lock K and Hijazi ZM. Device closure of muscular ventricular septal defects using the Amplatzer Muscular Ventricular Septal Defect Occluder: immediate and mid-term results of a U.S. registry. *J Am Coll Cardiol* 2004;43:1257–1263.
116. Arora R, Trehan V, Thakur AK, Mehta V, Sengupta PP, Nigam M. Transcatheter closure of congenital muscular ventricular septal defect. *J Interv Cardiol.* 2004;17(2):109–115.
117. Yip WC, Zimmerman F, Hijazi ZM. Heart block and empirical therapy after transcatheter closure of perimembranous ventricular septal defect. *Catheter Cardiovasc Interv.* 2005;66(3):436–441.
118. Golden AB, Hellenbrand WE. Coarctation of the aorta: stenting in children and adults. *Catheter Cardiovasc Interv.* 2007 Feb 1;69(2):289–99.
119. Ringel RE, Gauvreau K, Moses H, Jenkins KJ. Coarctation of the Aorta Stent Trial (COAST): study design and rationale. *Am Heart J.* 2012 Jul;164(1):7–13.
120. Lock JE, Bass JL, Amplatz K, Fuhrman BP, Castaneda-Zuniga W. Balloon dilation angioplasty of aortic coarctations in infants and children. *Circulation* 1983 Jul;68(1):109–16.
121. Shaddy RE, Boucek MM, Sturtevant JE, Ruttenberg HD, Jaffe RB, Tani LY, et al. Comparison of angioplasty and surgery for unoperated coarctation of the aorta. *Circulation.* 1993 Mar;87(3):793–9.
122. Hager A, Schreiber C, Nutzl S, Hess J. Mortality and restenosis rate of surgical coarctation repair in infancy: a study of 191 patients. *Cardiology.* 2009;112(f1):36–41.

123. Rao PS, Galal O, Smith PA, Wilson AD. Five- to nine-year follow-up results of balloon angioplasty of native aortic coarctation in infants and children. *J Am Coll Cardiol.* 1996 Feb;27(2):462-70.
124. Morrow WR, Palmaz JC, Tio FO, Ehler WJ, VanDellen AF, Mullins CE. Re-expansion of balloon-expandable stents after growth. *J Am Coll Cardiol.* 1993 Dec;22(7):2007-13.
125. O'Laughlin MP, Perry SB, Lock JE, Mullins CE. Use of endovascular stents in congenital heart disease. *Circulation.* 1991 Jun;83(6):1923-39.
126. Weber HS, Cyran SE. Endovascular stenting for native coarctation of the aorta is an effective alternative to surgical intervention in older children. *Congenit Heart Dis.* 2008 Jan-Feb;3(1):54-9.
127. Qureshi AM, McElhinney DB, Lock JE, Landzberg MJ, Lang P, Marshall AC. Acute and intermediate outcomes, and evaluation of injury to the aortic wall, as based on 15 years experience of implanting stents to treat aortic coarctation. *Cardiol Young.* 2007 Jun;17(3):307-18.
128. Pedra C, Fontes V, Esteves C, et al. Use of covered stents in the management of coarctation of aorta. *PediatrCardiol* 2005;26:431-9.
129. Feltes TF, Bacha E, Beekman RH 3rd, et al. American Heart Association Congenital Cardiac Defects Committee of the Council on Cardiovascular Disease in the Young; Council on Clinical Cardiology; Council on Cardiovascular Radiology and Intervention. Indications for cardiac catheterization and intervention in pediatric cardiac disease: a scientific statement from the American Heart Association. *Circulation* 2011;123:2607-52.
130. Snider AR, Serwer GA, Ritter SB. Echocardiography in pediatric heart disease. 2nd edition. St Louis(MO): Mosby Year Book; 1997. Chapter 11, Coarctation of the aorta. p. 479-82.

131. Marshall AC, Perry SB, Keane JF, et al. Early results and medium-term follow-up of stent implantation for mild residual or recurrent aortic coarctation. *Am Heart J* 2000;139:1054-60.
132. Qureshi AM, McElhinney DB, Lock JE, et al. Acute and intermediate outcomes, and evaluation of injury to the aortic wall, as based on 15 year experience of implanting stents to treat aortic coarctation. *Cardiol Young* 2007;17:307-18.128 Bruckheimer & Pedra
133. Egan M, Holzer RJ. Comparing balloon angioplasty, stenting and surgery in the treatment of aortic coarctation. *Expert Rev Cardiovasc Ther* 2009;7:1401-12.
134. Pedra CA, Fontes VF, Esteves CA, et al. Stenting vs.balloon angioplasty for discrete unoperated coarctation of the aorta in adolescents and adults. *Catheter Cardiovasc Interv* 2005;64:495-506.
135. Forbes TJ, Kim DW, Du W, et al. Comparison of surgical, stent, and balloon angioplasty treatment of native coarctation of the aorta: an observational study by the CCISC (Congenital Cardiovascular Interventional Study Consortium). *J Am Coll Cardiol* 2011;58:2664-74.
136. Gunn J, Cleveland T, Gaines P. Covered stent to treat coexistent coarctation and aneurysm of the aorta in a young man. *Heart* 1999;82:351.
137. Kenny D, Margey R, Turner MS, et al. Self-expanding and balloon expandable covered stents in the treatment of aortic coarctation with or without aneurysm formation. *Catheter Cardiovasc Interv* 2008;72:65-71.
138. Singer MI, Rowen M, Dorsey TJ. Transluminal aortic balloon angioplasty for coarctation of the aorta in the newborn. *Am. Heart J.* 103, 131-132 (1982).
139. Fletcher SE, Nihill MR, Grifka RG *et al.* Balloon angioplasty of native coarctation of the aorta: midterm follow-up and prognostic factors. *J. Am. Coll. Cardiol.* 25, 730-734 (1995).

140. Maheshwari S, Bruckheimer E, Fahey JT, Hellenbrand WE. Balloon angioplasty of postsurgical recoarctation in infants: the risk of restenosis and long term follow-up. *J. Am. Coll. Cardiol.* 35, 209–213 (2000).
141. Ho SY, Somerville J, Yip WC *et al.* Transluminal balloon dilation of resected coarcted segments of thoracic aorta: histological study and clinical implications. *Int. J. Cardiol.* 19, 99–105 (1988).
142. Lock JE, Castaneda-Zuniga WR, Bass JL *et al.* Balloon dilatation of excised aortic coarctations. *Radiology* 143, 689–691 (1982).
143. Ino T, Kishiro M, Okubo M *et al.* Dilatation mechanism of balloon angioplasty in children; assessment by angiography and intravascular ultrasound. *Cardiovasc. Interv. Radiol.* 21, 102–108 (1998).
144. Qureshi A, McElhinney DB, Lock JE, Landszberg MJ, Lang P, Marshall AC. Acute and intermediate outcomes, and evaluation of injury to the aortic wall, as based on 15 years experience of implanting stents to treat aortic coarctation. *Cardiol. Young* 17, 307–318 (2007).
145. Rao PS, Galal O, Smith PA *et al.* Five- to nine-year follow-up results of balloon angioplasty of native aortic coarctation in infants and children. *J. Am. Coll. Cardiol.* 27, 462–470 (1996).
146. Fletcher SE, Nihill MR, Grifka RG *et al.* Balloon angioplasty of native coarctation of the aorta: midterm follow-up and prognostic factors. *J. Am. Coll. Cardiol.* 25, 730–734 (1995).
147. O’Laughlin MP, Ferry SB, Lock JE *et al.* Use of endovascular stents in congenital heart disease. *Circulation* 83, 1923–1939 (1991).
148. Magee AG, Brzezinska-Rajszyk G, Qureshi SA *et al.* Stent implantation for aortic coarctation and recoarctation. *Heart* 82, 600–606 (1999).
149. Rosenthal E, Qureshi SA, Tynan M. Stent implantation for aortic recoarctation. *Am. Heart J.* 129, 1220–1221 (1995).

150. Brili S, Dima I, Ioakeimidis N *et al.* Evaluation of aortic stiffness and wave reflections in patients after successful coarctation repair. *Eur. Heart J.* 26, 1394 (2005).
151. Suarez de Lezo J, Pan M, Romera M *et al.* Immediate and follow-up findings after stent treatment for severe coarctation of aorta. *Am. J. Cardiol.* 83, 400–406 (1999).
152. Qureshi SA, Zubrzycka M, Brzezinska-Rajszyk G *et al.* Use of covered Cheatham–Platinum stents in aortic coarctation and recoarctation. *Cardiol. Young* 14, 50–54 (2004).
153. Gunn J, Cleveland T, Gaines P. Covered stent to treat co-existent coarctation and aneurysm of the aorta in a young man. *Heart* 82, 351 (1999).
154. Forbes T, Matisoff D, Dysart J *et al.* Treatment of coexisting coarctation and aneurysm of the aorta with covered stent in a pediatric patient. *Pediatr. Cardiol.* 24, 289–291 (2003).
155. Sadiq M, Malick NH, Qureshi SA. Simultaneous treatment of native coarctation of the aorta combined with patent ductus arteriosus using a covered stent. *Catheter. Cardiovasc. Interv.* 59, 387–390 (2003).
156. Ewert P, Abdul-Khalid H, Peters B *et al.* Transcatheter therapy of long extreme subaortic aortic coarctation with covered stents. *Catheter. Cardiovasc. Interv.* 63, 236–239 (2004).
157. Bruckheimer E, Dagan T, Amir G, Birk E. Covered Cheatham–Platinum stents for serial dilation of severe native aortic coarctation. *Catheter. Cardiovasc. Interv.* 74(1), 117–123 (2009).
158. Kenny D, Cao QL, Kavinsky C, Hijazi ZM. Innovative resource utilization to fashion individualized covered stents in the setting of aortic coarctation. *Catheter. Cardiovasc. Interv.* 78(3), 413–418 (2011).

159. Kim Y, Choi JY, Lee JK, Sul JH, Lee SK, Park YH, et al. Mid-term result of the transcatheter occlusion of patent ductus arteriosus with Duct-Occlud device and procedure-related problems. *Korean J Pediatr.*2004;47:36-43
160. Transcatheter closure of patent ductus arteriosus using the Amplatzer duct occluder in children: initial and one-year results. Parra-Bravo JR, Cruz-Ramírez A, Toxqui-Terán A, Juan-Martínez E, Chávez-Fernández AA, Lazo-Cárdenas C, Beirana-Palencia L, Estrada-Flores J.
161. A Retrospective Study of 1,526 Cases of Transcatheter Occlusion of Patent Ductus Arteriosus. Jin M, Liang YM, Wang XF, Guo BJ, Zheng K, Gu Y, Lyu ZY.
162. [Advances in interventional occlusion of persistent ductus arteriosus: comparison of results using different occlusion devices]. Koch A, Hofbeck M, Buheitel G, Gerling S, Rauch R, Singer H.
163. Finding genetic contributions to sporadic disease: a recessive locus at 12q24 commonly contributes to patent ductus arteriosus. Mani A, Meraji SM, Houshyar R, Radhakrishnan J, Mani A, Ahangar M, Rezaie TM, Taghavinejad MA, Broumand B, Zhao H, Nelson-Williams C, Lifton RP.
164. Bouchta.N.Les cardiopathies congénitales avec shunt gauche-droite (a propos de 302 cas). Thèse Fès (N° 115/2011).
- 165 . Chaara.A., et al Aspects cliniques et paracliniques dans la PCA. *Maroc Médical*, 1984, 6, P: 307.160
166. Laraaki Etude épidémiologique des cardiopathies congénitales à propos de 445 cas, thèse de médecine, faculté de médecine et de pharmacie de Fès.
167. Bencherif Noufissa.Persistance du canal artériel : Thèse Rabat 1975.
168. Kettani Mounia.Persistance du canal artériel : Thèse Casa 1985.
169. Faik.M.Persistance du canal artériel a l'hôpital d'enfant de Rabat. Thèse de Rabat N°137 (2000).

170. Apetrei E, Vilciu E. Mecanofonocardiografie–ghidpractic. Editura Medicală; 1977. pp. 49–50.
171. Constant J. Essentials of Bedside Cardiology, second edition. Humana Press Inc; 2003. chapter 14; pp. 235–241
172. R. Elmamoun, la persistance du canal artériel, thèse Rabat 2010
173. Fortescue EB, Lock JE, Galvin T, McElhinney DB (2010) To close or not to close: the very small patent ductus arteriosus. *Congenit Heart Dis.* 5:354–365
174. Yifeng Yang, Transcatheter closure of atrial septal defects without fluoroscopy: A well-established procedure for alternative use in children, *EuroIntervention: journal of EuroPCR in collaboration with the Working Group on Interventional Cardiology of the European Society of Cardiology* 12(5):e652–e657
175. John F. Rhodes Jr., Combined Prospective United States Clinical Study Data for the GORE VR HELEX VR Septal Occluder Device, *Catheterization and Cardiovascular Interventions* 83:944–952 (2014)
176. Mario Carminati, Transcatheter closure of congenital ventricular septal defects: results of the European Registry, *European Heart Journal*, Volume 28, Issue 19, October 2007, Pages 2361–2368
177. Sahar El Shedoudy, Mid-term results of transcatheter closure of ventricular septal defect using Nit-Occlud LÊ ventricular septal defect coil, single-center experience, Department of Cardiology, Tanta University Hospitals
178. Baykan A, Karagöz T, Çeliker A. Endovascular stent implantation for coarctation of the aorta in children and young adults: intermediate follow-up results from Turkey. *Turk J Pediatr* 2009; 51: 116–119.
179. John P. Cheatham, Stenting of Coarctation of the Aorta, *Cathet Cardiovasc Intervent* 2001;54:112–125, 2001 Wiley-Liss, Inc.
180. Sara Bondanza, Early and Long-Term Results of Stent Implantation for Aortic Coarctation in Pediatric Patients Compared to Adolescents: A Single Center Experience, *Cardiology Research and Practice* Volume 2016, Article ID 4818307, 5 pages.



Royaume du Maroc المملكة المغربية

كلية الطب والصيدلة
+0521010101 | +012112121 8 +00000000
FACULTÉ DE MÉDECINE ET DE PHARMACIE

أطروحة رقم 20/023

سنة 2020

علاج القسرة التداخلي من أجل الإغلاق عن طريق الجلد للمهمات داخل القلب وتمدد احتقان الشريان الأورطي مع أو بدون دعائم (بصدد 127 حالة)

الأطروحة

قدمت و نوقشت علانية يوم 2019/12/23

من طرف

السيد نورالدين عمرو

المزاد في 1992/09/10 بالخليل - فلسطين

لنيل شهادة الدكتوراه في الطب

الكلمات الأساسية

القناة الشريانية السالكة - عيب الحاجز الأذيني - عيب الحاجز البطيني - تضيق في الشريان الأورطي - التشخيص - انسداد
بالون - أنجيوبلاستي - الدعائم Amplatzer Septal - مطهر Amplatzer - القطار مطبق القناة

اللجنة

الرئيس السيد المصطفى حيدة. أستاذ في علم أمراض الأطفال
المشرف السيد سمير عثمانى أستاذ في علم أمراض الأطفال
الأعضاء السيد مصطفى هرنودو أستاذ في لتخدير و الإنعاش
 السيد المصطفى الكواش أستاذ في علم التشريح
 السيد محمد عدنان بردعي أستاذ مبرز في التخدير و الإنعاش