



كلية الطب
والصيدلة - مراكش
FACULTÉ DE MÉDECINE
ET DE PHARMACIE - MARRAKECH

Year 2021

Thesis N° 215

Outcome following the detachment of the tricuspid valve for ventricular septal defects closure

THESIS

PRESENTED AND DEFENDED PUBLICLY ON 02/12/2021

BY

Mr. Ascension Igor RANGUZA

Born on May 28 1992 in Burundi

TO OBTAIN A MEDICAL DOCTORATE

KEYWORDS

Detachment-Tricuspid valve-Ventricular septal defect- Outcome

JURY

Mrs.	N. EL IDRISSE SLITINE Professor of Paediatrics	CHAIRPERSON
Mr.	D. BOUMZEBRA Professor Head of Cardiovascular Surgery Unit	SUPERVISOR
Mr.	R. EL HAOUATI Associate Professor of Cardiovascular Surgery	JUDGE



HIPPOCRATIC OATH

At the time of being admitted as a member of the medical profession:

*I solemnly pledge to dedicate my life to the service of humanity;
the health and well-being of my patient will be my first consideration;*

I will respect the autonomy and dignity of my patient;

I will maintain the utmost respect for human life;

*I will not permit considerations of age, disease or disability, greed,
ethnic origin, gender, nationality, political affiliation, race, sexual
orientation, social standing or any other factor to intervene between my
duty and my patient;*

*I will respect the secrets that are confided in me, even after the patient
has died;*

*I will practice my profession with conscience and dignity and in
accordance with good medical practices;*

I will foster the honour and noble traditions of the medical profession;

*I will give to my teachers, colleagues, and students the respect and
gratitude that is their due*

*I will share my medical knowledge for the benefit of the patient and
the advancement of healthcare;*

*I will attend to my health, well-being, and abilities in order to
provide care of the highest standard;*

*I will not use my medical knowledge to violate human rights and civil
liberties, even under threat;*

I make these promises solemnly, freely and upon my honour.

Declaration of Geneva, 1948



*LIST OF
PROFESSORS*



UNIVERSITE CADI AYYAD
FACULTE DE MEDECINE ET DE PHARMACIE
MARRAKECH

Doyens Honoraires

: Pr. Badie Azzaman MEHADJI
: Pr. Abdelhaq ALAOUI YAZIDI

ADMINISTRATION

Doyen

: Pr. Mohammed BOUSKRAOUI

Vice doyen à la Recherche et la Coopération

: Pr. Mohamed AMINE

Vice doyen aux Affaires Pédagogiques

: Pr. Redouane EL FEZZAZI

Secrétaire Générale

: Mr. Azzeddine EL HOUDAIGUI

Professeurs de l'enseignement supérieur

Nom et Prénom	Spécialité	Nom et Prénom	Spécialité
ABKARI Imad	Traumato- orthopédie	ESSAADOUNI Lamiaa	Médecine interne
ABOU EL HASSAN Taoufik	Anésthésie- réanimation	FADILI Wafaa	Néphrologie
ABOUCHADI Abdeljalil	Stomatologie et chir maxillo faciale	FAKHIR Bouchra	Gynécologie- obstétrique
ABOULFALAH Abderrahim	Gynécologie- obstétrique	FOURAIJI Karima	Chirurgie pédiatrique
ABOUSSAIR Nisrine	Génétique	GHANNANE Houssine	Neurochirurgie
ADALI Imane	Psychiatrie	GHOUNDALE Omar	Urologie
ADMOU Brahim	Immunologie	HACHIMI Abdelhamid	Réanimation médicale
AGHOUTANE EI Mouhtadi	Chirurgie pédiatrique	HAJJI Ibtissam	Ophtalmologie
AISSAOUI Younes	Anesthésie - réanimation	HAROU Karam	Gynécologie- obstétrique
AIT AMEUR Mustapha	Hématologie Biologique	HOCAR Ouafa	Dermatologie
AIT BENALI Said	Neurochirurgie	JALAL Hicham	Radiologie
AIT BENKADDOUR Yassir	Gynécologie- obstétrique	KAMILI EI Ouafi EI Aouni	Chirurgie pédiatrique
AIT-SAB Imane	Pédiatrie	KHALLOUKI Mohammed	Anesthésie- réanimation
ALJ Soumaya	Radiologie	KHATOURI Ali	Cardiologie
AMAL Said	Dermatologie	KHOUCHANI Mouna	Radiothérapie
AMINE Mohamed	Epidémiologie- clinique	KISSANI Najib	Neurologie
AMMAR Haddou	Oto-rhino-laryngologie	KRATI Khadija	Gastro- entérologie
AMRO Lamyae	Pneumo- phtisiologie	KRIET Mohamed	Ophtalmologie
ANIBA Khalid	Neurochirurgie	LAGHMARI Mehdi	Neurochirurgie
ARSALANE Lamiae	Microbiologie -Virologie	LAKMICHY Mohamed Amine	Urologie
ASMOUKI Hamid	Gynécologie- obstétrique	LAOUAD Inass	Néphrologie

ATMANE El Mehdi	Radiologie	LOUHAB Nisrine	Neurologie
BAIZRI Hicham	Endocrinologie et maladies métaboliques	LOUZI Abdelouahed	Chirurgie – générale
BASRAOUI Dounia	Radiologie	MADHAR Si Mohamed	Traumato- orthopédie
BASSIR Ahlam	Gynécologie- obstétrique	MANOUDI Fatiha	Psychiatrie
BELBARAKA Rhizlane	Oncologie médicale	MANSOURI Nadia	Stomatologie et chiru maxillo faciale
BELKHOU Ahlam	Rhumatologie	MAOULAININE Fadl mrabih rabou	Pédiatrie (Neonatalogie)
BEN DRISS Laila	Cardiologie	MATRANE Aboubakr	Médecine nucléaire
BENALI Abdeslam	Psychiatrie	MOUAFFAK Youssef	Anesthésie – réanimation
BENCHAMKHA Yassine	Chirurgie réparatrice et plastique	MOUDOUNI Said Mohammed	Urologie
BENELKHAÏAT BENOMAR Ridouan	Chirurgie – générale	MOUFID Kamal	Urologie
BENHIMA Mohamed Amine	Traumatologie – orthopédie	MOUTAJ Redouane	Parasitologie
BENJILALI Laila	Médecine interne	MOUTAOUAKIL Abdeljalil	Ophthalmologie
BENZAROUËL Dounia	Cardiologie	MSOUGGAR Yassine	Chirurgie thoracique
BOUCHENTOUF Rachid	Pneumo- phtisiologie	NAJEB Youssef	Traumato- orthopédie
BOUKHANNI Lahcen	Gynécologie- obstétrique	NARJISS Youssef	Chirurgie générale
BOUKHIRA Abderrahman	Biochimie – chimie	NEJMI Hicham	Anesthésie- réanimation
BOUMZEBRA Drissi	Chirurgie Cardio- Vasculaire	NIAMANE Radouane	Rhumatologie
BOURRAHOÛAT Aïcha	Pédiatrie	OUALI IDRÏSSI Mariem	Radiologie
BOURROUS Monir	Pédiatrie	OUBAHA Sofia	Physiologie
BOUSKRAOÛI Mohammed	Pédiatrie	OULAD SAIAD Mohamed	Chirurgie pédiatrique
CHAFIK Rachid	Traumato- orthopédie	QACIF Hassan	Médecine interne
CHAKOUR Mohamed	Hématologie Biologique	QAMOÛSS Youssef	Anesthésie- réanimation
CHELLAK Saliha	Biochimie- chimie	RABBANI Khalid	Chirurgie générale
CHERIF IDRÏSSI EL GANOUNI Najat	Radiologie	RADA Nouredine	Pédiatrie
CHOULLI Mohamed Khaled	Neuro pharmacologie	RAIS Hanane	Anatomie pathologique
DAHAMI Zakaria	Urologie	RAJI Abdelaziz	Oto-rhino-laryngologie
DRAÏSS Ghizlane	Pédiatrie	ROCHDI Youssef	Oto-rhino-laryngologie

EL ADIB Ahmed Rhassane	Anesthésie- réanimation	SAMKAOUI Mohamed Abdenasser	Anesthésie- réanimation
EL AMRANI Moulay Driss	Anatomie	SAMLANI Zouhour	Gastro- entérologie
EL ANSARI Nawal	Endocrinologie et maladies métaboliques	SARF Ismail	Urologie
EL BARNI Rachid	Chirurgie- générale	SORAA Nabila	Microbiologie - Virologie
EL BOUCHTI Imane	Rhumatologie	SOUMMANI Abderraouf	Gynécologie- obstétrique
EL BOUIHI Mohamed	Stomatologie et chir maxillo faciale	TASSI Noura	Maladies infectieuses
EL FEZZAZI Redouane	Chirurgie pédiatrique	TAZI Mohamed Ilias	Hématologie- clinique
EL HAOURY Hanane	Traumato- orthopédie	YOUNOUS Said	Anesthésie- réanimation
EL HATTAOUI Mustapha	Cardiologie	ZAHLANE Kawtar	Microbiologie - virologie
EL HOUDZI Jamila	Pédiatrie	ZAHLANE Mouna	Médecine interne
EL IDRISSE SLITINE Nadia	Pédiatrie	ZAOUI Sanaa	Pharmacologie
EL KARIMI Saloua	Cardiologie	ZIADI Amra	Anesthésie - réanimation
EL KHAYARI Mina	Réanimation médicale	ZOUHAIR Said	Microbiologie
EL MGHARI TABIB Ghizlane	Endocrinologie et maladies métaboliques	ZYANI Mohammed	Médecine interne
ELFIKRI Abdelghani	Radiologie		

Professeurs Agrégés

Nom et Prénom	Spécialité	Nom et Prénom	Spécialité
ABIR Badreddine	Stomatologie et Chirurgie maxillo faciale	GHAZI Mirieme	Rhumatologie
ADARMOUCH Latifa	Médecine Communautaire (médecine préventive, santé publique et hygiène)	HAZMIRI Fatima Ezzahra	Histologie- embyologie cytogénétique
AIT BATAHAR Salma	Pneumo- phtisiologie	IHBIBANE fatima	Maladies Infectieuses
ARABI Hafid	Médecine physique et réadaptation fonctionnelle	KADDOURI Said	Médecine interne
ARSALANE Adil	Chirurgie Thoracique	LAHKIM Mohammed	Chirurgie générale
BELBACHIR Anass	Anatomie- pathologique	LAKOUICHMI Mohammed	Stomatologie et Chirurgie maxillo faciale
BELHADJ Ayoub	Anesthésie -Réanimation	MARGAD Omar	Traumatologie - orthopédie
BENJELLOUN HARZIMI Amine	Pneumo- phtisiologie	MLIHA TOUATI Mohammed	Oto- Rhino - Laryngologie
BOUZERDA Abdelmajid	Cardiologie	MOUHSINE Abdelilah	Radiologie

BSISS Mohamed Aziz	Biophysique	NADER Youssef	Traumatologie - orthopédie
CHRAA Mohamed	Physiologie	SALAMA Tarik	Chirurgie pédiatrique
DAROUASSI Youssef	Oto-Rhino - Laryngologie	SEDDIKI Rachid	Anesthésie - Réanimation
EL HAOUATI Rachid	Chirurgie Cardio-vasculaire	SERGHINI Issam	Anesthésie - Réanimation
EL KAMOUNI Youssef	Microbiologie Virologie	TOURABI Khalid	Chirurgie réparatrice et plastique
EL KHADER Ahmed	Chirurgie générale	ZARROUKI Youssef	Anesthésie - Réanimation
EL MEZOUARI El Moustafa	Parasitologie Mycologie	ZEMRAOUI Nadir	Néphrologie
EL OMRANI Abdelhamid	Radiothérapie	ZIDANE Moulay Abdelfettah	Chirurgie thoracique
FAKHRI Anass	Histologie- embryologie cytogénétique		

Professeurs Assistants

Nom et Prénom	Spécialité	Nom et Prénom	Spécialité
AABBASSI Bouchra	Pédopsychiatrie	ESSADI Ismail	Oncologie Médicale
ABALLA Najoua	Chirurgie pédiatrique	FASSI FIHRI Mohamed jawad	Chirurgie générale
ABDELFETTAH Youness	Rééducation et Réhabilitation Fonctionnelle	FDIL Naima	Chimie de Coordination Bio- organique
ABDOU Abdessamad	Chiru Cardio vasculaire	FENNANE Hicham	Chirurgie Thoracique
ABOULMAKARIM Siham	Biochimie	HAJHOUI Farouk	Neurochirurgie
ACHKOUN Abdessalam	Anatomie	HAJJI Fouad	Urologie
AIT ERRAMI Adil	Gastro-entérologie	HAMMI Salah Eddine	Médecine interne
AKKA Rachid	Gastro - entérologie	Hammoune Nabil	Radiologie
ALAOUI Hassan	Anesthésie - Réanimation	HAMRI Asma	Chirurgie Générale
ALJALIL Abdelfettah	Oto-rhino-laryngologie	HAZIME Raja	Immunologie
AMINE Abdellah	Cardiologie	JALLAL Hamid	Cardiologie
ARROB Adil	Chirurgie réparatrice et plastique	JANAH Hicham	Pneumo- phtisiologie
ASSERRAJI Mohammed	Néphrologie	LAFFINTI Mahmoud Amine	Psychiatrie
AZAMI Mohamed Amine	Anatomie pathologique	LAHLIMI Fatima Ezzahra	Hématologie clinique
AZIZ Zakaria	Stomatologie et chirurgie maxillo faciale	LAHMINI Widad	Pédiatrie
BAALLAL Hassan	Neurochirurgie	LALYA Issam	Radiothérapie
BABA Hicham	Chirurgie générale	LAMRANI HANCH Asmae	Microbiologie-virologie
BELARBI Marouane	Néphrologie	LOQMAN Souad	Microbiologie et toxicologie environnementale

BELFQUIH Hatim	Neurochirurgie	MAOUJOURD Omar	Néphrologie
BELGHMAIDI Sarah	Ophtalmologie	MEFTAH Azzelarab	Endocrinologie et maladies métaboliques
BELLASRI Salah	Radiologie	MESSAOUDI Redouane	Ophtalmologie
BENANTAR Lamia	Neurochirurgie	MILOUDI Mohcine	Microbiologie – Virologie
BENCHAFAI Ilias	Oto-rhino-laryngologie	MOUGUI Ahmed	Rhumatologie
BENNAOUI Fatiha	Pédiatrie	NASSIH Houda	Pédiatrie
BENZALIM Meriam	Radiologie	NASSIM SABAH Taoufik	Chirurgie Réparatrice et Plastique
BOUTAKIOUTE Badr	Radiologie	OUERIAGLI NABIH Fadoua	Psychiatrie
CHAHBI Zakaria	Maladies infectieuses	OUMERZOUK Jawad	Neurologie
CHEGGOUR Mouna	Biochimie	RAGGABI Amine	Neurologie
CHETOUI Abdelkhalek	Cardiologie	RAISSI Abderrahim	Hématologie clinique
CHETTATI Mariam	Néphrologie	REBAHI Houssam	Anesthésie – Réanimation
DAMI Abdallah	Médecine Légale	RHARRASSI Isam	Anatomie-patologique
DARFAOUI Mouna	Radiothérapie	RHEZALI Manal	Anesthésie-réanimation
DOUIREK Fouzia	Anesthésie- réanimation	ROUKHSI Redouane	Radiologie
EL- AKHIRI Mohammed	Oto- rhino- laryngologie	SAHRAOUI Houssam Eddine	Anesthésie-réanimation
EL AMIRI My Ahmed	Chimie de Coordination bio-organnique	SALLAHI Hicham	Traumatologie-orthopédie
EL FADLI Mohammed	Oncologie médicale	SAYAGH Sanae	Hématologie
EL FAKIRI Karima	Pédiatrie	SBAAI Mohammed	Parasitologie-mycologie
EL GAMRANI Younes	Gastro-entérologie	SBAI Asma	Informatique
EL HAKKOUNI Awatif	Parasitologie mycologie	SEBBANI Majda	Médecine Communautaire (médecine préventive, santé publique et hygiène)
EL JADI Hamza	Endocrinologie et maladies métaboliques	SIRBOU Rachid	Médecine d'urgence et de catastrophe
EL KHASSOUI Amine	Chirurgie pédiatrique	SLIOUI Badr	Radiologie
ELATIQI Oumkeltoum	Chirurgie réparatrice et plastique	WARDA Karima	Microbiologie
ELBAZ Meriem	Pédiatrie	YAHYAOUI Hicham	Hématologie
ELJAMILI Mohammed	Cardiologie	ZBITOU Mohamed Anas	Cardiologie
ELOUARDI Youssef	Anesthésie réanimation	ZOUIITA Btissam	Radiologie
EL-QADIRY Rabiyy	Pédiatrie	ZOUIZRA Zahira	Chirurgie Cardio-vasculaire

LISTE ARRÊTÉE LE 23/06/2021



DEDICATIONS





I dedicate this thesis to ...

To my loving mother NIZIGIYIMANA Libérate

You are the corner stone of my life, the closest person to my heart. I cannot find words strong enough to express the depth of my love. I owe you every achievement that I have ever made in my life. May the almighty God bless you with a good health and a very long life.

To my loving father RANGUZA Ignace

Thanks for raising me as an honest, loyal and intellectual man. And for all the values of "ubuntu" that you passed through me.

To my lovely sisters Ange, Alda and my dear brother Jérôme

I will always hold you close in my heart. Thank you for your love and your tenderness.

To my dear aunt ITANGISHAKA Sylvie

Thank you for your unconditional love and support my dear "mama mudogo".

To all my uncles, aunts and cousins

Thank you for always being there for me with a special thought for those who left us for a better world.

To mister CAUQUIL Michel

Thank you for being like a second parent for me. And thank you for showing me the actual values of a Christian life.

To father Thaddeus MUSAS KAPEND o.f.m.

I will always be grateful for your kindness towards me and for providing me a quiet and cosy place to work on my thesis. And to the Franciscan community in Marrakech as well.

To all my friends of the Holy Martyr's parish in Marrakech

Special thoughts for NYAMBALAMOPEPE, LANGUIE Boris, Louise, Honorine, Annick and all current and past members of the liturgic group and the choir. I have found a true family here. I am grateful for the good times we spent together and the nice comradeship we shared.

To my fellow compatriots

Mr SHURWERYIMANA, Dr Germaine, Mr MUSHEMEZE, miss Sandrine, Mr MUGANI and all Burundians living and working in Morocco. We stayed united and solidary through thick and thin bounded together by our common love to our homeland.

To my fellow colleagues and friends

To Dr AKOUETE, Dr VIEIRA INSUMBO, Dr NEZA, Dr TCHIO, Dr BOANIMBEK, Dr AGBAKOU, Dr NTINI LEBI, Dr AGBAVITOR, Dr DIOUF, Dr BITEYE and all fellow foreign students who trained with me at different periods at the Marrakech Medicine Faculty. We shared together this journey and I will always be thankful for your mentorship, advices and solidarity.

To my classmates

Dr RAMI Mohammed, Dr SEYIDI Mustafa, Dr OUZOUHOU Soufiane, Dr HADDIRI Mehdi, Dr HALLOUMI Omar and all my other classmates. I am very thankful for helping me all those years to communicate with patients and to build bridges between our culture and religion. And for all the joys and hurdles we shared all this time.

To my closest friends

Special thoughts for Mr RUMURI Berny, miss Kiden WANI, Mr DEMOKARASI Ange, miss Greta, Mr MOUSSOUKOULA Ben-Zevy, Mr & Mrs MANÉ, Mr HAKASSOU Antoine, and all my other friends. I cannot imagine what my life would look like without your friendship and care.

Pr. ZOUIZRA, Dr Issaka

I am very grateful for your crucial and decisive help in the build-up of this thesis and for being the first who called up my attention to this subject. I owe you a lot.

Dr Mouhcine EL MARDOULI

I will always be thankful for your help in editing my thesis and for the Arabic translation of the abstract. Thank you for your assistance sir.

*Dr NIJIMBERE Macédoine, Dr KANE, Siham, Khadija, Sanaa and all
the cardiovascular surgery department*

*Thank You for your constant and patient assistance throughout the
making of this thesis.*

*To all my relatives, friends, neighbours, colleagues, classmates from
kindergarten to university and all the people whom I crossed paths with
and that I unwillingly have not cite namely.*

*Thank you and may the Almighty God bless you and may you keep
thriving in your lives.*



ACKNOWLEDGEMENTS



Pr. Nadia EL IDRISSE SLITINE

I was moved by your passion and commitment while attending your classes. And even though I did not have the opportunity to interne in your department, I admire your dedication towards your patients. I am very thankful that you concurred to preside over the jury of this thesis.

Thank you, Professor.

Pr. Drissi BOUMZEBRA

It is an utmost honour to have worked under the supervision of the great surgeon, great physician and above all the great person that you are. You are such an inspiring model that I would like to emulate with all my

heart and strength.

Thank you, sir.

Pr. Rachid EL HAOUATI

It is a singular honour for us that you agreed to be a member of this honourable jury. Allow me professor, to express my humble admiration of your human, professional qualities and your high sense of duty.

Thank you, sir.

And to all those who, one way or another, played an active role in the elaboration of this thesis. Please allow me to express my deepest and everlasting gratitude.



FIGURES



List of figures

- Figure 1** : Intraoperative picture showing the chordae insertion on the anterior margin of the VSD after exposure of the right atrium
- Figure 2** : Drawing of a VSD
- Figure 3** : Saline pressure testing of the tricuspid valve shows a competent valve
- Figure 4** : Age distribution of our patients
- Figure 5** : Gender distribution of our patients
- Figure 6** : Heart failure in our case series
- Figure 7** : Heart murmur distribution in our series
- Figure 8** : Type of VSD in our case series
- Figure 9** : VSD diameter in our series
- Figure 10** : Associated cardiac defects in our case series
- Figure 11** : Distribution of our patients by the grade of preoperative TR
- Figure 12** : Distribution of pulmonary Hypertension in our case series
- Figure 13** : Intraoperative assessment of VSD Type in our study
- Figure 14** : Perioperative Associated cardiac defects in our case series
- Figure 15** : Type of TVD performed in our case series
- Figure 16** : Type of patch used for the closure of the VSD in our case series
- Figure 17** : Additional procedures in our case series
- Figure 18** : Surgery aftermath in our case series
- Figure 19** : Occurrence of Residual VSD before discharge in our case series
- Figure 20** : Occurrence of Tricuspid Regurgitation before discharge in our case series
- Figure 21** : Occurrence of Residual VSD at 6 months follow up in our case series
- Figure 22** : Occurrence of Tricuspid Regurgitation at 6 months follow up in our case series
- Figure 23** : Occurrence of Residual VSD at long-term follow up in our case series
- Figure 24** : Occurrence of Tricuspid Regurgitation at long-term follow up in our case series
- Figure 25** : Picture of the interventricular septum seen from the right ventricle
- Figure 26** : Perimembranous VSD with chordae attachments obscuring its rims
- Figure 27** : Partial detachment of the septal leaflet extended to the anterior leaflet
- Figure 28** : Comparison between the levels of preoperative and postoperative TR



LIST OF TABLES



List of tables

Table I	: Age distribution of our patients
Table II	: Medical history in our case series
Table III	: Breastfeeding tiredness and dyspnea in our case series
Table IV	: Clinical signs prevalence in our case series
Table V	: ECG assessment in our case series
Table VI	: Associated cardiac defects in our case series
Table VII	: Distribution of our patients by the grade of preoperative TR
Table VIII	: Perioperative Associated cardiac defects in our case series
Table IX	: Additional procedures in our case series
Table X	: Age of patients (Literature review)
Table XI	: Gender distribution of patients (Literature review)
Table XII	: Percentage of patients with perimembranous VSD
Table XIII	: Mean CPB time in various studies
Table XIV	: Percentage of patients with no residual VSD and small, non-significant one
Table XV	: Percentage of patients with more than mild TR (Literature review)
Table XVI	: Number of patients with complete heart block



ABBREVIATIONS



Abbreviations List

ASD	: Atrial septal defect
AV	: Atrio-ventricular
AVB	: Atrioventricular block
CPB	: Cardiopulmonary bypass
HF	: Heart failure
ICU	: Intensive care unit
LVH	: Left ventricular hypertrophy
NYHA	: New York Heart Association
PDA	: Patent ductus arteriosus
PS	: Pulmonary stenosis
RSR	: Regular sinus rhythm
RVH	: Right ventricular hypertrophy
SD	: Standard deviation
TOF	: Tetralogy of Fallot
TR	: Tricuspid regurgitation
TV	: Tricuspid valve
TVD	: Tricuspid valve detachment
VSD	: Ventricular septal defect



OUTLINE



INTRODUCTION	1
PATIENTS AND METHODS	4
I. STUDY DESIGN.....	5
1. Type of study.....	5
2. Duration of the study.....	5
3. Setting.....	5
4. Follow-Up.....	6
II. METHODS.....	6
1. Inclusion criteria.....	6
2. Exclusion criteria.....	6
3. Data collection.....	6
4. Statistical analysis.....	7
III. OPERATIVE TECHNIQUE AND TVD INDICATIONS.....	7
IV. ETHICAL CONSIDERATIONS.....	10
RESULTS	11
I. EPIDEMIOLOGY.....	12
1. Age.....	12
2. Gender.....	12
II. CLINICAL DATA.....	13
1. Case History.....	13
2. Functional Symptoms.....	14
3. Physical Symptoms.....	15
III. PARACLINICAL DATA.....	16
1. Electrocardiogram.....	16
2. Echocardiographic Data.....	17
IV. SURGICAL TREATMENT.....	21
1. Intraoperative assessment.....	21
2. Surgical Procedures.....	23
V. POSTOPERATIVE EVOLUTION.....	25
1. Immediate postoperative aftermath.....	25
2. Postoperative assessment before discharge.....	27
3. Postoperative assessment at 6 months follow-up.....	28
4. Long term follow-up assessment.....	30
DISCUSSION	33
I. AGE AND GENDER.....	37
1. Age.....	37
2. Gender.....	38
II. TYPE OF VSD.....	38
III. CARDIOPULMONARY BYPASS AND AORTIC CROSS-CLAMP TIME.....	39
IV. RESIDUAL VSD.....	40
V. TRICUSPID REGURGITATION.....	41

VI. COMPLETE HEART BLOCK.....	43
VII. LIMITATIONS OF OUR STUDY.....	44
CONCLUSION.....	45
ANNEX.....	47
ABSTRACTS.....	52
REFERENCES.....	59



INTRODUCTION



The ventricular septal defect (VSD) is a congenital malformation where there is a defect in the ventricular septum of the heart. The VSDs are the most common congenital structural heart disease, accounting for 30 to 40 % of all congenital heart diseases and 0.8 % of all live births [1]. They can be either isolated, associated with other congenital heart malformations, or a component of a more complex heart malformation such as the Tetralogy of Fallot (TOF).

Their diagnosis is easily and accurately performed by the transthoracic echocardiography coupled with the colour Doppler.

A significant number of VSD cases, depending on their size and location, may close spontaneously. However, if a spontaneous closure does not happen, either a surgical or a percutaneous device closure treatment is required in order to prevent complications such as heart failure, infective endocarditis, aortic regurgitation and pulmonary hypertension which is a corollary of the left-to-right shunt.

During the surgical treatment, the transatrial approach is nowadays the gold standard since it generates less scarring of the right ventricle and less risk of right bundle branch block than the right ventricular one.

In some cases, mostly in perimembranous and muscular infundibular VSDs, the sub-valvular apparatus of the tricuspid valve (TV) conceals the margins of the VSD.

Hence an inadequate exposure of the VSD which both carries a high risk of damage to the conduction system, injury of the tricuspid valve, residual leaks and makes it difficult for surgeons to establish suture lines if they undertake the surgery without addressing it.

Furthermore, in case of outlet extension of the VSD in an upper position, exerting too much traction on the TV will result in the distortion of the TV or the elongation of the chordae, hence generating a tricuspid regurgitation.

Therefore, in order to allow both an optimal exposure of the VSD, an easier access to the VSD and avoid a distortion of the tricuspid valve; a partial detachment of the tricuspid valve is required.

The partial detachment of the tricuspid valve from the annulus during a VSD closure was first described by Hudspeth et al in 1962[2]. Since then, this technique has been further improved and even extended to closure of VSDs in patients with more-complex malformations such as the TOF [3].

Some surgeons have even developed and started performing variants of this technique: either a radial incision of the septal leaflet or a partial detachment of the chordae from their septal attachments and flipping them over [4].

Yet despite numerous studies in favor of its safety and efficacy, there are surgeons still restraining themselves from using this technique over concerns that it may increase the risk of heart block, tricuspid valve regurgitation and longer operation time [5].

The purpose of this endeavour is to assess the long-term outcomes of the patients who underwent a surgical closure of their VSD with a tricuspid valve detachment (TVD) in the cardiovascular surgery department of the Mohammed VI teaching hospital; by mainly focusing on the following elements:

- The frequency of residual VSDs.
- The frequency and severity of the tricuspid regurgitation at long-term.
- The occurrence of complete atrio-ventricular blocks.



*PATIENTS
AND METHODS*



I. STUDY DESIGN

1. Type of study

We undertook a retrospective, single center and descriptive study of the preoperative, intraoperative and follow up data of 28 patients who underwent surgery for VSD closure using the TVD technique.

2. Duration of the study

The study spanned on a period of 10 years from July 2010 to August 2020.

3. Setting

The study took place in the Cardiovascular Surgery department, Arrazi Hospital, Mohammed VI University Teaching Medical Center.

Both the preoperative and postoperative follow-up echocardiographic assessment were performed by the cardiovascular medicine department of Mohammed VI University Teaching Medical Center.

The severity of TR was assessed by applying the qualitative and semiquantitative variables [6]:

- Qualitative variables included: the size of the jet area flow (small, moderate, or large); the convergence of the jet area flow (transient, intermediate and large); and the density of the jet area flow (partial/dense, parabolic, or triangular).
- Semiquantitative variables included the state of the vena contracta (mild, <0.5cm; moderate, 0.3 to 0.69cm; or severe, >0.9cm), and hepatic vein flow (systolic dominance, systolic blunting, or systolic flow reversal).

4. Follow-Up

All the patients underwent consultations at 30 postoperative days, at 3 months, at 6 months, and at 12 months. Then, they were seen annually for a maximum of 8 years.

II. METHODS

1. Inclusion criteria

The following inclusion criteria were set up:

- Patients who underwent surgery for isolated VSDs or VSDs associated with either ASD, PDA, or PS with a partial detachment of the septal leaflet extended or not to the anterior one.
- Patients who underwent a complete repair surgery of TOF during which the VSD was closed with partial TVD.
- Patients with at least 6 months follow-up data.

2. Exclusion criteria

The exclusion criteria were the following ones:

- Patients with very complex heart malformations such as complete atrioventricular defect or double output right ventricle.
- Patients lost to follow-up.
- Patients with unusable or lost medical records.

3. Data collection

- The preoperative data (epidemiology, medical and surgical history, clinical exams, paraclinical data) were provided by a thorough review of medical records in the cardiovascular surgery department archives.

- The follow-up data was provided by the records of outpatient follow-up consultations, gathered either directly from the patients or sent by phone instant messaging applications; due to the coronavirus pandemic context.
- The data from each patient was recorded in a patient information sheet required to perform our study. (Check in the appendices).

4. Statistical analysis

We recorded the collected data using Microsoft Excel 2016 version.

- The data analysis was performed using SPSS 21.0 version.
- Continuous variables were presented as mean \pm standard deviation, range, as mostly appropriate. Categorical data were presented as number of patients and relative percentage.

III. OPERATIVE TECHNIQUE AND TVD INDICATIONS

The surgical approach used for closing the VSD for all the patients in our series was via a right atriotomy.

First, the mediastinal access was achieved through a midline sternotomy (and partial or total thymectomy); followed by an inverted T pericardiotomy and its suspension.

For 2 (7.1%) of our patients who had a PDA, it was closed at this stage.

Then the CPB was established in a standard manner by an aorta-bicaval cannulation following heparinization. The CPB was conducted at mild hypothermia. A left atrial vent was inserted in the right superior pulmonary vein after the aortic cross clamping.

Diastolic arrest was achieved by an infusion of cold and antegrade blood cardioplegia into the aortic root every 25 minutes.

Therefore, with both total CPB and caval vein isolation, the right atrium was opened parallel to the atrioventricular groove.

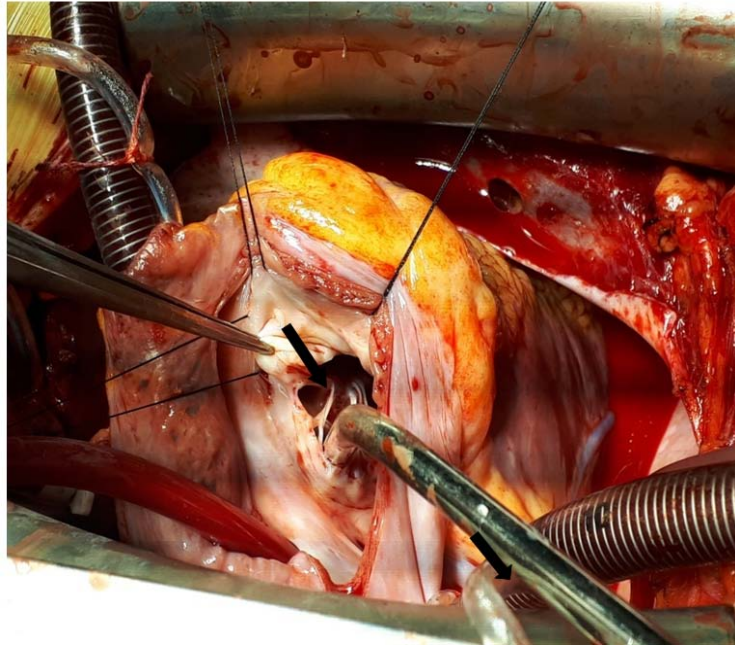


Figure 1: Intraoperative picture showing the chordae insertion (black arrow) on the anterior margin of the VSD after exposure of the right atrium / Cardiovascular Surgery Department – University hospital Mohammed VI – Marrakech

Then the VSD was fully exposed by retracting the anterior leaflet towards the right atrium appendage. The decision to perform a TVD was taken at this stage whenever the following circumstances arose:

- Chordal attachments of the tricuspid valve obscuring the margins of the defect.
- Aneurysm of the tricuspid valve disallowing an easy access to the defect.
- Upper position of the defect generating an excessive traction on the tricuspid valve leaflet.

The procedure continued by the partial detachment of the septal leaflet with an extension to the anterior one. The detachment is performed 2 to 3 mm away from the TV annulus in order to ease the further reattachment.

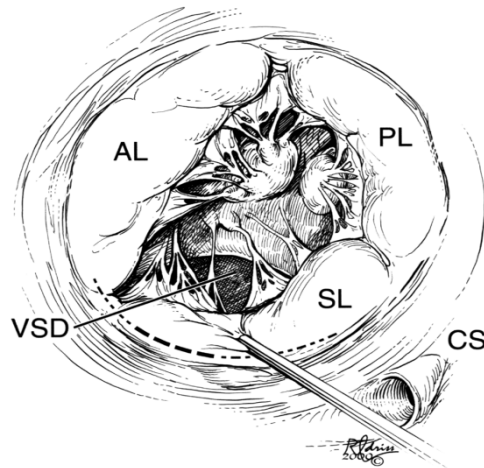


Figure 2: Drawing of a VSD. The dotted line is the site of the septal incision performed 2–3 mm away from the annulus. The incision is extended to the anterior leaflet [7].

No marking sutures for the TV were used in order to avoid lesions of the valve by overstretching it.

Then the borders of the defect were easily visualized. The VSD was closed with an autologous pericardium patch mostly (with a synthetic or a bovine pericardial patch in some cases) sutured using a continuous 5–0 Prolene starting at midpoint of the anterior margin. The leaflet was reattached along the line of incision using a continuous 7–0 Prolene suture.

After that, the tricuspid valve competence and coaptation was assessed by filling the right ventricle with a cold saline infusion (Figure 3).

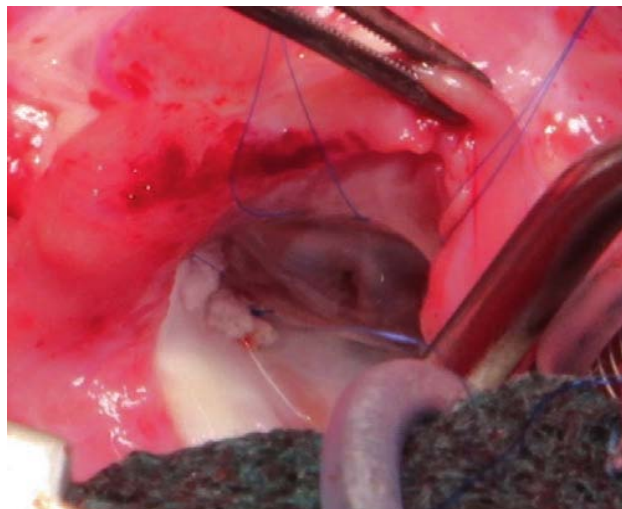


Figure 3: Saline pressure testing of the tricuspid valve shows a competent valve [8]

In some cases, after the closing of the VSD, additional procedures were carried out to address the associated cardiac malformations:

- Closure of an associated atrial defect.
- Enlargement of the pulmonary artery using a patch in case of an associated pulmonary stenosis and concomitant to an Infundibular resection and pulmonary commissurotomy in case of TOF.

Then, the right atrium was closed, the aortic cross clamp removed and the weaning from CPB performed. After bleeding control, the surgery was ended in the usual way.

IV. ETHICAL CONSIDERATIONS

We undertook a retrospective study. Thus, it does not require the formal approval of the patients in our series. Nevertheless, our study was performed in the strict respect of the patient privacy and anonymity.



RESULTS



I. EPIDEMIOLOGY

1. AGE

The mean age of our patients was 5.8 years with a standard deviation of 4.88 and a range from 9 months–old to 21 years–old.

Table I provides the age distribution of the patients in our case series.

Table I: Age distribution of our patients

Age group in years	Number of patients	Percentage
< 4	12	42.9 %
4 - 12	13	46.4 %
12-18	2	7.1 %
> 18	1	3.6 %
Total	28	100 %

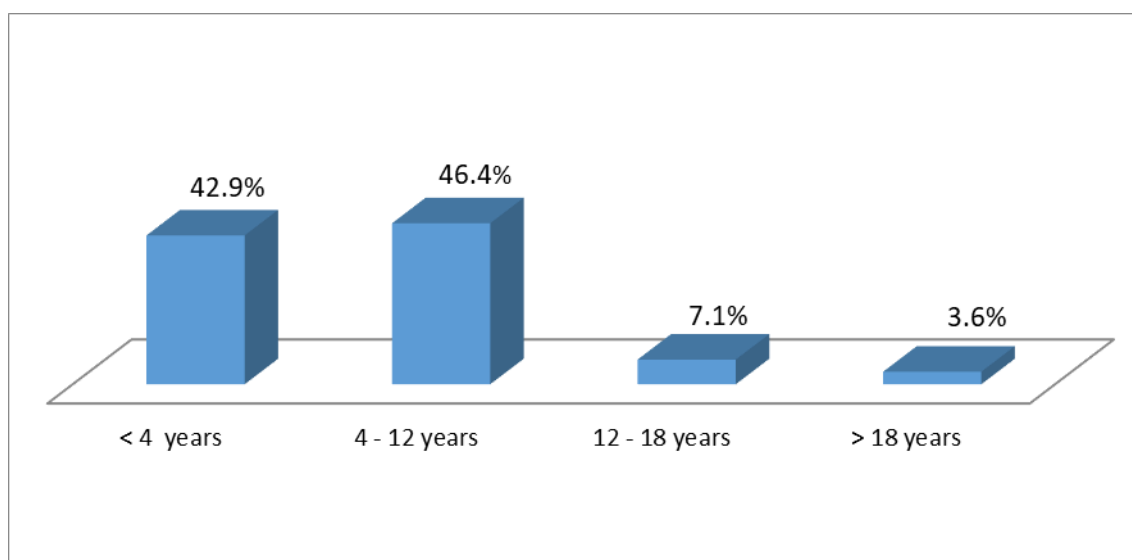


Figure 4: Age distribution of our patients

2. GENDER

In our study: 18 (64.3%) patients were male and 10 (35.7%) were female with a 1.77 sex ratio.

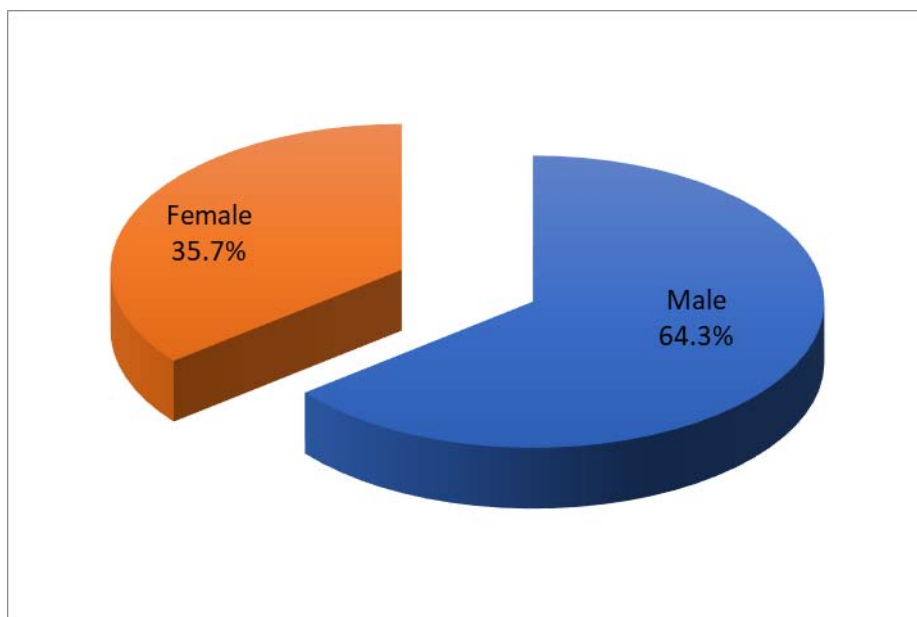


Figure 5: Gender distribution of our patients

II. CLINICAL DATA

1. CASE HISTORY

Among our patients:

- Eighteen (64.3%) had a history of recurrent respiratory infections.
- Twenty (71.4%) had been admitted at least once in Pediatrics service.
- Four (14.3%) had undergone a pulmonary artery banding procedure.

Table II: Medical history in our case series

	Number of patients	Percentage
Recurrent respiratory infections	18	64.3%
Pediatrics hospitalizations	20	71.4%
Pulmonary artery banding	4	14.3%

2. FUNCTIONAL SYMPTOMS

2.1. Heart failure

In our study, the heart failure (HF) severity was assessed using the modified Ross Heart failure (HF) classification:

- Seven (25%) patients had a class II Ross HF.
- Twenty (71.4%) patients had a class III Ross HF.
- One (3.6%) had a class IV Ross HF.

Table III: Heart failure in our case series

	Number of patients	Percentage
Class II Ross heart failure	7	25%
Class III Ross heart failure	20	71.4%
Class IV Ross heart failure	1	3.6%
TOTAL	28	100%

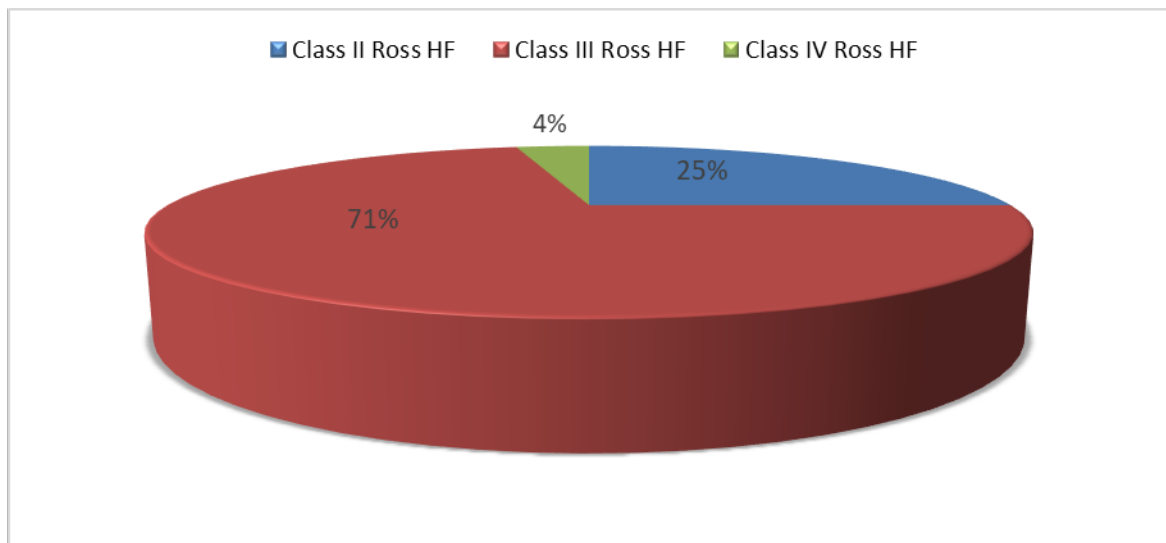


Figure 6: Heart failure in our case series

2.2. Height-weight growth delay

Another cardiac malformation symptom that calls out is height and weight growth delay. In this study, 12 patients had that symptom which accounts for 42.9%.

3. PHYSICAL SYMPTOMS

3.1. Weight

In this series, the mean weight before surgery was 18.57 kg with a standard deviation of 13.51. The patient with the lowest weight had 6 kg and the heaviest had 70 kg.

3.2. Heart rate, Oxygen saturation, heart failure syndrome

In our series:

- Twenty-six (92.9%) patients had a normal heart rate, while 2 (7.1%) patient had tachycardia.
- Nine (32.1%) patients had cyanosis, whilst 19 (67.9%) had a normal oxygen saturation.
- One (3.6%) patient had a global heart failure syndrome.

Table IV: Clinical signs prevalence in our case series

	Number of patients	Percentage
Tachycardia	2	7.1 %
Cyanosis	9	32.1 %
Global heart failure syndrome	1	3.6 %

3.3. Auscultation

The pan systolic murmur is the most characteristic heart murmur of the VSD. It was present in 17 (60.7%) of our patients. A pulmonary stenosis systolic murmur was found in 11 (39.3%) of the patients.

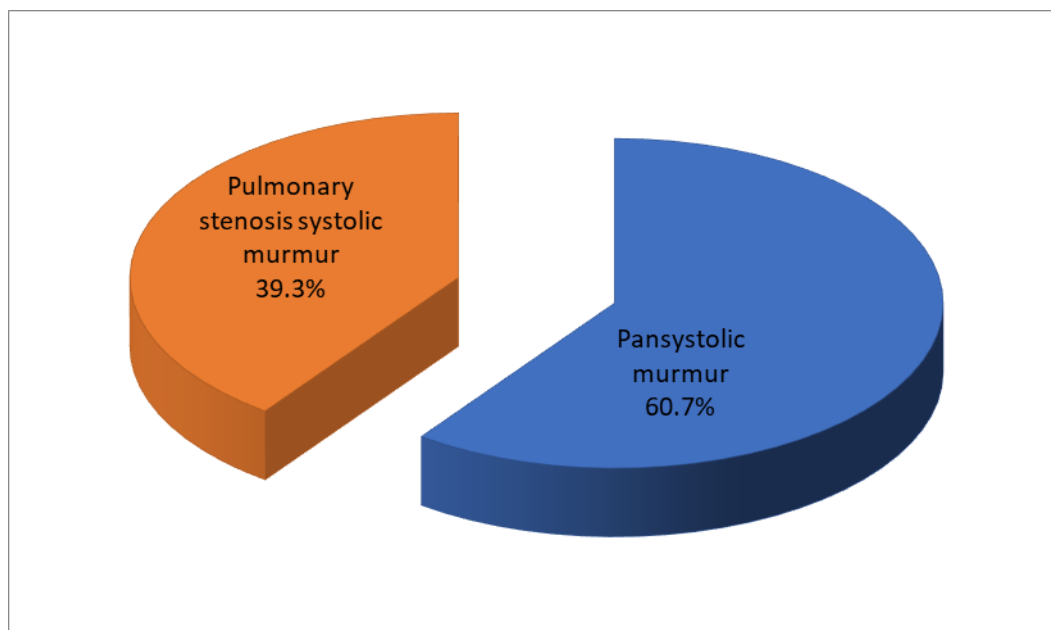


Figure 7: Heart murmur distribution in our series

III. PARACLINICAL DATA

1. ELECTROCARDIOGRAM

In our study:

- Eighteen (64.3%) patients had a regular sinus rhythm.
- Three (10.7%) patients had a regular sinus rhythm with an isolated left ventricular hypertrophy (LVH).
- Four (14.3%) patients had a regular sinus rhythm with a biventricular hypertrophy.
- Three (10.7%) patients had an incomplete right bundle branch block (RBB).

Table V: ECG assessment in our case series

ECG Assessment	Number of patients	Percentage
Regular sinus rhythm	18	64.3
RSR with LVH	3	10.7
RSR with LVH + RVH	4	14.3
Incomplete RBB	3	10.7

2. ECHOCARDIOGRAPHIC DATA

2.1. Type and diameter of the VSD

In our case series:

- Twenty-one (75%) patients had a perimembranous VSD.
- Five (17.8%) patients had a conoventricular VSD.
- One (3.6%) patient had both a muscular VSD and a perimembranous one.
- One (3.6%) patient had two muscular VSDs.

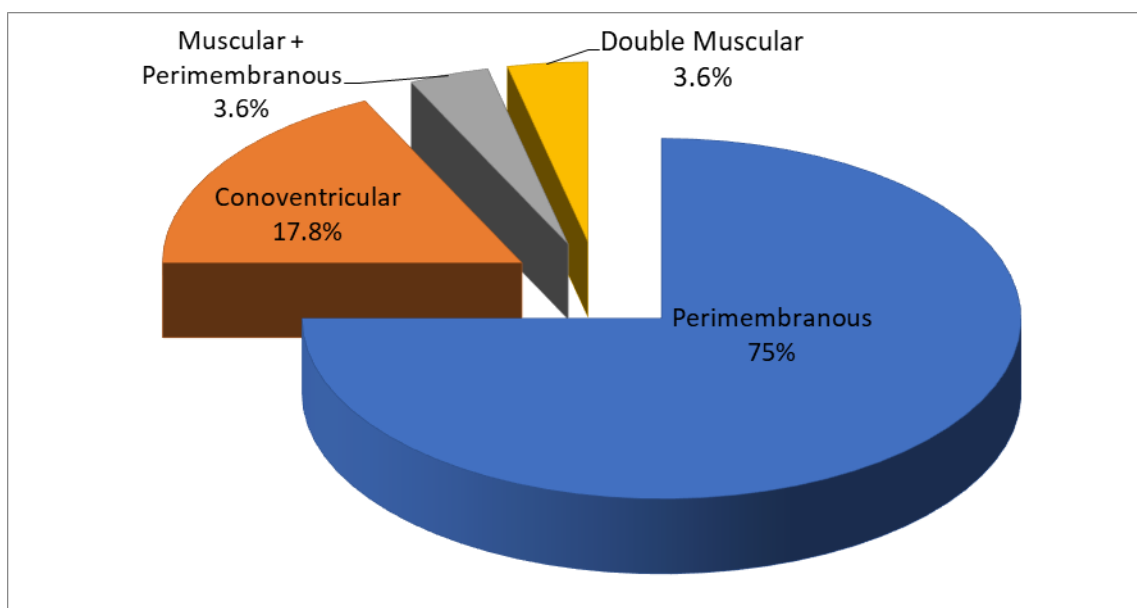


Figure 8: Type of VSD in our case series

About the size of the VSD, most of our patients had a large (diameter > 7 mm) VSD leading to an important Left-to-Right shunt. In our case series:

- Five (17.8%) patients had a VSD diameter less than 7 mm.
- Fifteen (53.6%) patients had a VSD diameter between 7 and 15 mm.
- Eight (28.6%) patients had a VSD diameter superior to 15 mm.

The mean diameter of the VSD in our series was 11.38 mm \pm 4.83 mm with a minimum of 3 mm and a maximum of 22 mm.

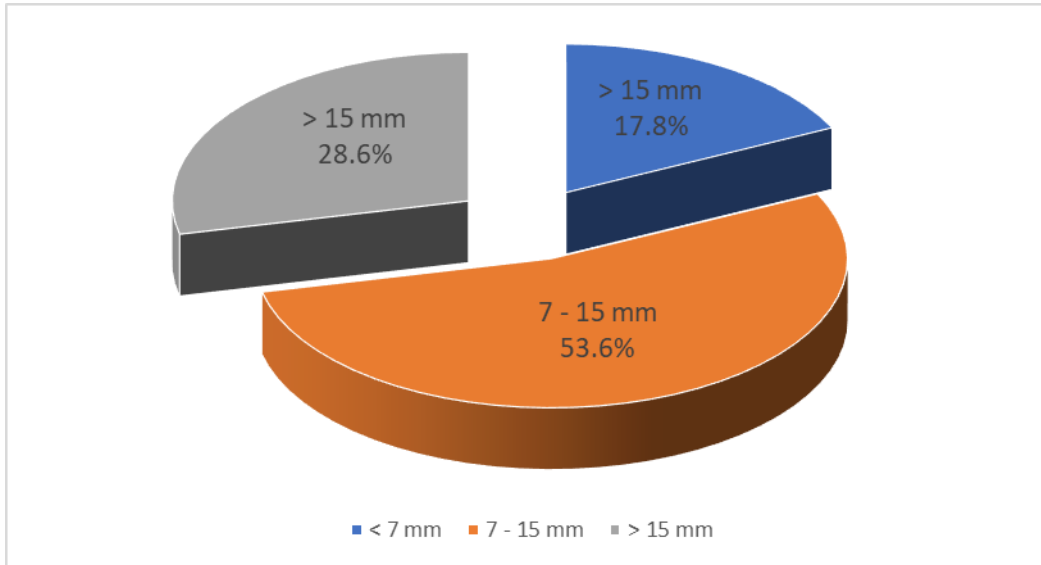


Figure 9: VSD diameter in our series

2.2. Associated cardiac defects

In our case series, the echocardiographic analysis showed that 12 (42.9%) of our patients had an isolated VSD. The remaining patients had the following associated cardiac malformations:

- Eight (28.6%) patients had the VSD as a component of the Fallot’s tetralogy.
- Four (14.3%) patients had an atrial septal defect (ASD).
- Four (14.3%) patients had a pulmonary stenosis.

Table VI: Associated cardiac defects in our case series

Associated cardiac defects	Number of patients	Percentage
Isolated VSD	12	42.8 %
Fallot’s tetralogy	8	28.6 %
Atrial septal defect	4	14.3 %
Pulmonary stenosis	4	14.3 %
Total	28	100 %

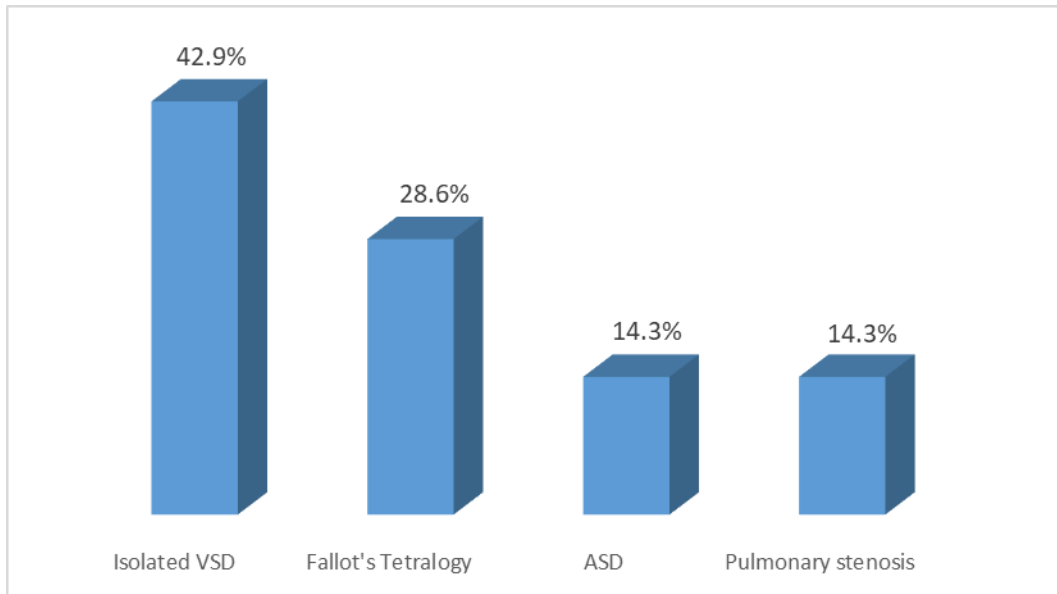


Figure 10: Associated cardiac defects in our case series

2.3. Preoperative tricuspid regurgitation assessment

The echocardiography exam also allowed the analysis of the tricuspid valve architecture looking for a pre-existing tricuspid regurgitation with the color-Doppler assessment providing the following scores:

- TR 0: No tricuspid regurgitation
- TR 1+: Trivial TR
- TR 2+: Mild TR
- TR 3+: Moderate TR
- TR 4+: Severe TR

In our case series:

- Seven (25%) patients had no tricuspid regurgitation
- Four (14.3%) patients had a trivial tricuspid regurgitation
- Thirteen (46.4%) patients had a mild tricuspid regurgitation
- Three (10.7%) patients had a moderate tricuspid regurgitation
- One (3.6%) patient had a severe tricuspid regurgitation caused by a tricuspid dysplasia.

Table VII: Distribution of our patients by the grade of preoperative TR

TR Grade	Number of patients	Percentage
TR 0	7	25%
TR 1+	4	14.3%
TR 2+	13	46.4%
TR 3+	3	10.7%
TR 4+	1	3.6%
Total	28	100 %

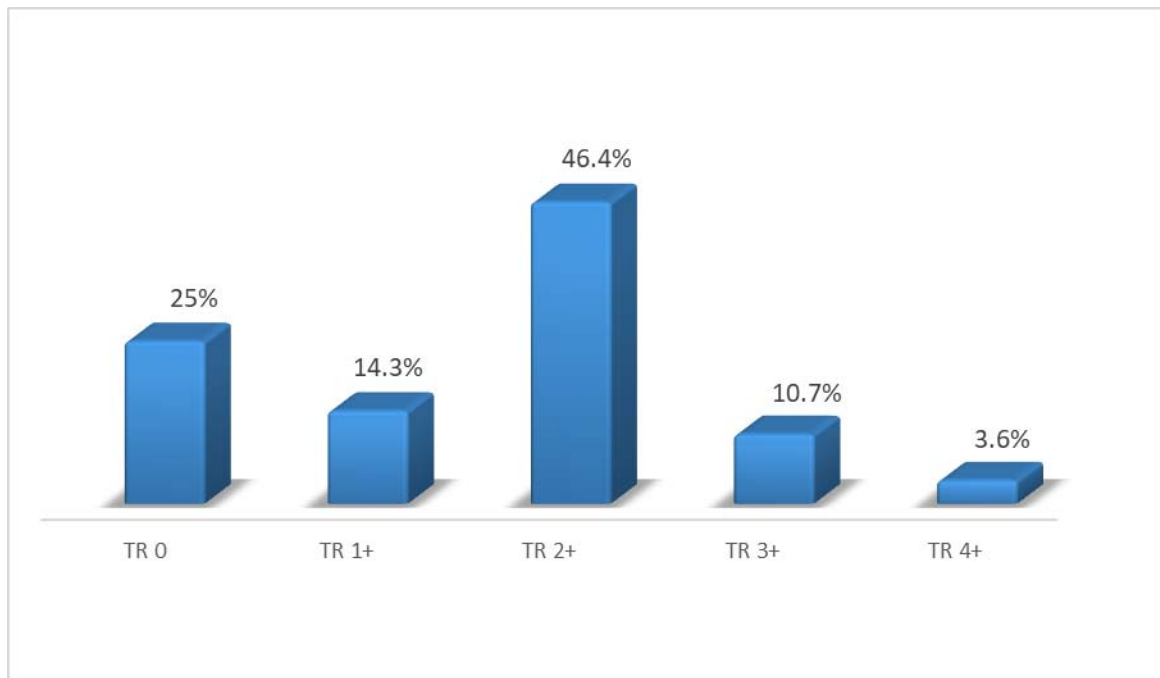


Figure 11: Distribution of our patients by the grade of preoperative TR

2.4. Pulmonary Hypertension

Another crucial element detected by the echocardiography was the pulmonary hypertension which is a decisive element while assessing the surgery indication.

A pulmonary artery systolic pressure > 35 mmHg is in favor of a pulmonary hypertension.

The pulmonary artery systolic pressure is estimated from both the measure of the pressure in the right atrium and the velocity of the tricuspid leak.

In our case series:

- Thirteen (46.4%) patients had a normal pulmonary artery systolic pressure (≤ 35 mmHg).
- Eight (28.6%) patients had a moderate pulmonary hypertension.
- Seven (25%) patients had a severe pulmonary hypertension.

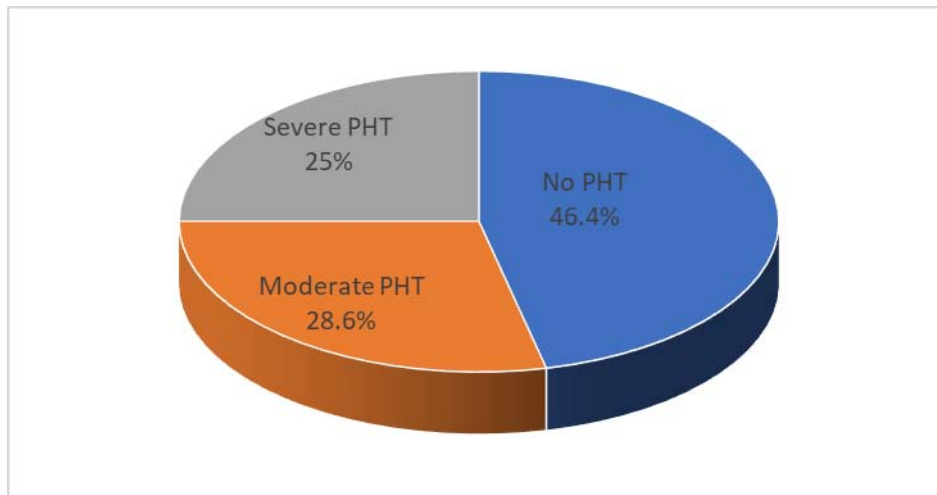


Figure 12: Distribution of pulmonary Hypertension in our case series

IV. SURGICAL TREATMENT

1. Intraoperative assessment

1.1. Type of VSD

The intraoperative assessment found the following types of VSDs:

- Twenty-one (75%) patients had a perimembranous VSD.
- Five (17.8%) patients had a conoventricular VSD.
- Two (7.2%) patients had a double VSD: both a muscular VSD and a perimembranous one.

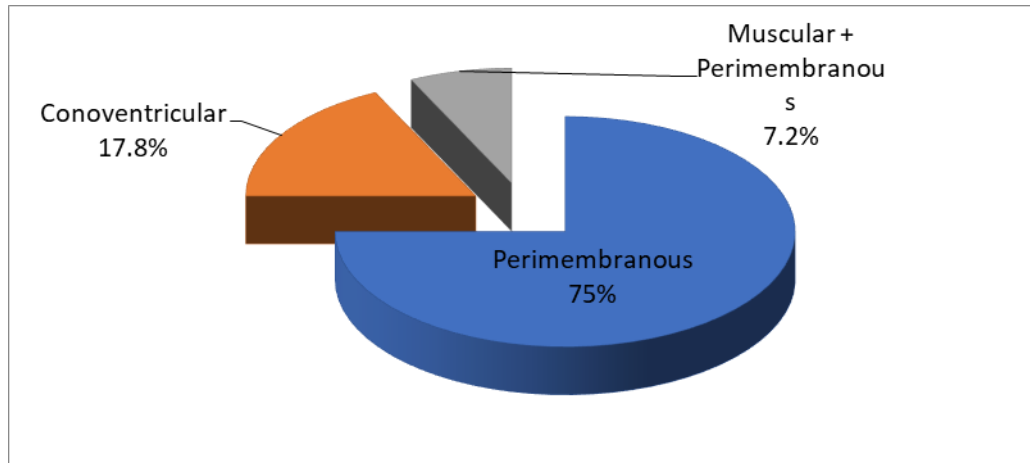


Figure 13: Intraoperative assessment of VSD Type in our study

1.2. Associated cardiac defects

The surgical exploration found the following associated cardiac defects as detailed in table 5.

Table VIII: Perioperative findings in our case series

Associated cardiac defects	Number of patients	Percentage
Atrial septal defect	9	32.1 %
Fallot's tetralogy	8	28.6 %
Pulmonary stenosis	4	14.3 %
Patent ductus arteriosus	2	7.1 %

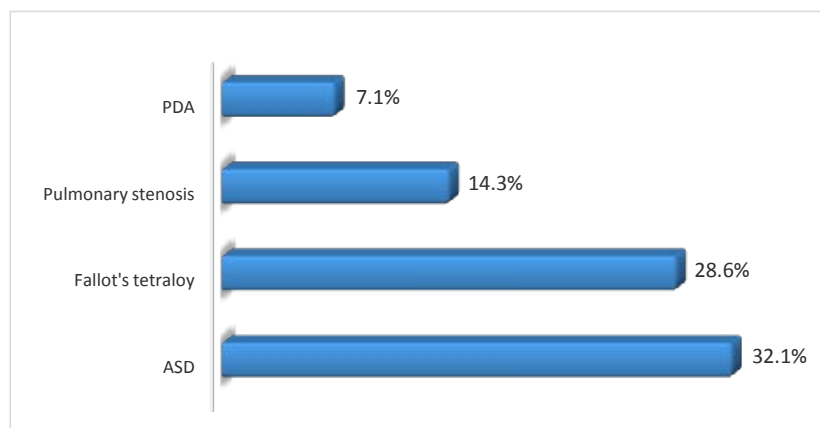


Figure 14: Perioperative findings in our case series

2. Surgical Procedures

2.1. Type of tricuspid valve detachment

A partial detachment of the tricuspid's septal leaflet was performed for 19 (67.9%) of our patients. For 2 (7.1%) patients it was the anterior leaflet that was partially detached. And 7 (25%) patients had a partial detachment of both the septal leaflet and a segment of the anterior one.

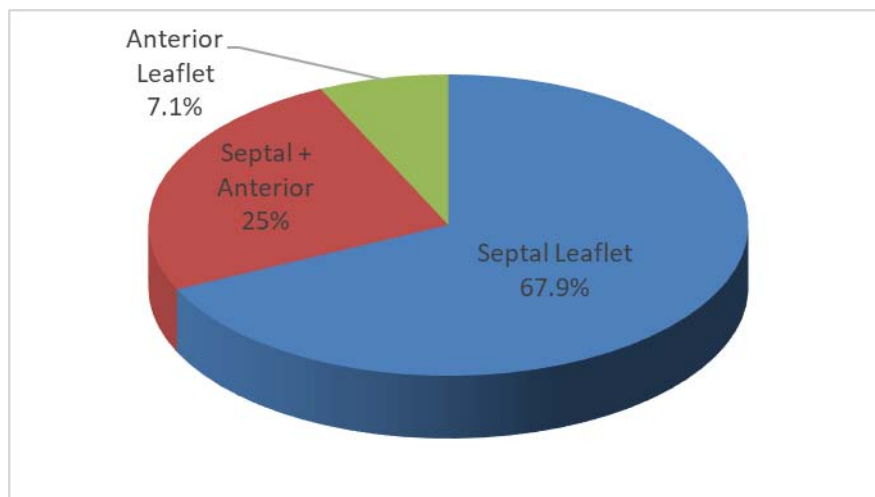


Figure 15: Type of TVD performed in our case series

2.2. Closure of the VSD

The VSD was closed using an autologous pericardium patch for 22 (78.6%) patients. A bovine pericardial patch was used for 4 (14.3%) patients and a synthetic one for 2 (7.1%) patients.

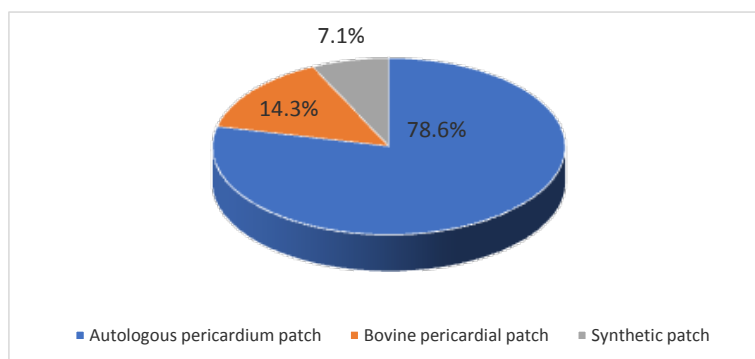


Figure 16: Type of patch used for the closure of the VSD in our case series

2.3. Additional procedures

The associated cardiac malformations in our patients generated additional surgical procedures to fix them.

- An atrial septal defect closure was performed for 9 (32.1%) patients.
- A patent ductus arteriosus ligation was performed for 2 (7.1%) patients.
- An infundibular stenosis resection was performed for 12 (42.9%) patients.
- A pulmonary artery enlargement was performed for 7 (25%) patients.
- A pulmonary commissurotomy was performed for 3 (10.7%) patients.

Table IX: Additional procedures in our case series

Procedure	Number of patients	Percentage
ASD closure	9	32.1 %
PDA ligation	2	7.1 %
Infundibular stenosis resection	12	42.9 %
Pulmonary artery enlargement	7	25 %
Pulmonary commissurotomy	3	10.7 %

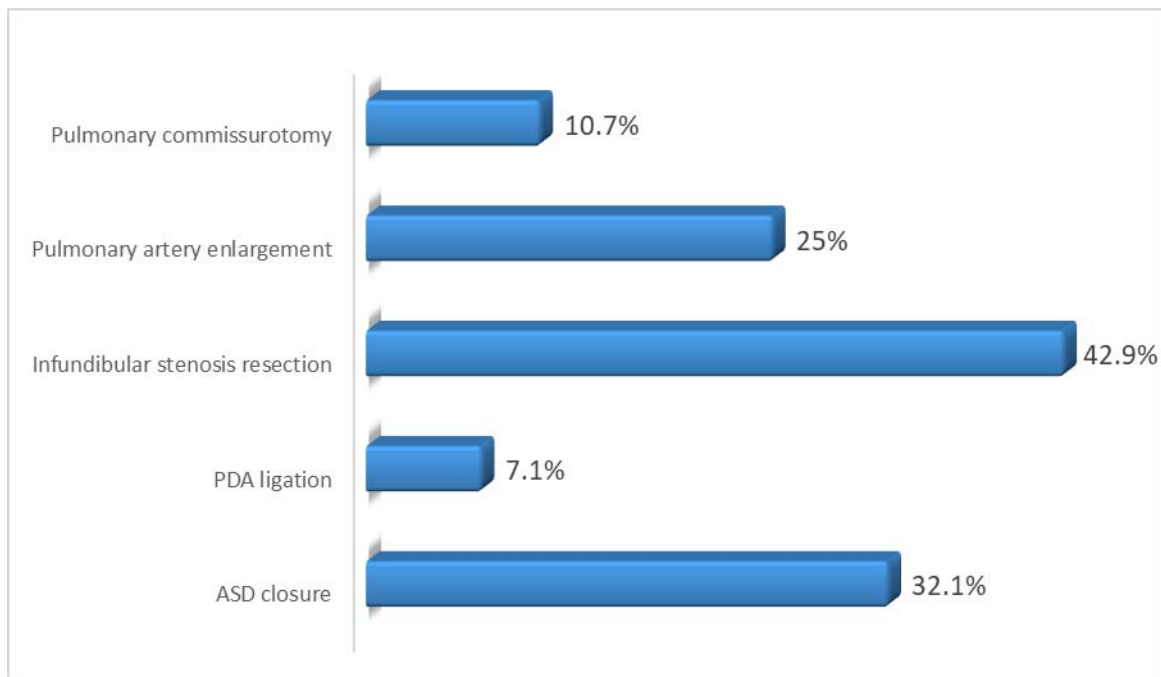


Figure 17: Additional procedures in our case series

2.4. Cardio-pulmonary bypass and aortic cross-clamp time

The mean cardiopulmonary bypass time was 111.25 min \pm 37.12 min with a minimum of 51 min and a maximum of 185 min.

The mean aortic cross-clamp time was 75.18 min \pm 27.67 min with a minimum of 42 min and a maximum of 142 min.

2.5. Tricuspid valve test

After the closure of the VSD and the following reattachment of the tricuspid valve, a tricuspid competence test was performed by filling the right ventricle with cold saline infusion. That was done in order to assess whether the valve is competent.

Twenty-five (89.3%) of our patients had no tricuspid leak while 3 (10.7%) patients had a trivial leak.

V. POSTOPERATIVE EVOLUTION

1. Immediate postoperative aftermath

1.1. Morbidity

During their ICU stay:

- Twenty (71.4%) patients did not suffer from any complication.
- Two (7.1%) patients developed sinus bradycardia in both cases that was managed by an electrostimulation. Neither of those patients required an implantation of a permanent pacemaker.
- One patient (3.6%) developed a sinus tachycardia that was managed by anti-arrhythmic drugs.
- Three (10.7%) patients suffered from infectious complications: 2 suffered from sepsis and one suffered from surgical-site infection. It was managed by antibiotics targeting the incriminated germ and vascular filling (for the sepsis).

- Four (17.9%) patients were subject to a postoperative hemorrhage that was managed by hemostatic agents and blood transfusion. No reoperation for massive and uncontrolled bleeding was required.

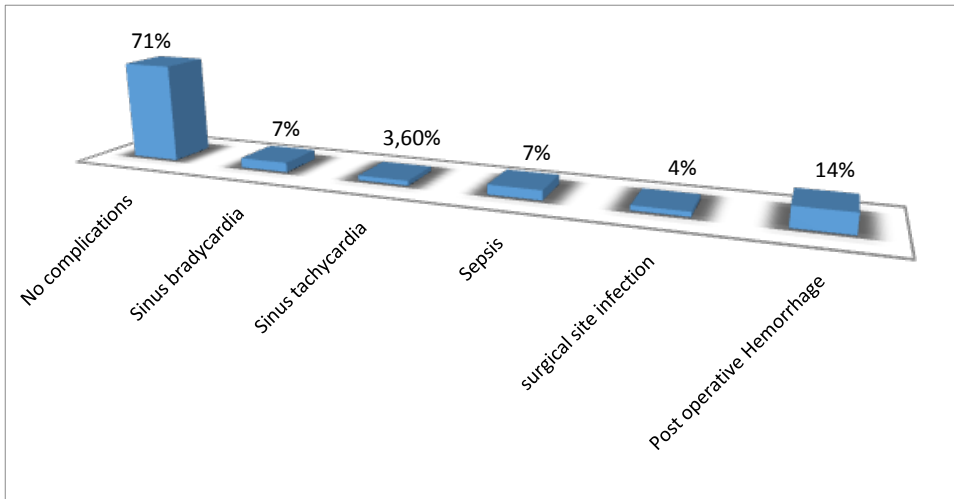


Figure 18: Surgery aftermath in our case series

1.2. Intubation time, ICU and hospital duration

In our case series, the mean intubation time was 4.57 ± 3.35 hours from a minimum of 1 hour to a maximum of 18 hours

The mean duration of ICU stay was 4.5 ± 2.6 days ranging from a minimum of 2 days to a maximum of 15 days.

The mean total hospital stay in our case series was 11 ± 4.25 days with a minimum of 7 days and a maximum of 22 days.

2. Postoperative assessment before discharge

2.1. Electrocardiogram

Before being discharged from the hospital, all patients had an electrocardiogram.

In our case series, all 28 (100%) patients had a regular sinus rhythm.

No atrioventricular block neither a transient nor a permanent one was recorded.

No Right bundle branch block neither complete nor incomplete was recorded as well.

2.2. Echocardiography

a. **Residual VSD**

The first key element analyzed by the echocardiography performed for all our patients before being discharged was whether or not they presented a residual ventricular septal defect.

And if it was the case to assess the following elements:

- The size of the eventual residual VSD.
- The importance of the residual left to right shunt.

That echocardiography found that:

- Twenty-two (78.6%) of our patients did not have a residual VSD.
- Six (21.4%) of our patients had a small, hemodynamically non-significant residual VSD.

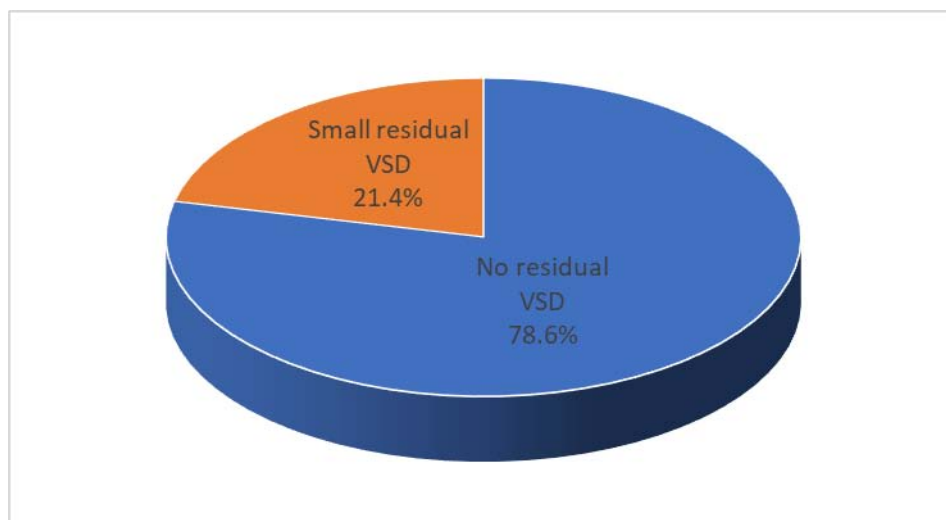


Figure 19: Occurrence of Residual VSD before discharge in our case series

b. Tricuspid Regurgitation

The analysis of the tricuspid valve is also of paramount importance in order to assert if there is not a tricuspid regurgitation induced by the procedure.

In our case series, the echocardiography found that:

- Nineteen (67.8%) patients had no tricuspid regurgitation.
- Eight (28.6%) patients had a trivial tricuspid regurgitation.
- One (3.6%) patient had a mild tricuspid regurgitation.

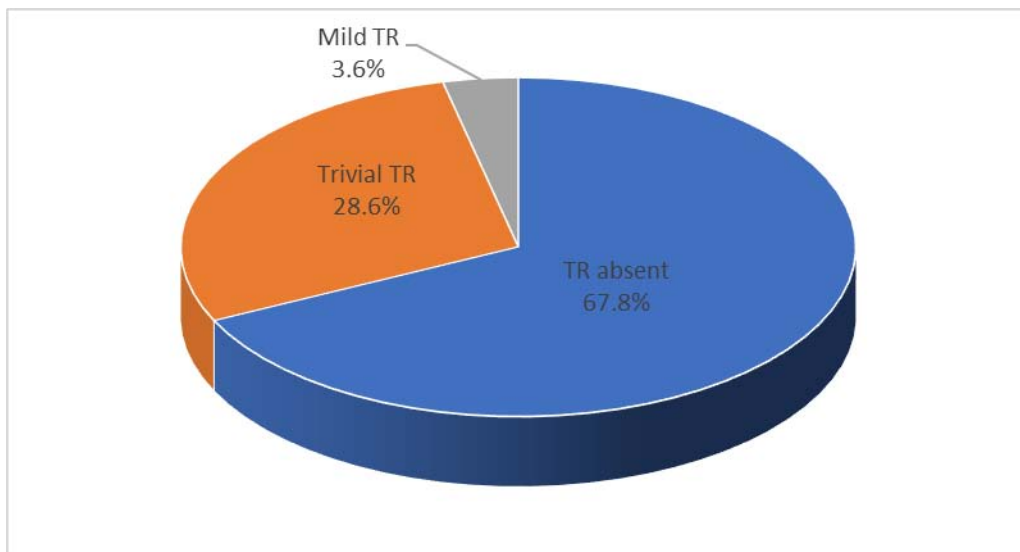


Figure 20: Occurrence of Tricuspid Regurgitation before discharge in our case series

c. Pulmonary hypertension

At the echocardiographic assessment before discharge:

All 28 (100%) patients had a normal (≤ 35 mmHg) pulmonary artery systolic pressure.

3. Postoperative assessment at 6 months follow-up

3.1. Electrocardiography

The electrocardiography performed after 6 months of follow-up found that:

- All 28 (100%) patients in our case series had a regular sinus rhythm.
- No AVB was recorded.
- No Right bundle branch block neither complete nor incomplete was recorded as well.

3.2. Echocardiography

a. Residual VSD

The echocardiography performed after 6 months of follow-up found that:

- Twenty-four (85.7%) of our patients did not have a residual VSD.
- Four (14.3%) of our patients had a small, hemodynamically non-significant residual VSD.

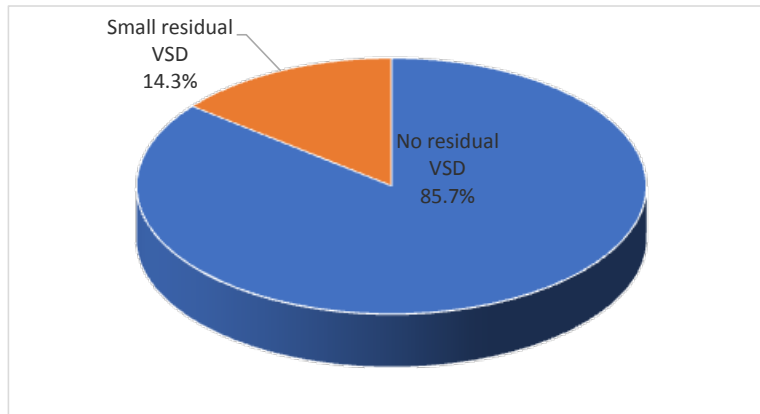


Figure 21: Occurrence of Residual VSD at 6 months follow up in our case series

b. Tricuspid Regurgitation

The analysis of the tricuspid valve by the echocardiography performed after 6 months follow-up found that:

- Twenty-four (85.7%) patients did not have tricuspid regurgitation.
- Two (7.1%) patients had a trivial tricuspid regurgitation.
- Two (7.1%) patients had a mild tricuspid regurgitation.

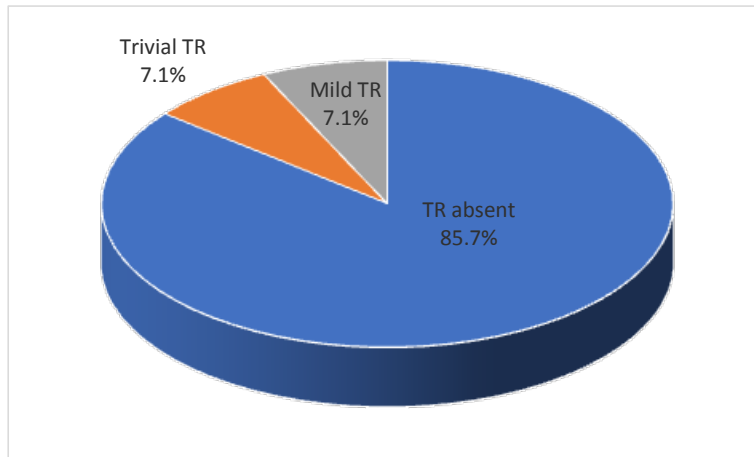


Figure 22: Occurrence of Tricuspid Regurgitation at 6 months follow up in our case series

c. Pulmonary hypertension

At the echocardiographic assessment after 6 months follow up:

All 28 (100%) patients had a normal (≤ 35 mmHg) pulmonary artery systolic pressure.

4. Long term follow-up assessment

The mean follow-up period in our study is 4.4 ± 2.5 years, with a minimum of 6 months follow up to a maximum of 8 years of follow-up.

4.1. Electrocardiogram

The electrocardiography performed at a mean follow-up of 4.4 years found that:

- All 28 (100%) patients in our case series had a regular sinus rhythm.
- No AVB was recorded.
- No Right bundle block neither complete nor incomplete was recorded as well.

4.2. Echocardiography

a. **Residual VSD**

The echocardiography performed at a mean follow-up of 4.4 years found that:

- Twenty-four (85.7%) patients did not have a residual VSD.
- Three (10.7%) patients had a small, hemodynamically non-significant residual VSD.
- One (3.6%) patient had a large VSD that required a reoperation.

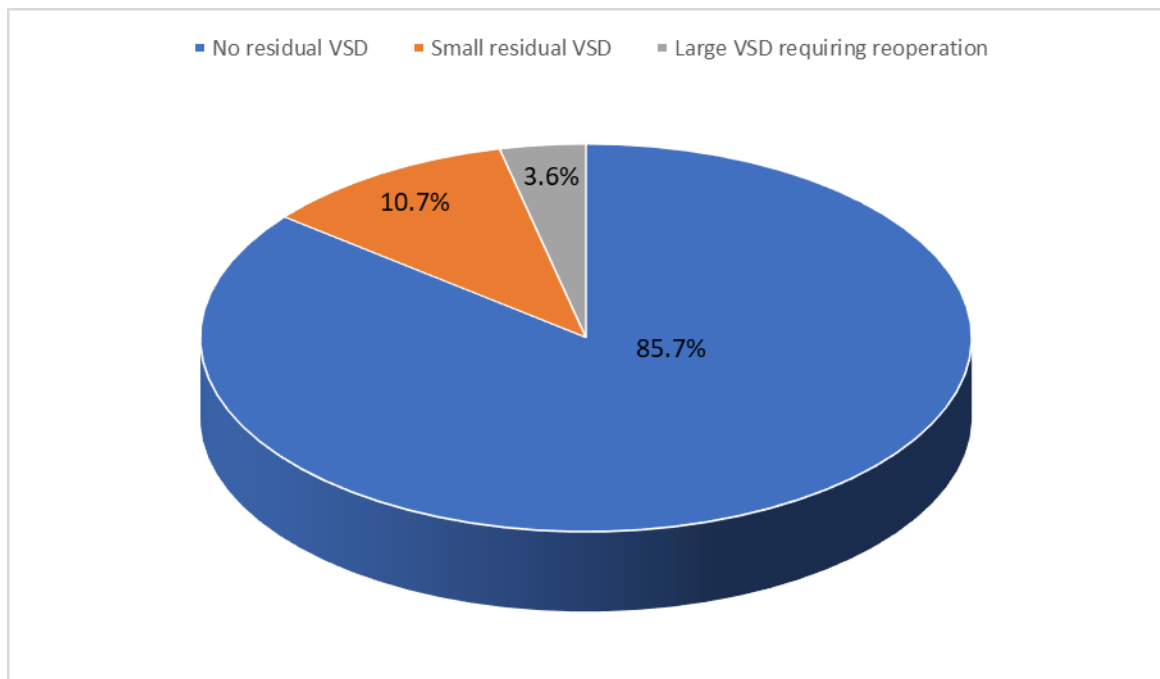


Figure 23: Occurrence of Residual VSD at long term follow up in our case series

b. **Tricuspid Regurgitation**

The tricuspid valve analysis during the echocardiography performed at a mean follow-up of 4.4 years found that:

- Twenty-five (89.3%) patients did not have a tricuspid regurgitation.
- Two (7.1%) patients had a trivial tricuspid regurgitation.
- One (3.6%) patient had a mild tricuspid regurgitation.

None of our patients had a tricuspid stenosis at the long-term follow-up echocardiogram.

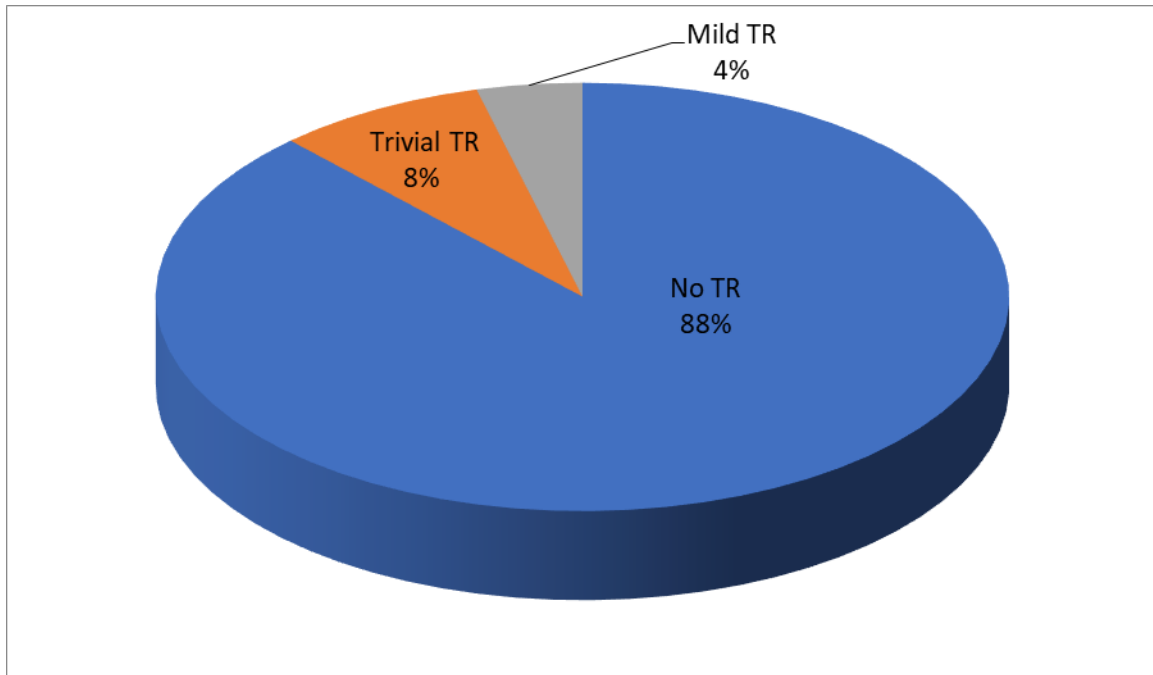


Figure 24: Occurrence of Tricuspid Regurgitation at long term follow up in our case series

c. Pulmonary hypertension

At the echocardiographic assessment for long term follow up:

All 28 (100%) patients had a normal (≤ 35 mmHg) pulmonary artery systolic pressure.



DISCUSSION



The ventricular septal defect is a congenital malformation where there is a defect in the interventricular septum of the heart.

According to the Anderson anatomic classification [9], VSDs are divided in 3 groups in regards of their respective position in the interventricular septum (Figure 25):

- Perimembranous VSDs: Due to a deficiency of the membranous septum, with an extension towards the inlet, either central trabecular or outlet portions of the septum.
- Muscular VSDs: they are totally surrounded by muscular tissue. They can be located in any portion of the septum. There are three main types of muscular VSDs: inlet VSDs, central trabecular VSDs and infundibular VSDs. They can be single or multiple in which case they constitute a “swiss cheese” type of muscular VSDs.
- Juxta-arterial defects: where there is a fibrous continuity between the aortic and pulmonary valves.

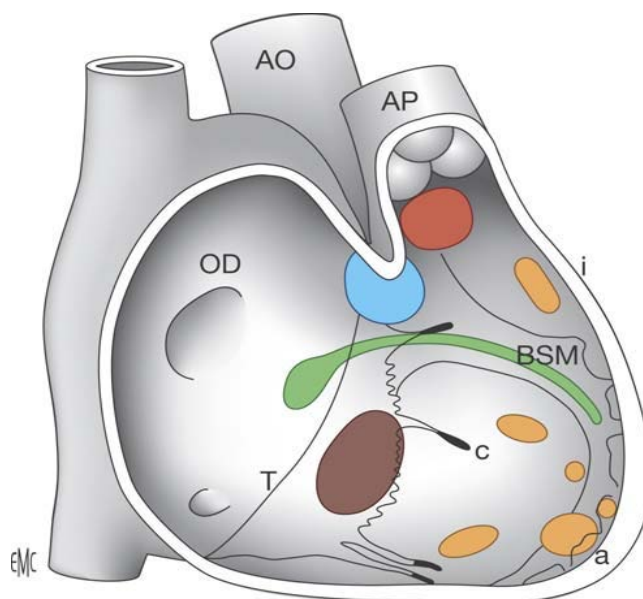


Figure 25: Picture of the interventricular septum seen from the right ventricle [10].

Red: Juxta-arterial VSD. Blue: Perimembranous VSD. Brown: inlet VSD.

Orange: Infundibular VSD (i), central trabecular (c), apical (a), apical (a). Green: AV node and Bundle of His.

During the first year of life, approximately 85 to 90 % of small, isolated and mostly muscular VSDs close spontaneously [7].

However, in case a spontaneous closure does not occur and in the presence of a large (>7mm) and hemodynamically significant VSD, a surgical or a percutaneous closure intervention must be performed.

The trans-catheter closure, when the anatomy of the VSD is favourable, is reserved for those in whom surgery is very risky due to severe pulmonary artery hypertension, multiple comorbidities and those with residual or recurrent VSDs after surgical closure. [8]

Complete surgical repair of the defect by patch closure is by far the most common approach.

Nonetheless, the differing anatomical variants require different surgical approaches. Thus, three surgical approaches are possible:

- Via a right atriotomy: the gold standard surgical approach for closure of perimembranous and muscular VSDs.
- Via a right ventriculotomy: mostly used for patients for whom the VSD is a component of the Fallot's tetralogy when there will be a need to perform a pulmonary artery enlargement as well.
- Via the main pulmonary artery or the aorta: for juxta-arterial defects.

For all patients in our study, a right atriotomy was performed because:

- It generates less scarring than a ventriculotomy.
- It sensibly decreases the risk of complete right bundle branch block.
- It preserves the right ventricular function.

After the right atriotomy is performed, a gentle traction of the anterosuperior leaflet helps exposing the rims of the defect.

However, in some circumstances the presence of thick, tight TV chordae or an aneurysm of the TV conceals the rims of the defect (Figure 26).

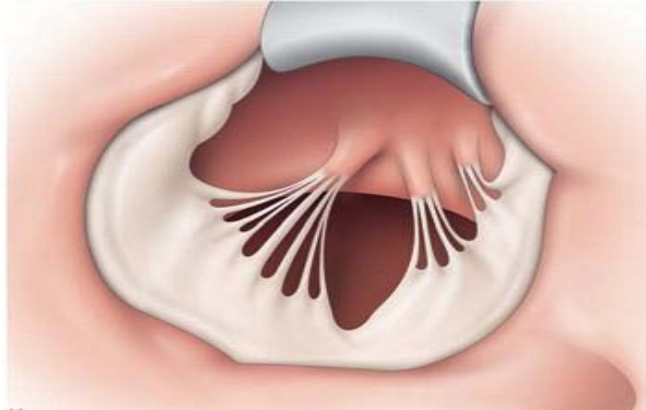


Figure 26: Perimembranous VSD with chordae attachments obscuring its rims [11].

Hence, an inadequate exposure disallowing an optimal closure of the defect and then carrying the risk of damage to the conduction system and residual VSD if the surgery is undertaken without addressing that issue.

Moreover, in case of outlet extension of the VSD in an upper position, exerting too much traction on the TV will result in the distortion of the TV with chordae elongation, hence generating a tricuspid regurgitation.

In front of all those situations, surgeons perform a partial detachment of the septal leaflet extended or not to the anterior one (Figure 27).

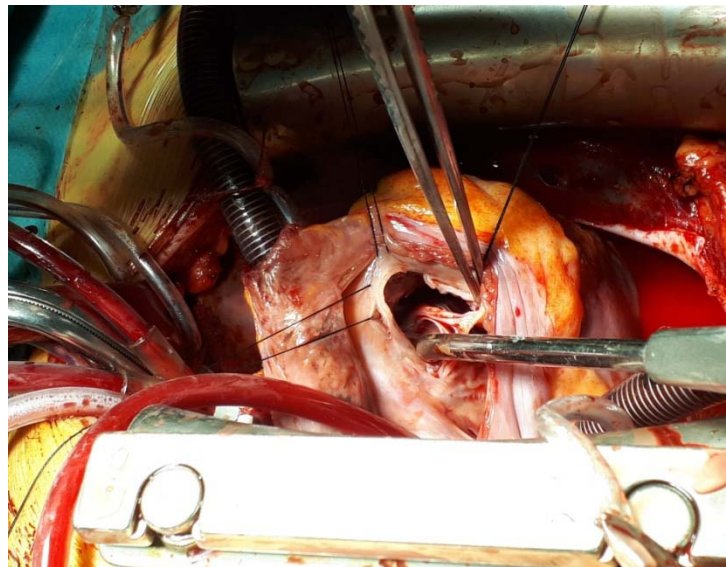


Figure 27: Partial detachment of the septal leaflet extended to the anterior leaflet/
Cardiovascular Surgery Department – University hospital Mohammed VI – Marrakech

The partial detachment of the TV provides both an optimal exposure of the VSD margins and prevent from exerting too much tension on the TV.

The partial detachment of the TV will allow an optimal closure of the defect, prevent the tricuspid regurgitation, and complete heart block [12].

New variants to this technique have been developed:

- A radial incision of the septal leaflet
- A detachment of the chordae from their septal attachments and flipping them over.

Despite numerous studies in favour of the safety and effectiveness of this method, there are still surgeons restraining themselves from using it [5].

We undertook this study to assess the outcomes of patients who underwent VSD closure using tricuspid valve detachment by mainly focusing on the following elements:

- The frequency of residual VSDs.
- The frequency and severity of the tricuspid regurgitation at long-term.
- The occurrence of complete atrio-ventricular blocks.

I. AGE AND GENDER

1. AGE

The average age in our series was 5.8 ± 4.88 years old ranging from 9 months to 21 years old.

It was closer to the series of ZHAO et al (13) and sensibly higher than the series of authors such as SASSON et al (14), LUCCHESI et al (15), BILEN et al (16).

While the age of the study population of RIAZ (17) series was much higher than in our study.

The age of our population study was sensibly higher than in most studies which were undertaken in western developed countries where the diagnosis of congenital heart malformations is achieved much earlier (in some cases in antenatal); hence allowing an early management in specialised paediatric cardiac surgery centers.

Table X: Age of patients (Literature review)

AUTHORS	YEAR OF PUBLICATION	COUNTRY	Mean Age \pm SD (years)
BILEN et al (16)	2020	TURKEY	1.92 \pm 1.83
LUCCHESE et al (15)	2016	ITALY	1.28 \pm 1.01
SASSON et al (14)	2006	ISRAEL	3.36 \pm 3.2
ZHAO et al (13)	2003	CHINA	4.6 \pm 1.5
RIAZ et al (17)	2017	PAKISTAN	13.38 \pm 6.91
OUR CASE SERIES	2021	MOROCCO	5.8 \pm 4.88

2. GENDER

In our study; 64.3% of our patients were male with a 1.77 sex ratio.

However, there is no gender predominance regarding the occurrence of VSDs [10]. Therefore, the male larger population in our study is entirely fortuitous.

That male predominance was also found in the studies of Fraser et al (18), Pourmoghadam et al (19), and Lucchese et al (15) whereas Bilen et al (16) study found a female predominance.

Table XI: Gender distribution of patients (Literature review)

AUTHORS	YEAR OF PUBLICATION	COUNTRY	SEX RATIO M/F
BILEN et al (16)	2020	TURKEY	0.69
FRASER et al (18)	2018	USA	1.51
POURMOGHADAM et al (19)	2018	USA	1.41
LUCCHESE et al (15)	2016	ITALY	1.52
OUR CASE SERIES	2021	MOROCCO	1.77

II. TYPE OF VSD

75% of our patients were suffering from a perimembranous VSD. Other authors such as Russell et al (4), Weymann et al (20), Giordano et al (21) and Bang et al (22) also found that the majority of the patients in their respective series were admitted for a perimembranous VSDs closure.

This is explained by the fact that perimembranous VSDs account for around 20 to 35 % of the total VSD but make up the vast majority of VSDs requiring a surgical closure [10].

The reason behind that fact is the very low potential of perimembranous VSDs to close spontaneously particularly in case of moderate to large ones [10].

Moreover, the perimembranous VSDs are located between the septal part of the tricuspid annulus and the insertion of the papillary muscle of the tricuspid valve (see Figure 25).

Table XII: Percentage of patients with perimembranous VSD

AUTHORS	YEAR OF PUBLICATION	COUNTRY	PERIMEMBRANOUS VSD %
GIORDANO et al (21)	2018	ITALY	87.6 %
BANG JH et al (22)	2016	SOUTH KOREA	95.9 %
WEYMANN et al (20)	2013	GERMANY	90 %
RUSSELL et al (4)	2011	USA	98.3 %
OUR CASE SERIES	2021	MOROCCO	75 %

III. CARDIOPULMONARY BYPASS AND AORTIC CROSS-CLAMP TIME

There have been concerns that TVD increases significantly the CPB time but that remains a controversial issue. Temporary TVD may decrease the operation time by easing the placing and suturing process of the patch. However, this technique requires additional CPB time for the reattachment of the septal (and/or anterior) leaflet of the tricuspid valve.

Nonetheless, in our context, the TV reattachment was performed using the same continuous suture of the patch placed as a “sandwich” between the annulus and the detached leaflet. That process spared operative time.

The mean CPB time in our study was 111.25 ± 37.12 min and the mean aortic cross clamp time was 75.18 ± 27.67 min.

The cross-clamp time in our study was higher than in the literature since we included in our study patients for whom the VSD was a component of Fallot’s tetralogy. Those patients will require additional heavy surgical procedures such as the pulmonary artery enlargement, the infundibular resection, and the pulmonary commissurotomy.

Table XIII: Mean CPB time in various studies

AUTHORS	YEAR OF PUBLICATION	COUNTRY	MEAN Cross-Clamp TIME \pm SD (min)
POURMOGHADAM et al (19)	2018	USA	73 \pm 20
GIORDANO et al (21)	2018	ITALY	63 \pm 9
RIAZ et al (17)	2017	PAKISTAN	67.91 \pm 27.3
BANG JH et al (22)	2016	SOUTH KOREA	60.0 \pm 22.1
WEYMANN et al (20)	2013	GERMANY	50.7 \pm 12.1
OUR CASE SERIES	2021	MOROCCO	75.18 \pm 27.67

IV. RESIDUAL VSD

The TVD technique provides an optimal exposure of all the VSD margins, which will allow a complete and easy repair.

Indeed, temporary TVD provides a clear view of the edges between the conal septum, the aortic annulus and the ventriculo–infundibular fold, thus minimizing the incidence of residual defects [16]. The temporary TVD also allows a more accurate suture placement, especially in case of multiple chordal attachments crossing over the VSD and inserted at the edge of the defect.

It is very crucial to achieve that complete repair in order to avoid residual defects. Residual hemodynamically significant defects generate severe complications impacting morbidity and mortality such as low cardiac output, pulmonary hypertensive crisis, and infectious endocarditis associated with the risks of the subsequent reoperation.

In our study, at a mean follow-up of 4.4 years: 4(14.3%) patients had a residual VSD. 1(3.6%) patient had a large residual VSD that required a reoperation. The other 3(10.7%) patients had small, hemodynamically meaningless residual defects.

Our results are similar to those reported in published international studies where most authors reported no residual VSD or small hemodynamically meaningless one after surgical closure of VSDs with the TVD technique.

Table XIV: Percentage of patients with no residual VSD and small, non-significant one

AUTHORS	YEAR OF PUBLICATION	COUNTRY	% OF PATIENTS WITH NO RESIDUAL VSD AND SMALL, NON-SIGNIFICANT ONE
BILEN et al (16)	2020	TURKEY	100 %
POURMOGHADAM et al (19)	2018	USA	100 %
FRASER et al (18)	2018	USA	97.6 %
BANG JH et al (22)	2016	SOUTH KOREA	98 %
WEYMANN et al (20)	2013	GERMANY	100 %
OUR CASE SERIES	2021	MOROCCO	96.4 %

Moreover, Russell et al (4), Aeba et al (23), and Gaynor et al (7) included in their series patients with residual VSDs after a first surgery performed without TVD. Their respective reoperation was carried out with TVD and provided a successful and definitive closure.

V. TRICUSPID REGURGITATION

There have been concerns about the function of the tricuspid valve after temporary detachment of the septal leaflet extended or not to the anterior one. Those concerns are the following:

- Tricuspid regurgitation induced by the procedure
- Growth impairment after the reattachment that generates tricuspid stenosis.

However, it is the other way round: the partial detachment of the tricuspid valve not only provides an optimal exposure of the VSDs margins, but it also allows the preservation of the architecture of the tricuspid valve (one of the major goals of the partial TVD). This assertion is based on the fact that when the VSD is located in an upper position with an outlet extension, it requires exerting a severe traction on the tricuspid valve to improve the exposure which will lead to the distortion and elongation of the chordae of the tricuspid valve.

In our case series, the TVD provided good results since 25 (89.3%) of our patients had no tricuspid regurgitation, 2 (7.1%) patients had a trivial TR and 1 (3.6%) patient had a mild TR. No patient developed more than mild TR at a mean follow-up of 4.4 years.

Our results corroborate most studies on this issue even in series with much younger patients.

Bilen et al (16) determined with a mean follow-up of 36.38 months that 88% of their 50 patients in the TVD group had none or trivial TR while 12 % had a mild TR. With a series of 26 patients in the TVD group, Pourmoghadam et al (19) also found with a median follow-up of 2.2 years that 64 % had no TR while the remaining 36 % had a trivial to mild TR. With a larger series of 83 patients in the TVD group, Fraser et al (18) determined with a median follow-up of 4.4 years that 7 (8.4 %) patients had no TR, 75 (90.4%) patients had a trivial to mild TR and 1 (1.2%) patient had a moderate TR.

Table XV: Percentage of patients with more than mild TR (Literature review)

AUTHORS	YEAR OF PUBLICATION	COUNTRY	NUMBER OF PATIENTS IN THE TVD GROUP	MEAN / MEDIAN AGE (months)	% OF PATIENTS WITH MORE THAN MILD TR (TR 2+)
BILEN et al (16)	2020	TURKEY	50	23.26	0 %
FRASER et al (18)	2018	USA	83	7.56	1.2 %
POURMOGHADAM et al (19)	2018	USA	26	6.77	0 %
BANG JH et al (22)	2016	SOUTH KOREA	49	1.97	2 %
WEYMANN et al (20)	2013	GERMANY	20	6	0 %
OUR CASE SERIES	2021	MOROCCO	28	60	0 %

In our case series, the tricuspid function was even improved after surgery (Figure 28). This is explained by the disappearance of pulmonary hypertension after the closure of the VSD, the associated tricuspid plasty performed in some cases and the decrease of the annulus diameter induced by the procedure.

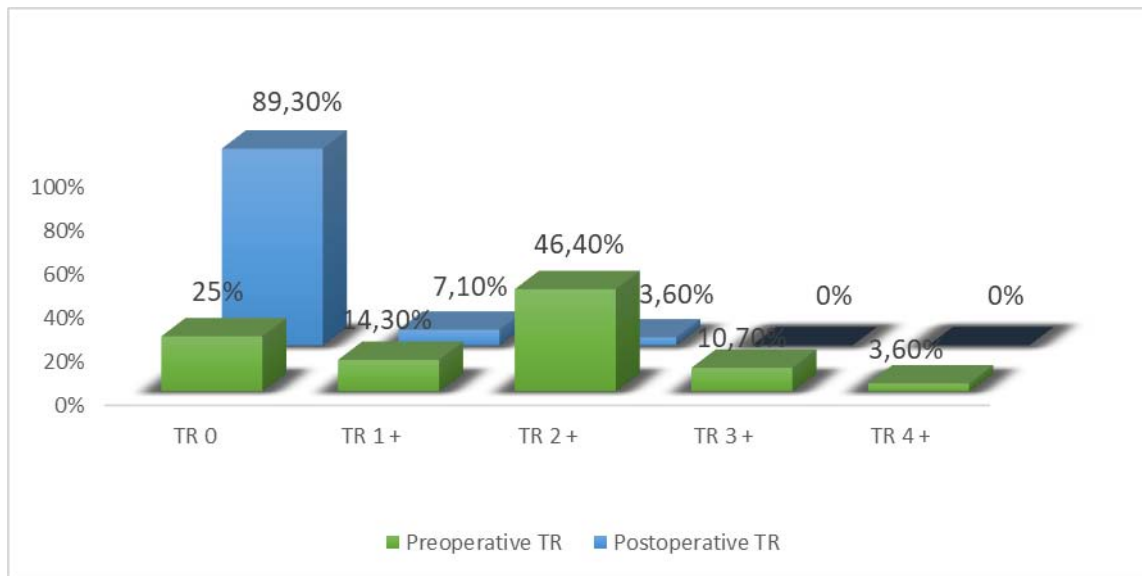


Figure 28: Comparison between the levels of preoperative and postoperative TR

No tricuspid valve stenosis was recorded neither in our study at the long-term follow-up nor in the literature. Hence, we can conclude that it is a more subjective fear than an actual cause of concern.

VI. COMPLETE HEART BLOCK

During surgical closure of perimembranous and inlet VSDs, the proximity of the conduction system with the risk of damaging it is an important source of concern for the surgeons.

However, complete heart block is a rare but very serious complication. Andersen et al. undertook a study with a large cohort of 2079 patients who were operated for VSD closure and reported an incidence of third-degree atrioventricular block less than 1% (23).

In our series, we did not report any complete heart block in any of our patients. Only 2 (7.1%) patients suffered from heart arrhythmia (sinus bradycardia) that did not require permanent pacemaker.

Our results are similar to those found in other studies. Pourmoghadam et al (19), Bang et al (22), Lucchese et al. (15), Weymann et al (20) did not report any complete heart block requiring permanent pacemaker implantation in their studies neither.

Table XVI: Number of patients with complete heart block

AUTHORS	YEAR OF PUBLICATION	COUNTRY	NUMBER OF PATIENTS IN THE TVD GROUP	NUMBER OF PATIENTS WITH COMPLETE HEART BLOCK
POURMOGHADAM et al (19)	2018	USA	26	None
FRASER et al (18)	2018	USA	83	None
BANG JH et al (22)	2016	SOUTH KOREA	49	None
LUCCHESE et al (15)	2016	ITALY	68	None
WEYMAN et al (20)	2013	GERMANY	20	None
OUR CASE SERIES	2021	MOROCCO	28	None

VII. LIMITATIONS OF OUR STUDY

Our study proved the long-term positive outcomes of patients who underwent partial detachment of the tricuspid valve during the surgical closure of their VSDs.

Nevertheless, our study had some limitations that limited the power of our study:

- The retrospective design: in evidence-based medicine, the benefits and disadvantages of a treatment are best assessed with prospective double-blinded studies.

Those kinds of studies are very hard to undertake since the decision to perform or not the detachment is made intraoperatively by the surgeon. It would be very difficult to determine before surgical intervention the patients in need of a TVD and even more challenging to randomize them.

- The small number of patients in our study that do not allow us to draw a definitive conclusion on this issue.
- The absence of a comparison groups of patients who underwent VSD closure without TVD.



CONCLUSION



This is a retrospective, single center and descriptive study of the data of 28 patients who underwent surgery for VSD closure spanning on a period of 10 years from July 2010 to August 2020.

The aim of this study was to assess the long-term outcomes of the TVD on patients who underwent a surgical closure of their VSDs.

The use of the TVD did not result in an increased postoperative morbidity since there was neither any death nor acute complications.

In our study, the use of the TVD produced a definitive closure for all our patients except for one.

At the long-term follow-up, the long-term function of the tricuspid valve was not compromised since none of our patients had more than mild tricuspid regurgitation.

No AV block was recorded neither in postoperative care nor at the long-term follow-up.

Hence, the TVD is an effective method for VSD closure since it allows an optimal closure of the VSD by reliably enhancing the exposure of the VSD rims. Therefore, avoiding the dangerous risk of residual VSD.

The TVD is also a safe method for VSD closure since it prevents both the distortion of the tricuspid valve and the damage to the conduction system.

Our overall results corroborate those found in international published series regarding this issue.

Therefore, we recommend the use of this valuable technique whenever indications for it arise during VSD surgical closure.

Nevertheless, the limitations of our study require further large, multi-center, randomized controlled studies to uproot all concerns about this method once and for all.



ANNEX



Patient's information sheet

THESIS: 'OUTCOME FOLLOWING THE TRICUSPID VALVE DETACHMENT FOR VENTRICULAR SEPTAL DEFECTS CLOSURE'

I. Presurgical assessment

1. Patient's identity:

– Patient's name and surname:

– Age:

– Gender:

M

F

2. Case History

– Recurrent respiratory infections: YES NO

– Pulmonary artery banding: YES NO

– Pediatrics Hospitalizations: YES NO

3. Functional symptoms

– Breastfeeding tiredness: YES NO

– Dyspnea: YES (class I II III IV) NO

– Height-weight growth delay: YES NO

4. Physical symptoms

– Weight (kg):

– Heart rate: Normal Tachycardia

– Cyanosis: YES NO

– Heart murmur: YES (type/location) NO

– Global or right heart failure syndrome: YES NO

5. Paraclinical data

5.1. Electrocardiogram:

– NSR (normal sinus rhythm) YES NO

– RV Hypertrophy: YES NO

– LV Hypertrophy: YES NO

– Right bundle branch block: YES (Complete/Incomplete) NO

5.2. Echocardiography:

– VSD: Number: Type Size:

– Isolated: YES NO

- If not, other cardiac congenital anomalies associated with the VSD:

Fallot Tetralogy	Pulmonary stenosis	PDA (patent ductus arteriosus)
ASD		
- Preoperative TR: TR 0 TR 1+ TR 2+ TR 3+ TR 4+
- Pulmonary artery pressure: Normal Pulmonary hypertension
- In case of pulmonary hypertension: moderate severe fixed

II. Surgical treatment:

1. Intraoperative assessment:

- VSD: Number: Type: Size:
- Isolated: YES NO
- If not, other cardiac congenital anomalies associated with the VSD:

Tetralogy of Fallot (TOF)	Pulmonary stenosis
PDA (patent ductus arteriosus)	ASD

2. Surgical procedures:

- Tricuspid valve detachment: Septal Leaflet Anterior Leaflet
- Patch used for the VSD closure: Autologous pericardium Synthetic Biologic
- Additional procedures:
 - Infundibular stenosis resection: YES NO
 - Pulmonary commissurotomy: YES NO
 - Pulmonary artery enlargement: YES NO
 - ASD closure: YES NO
 - Patent ductus arteriosus ligation: YES NO
- Cardiopulmonary bypass time (min):
- Aortic cross-clamp time (min):
- Tricuspid test at the end of the intervention: Tricuspid valve not leaking Tricuspid leak
 - In case of tricuspid leak: Trivial leak Mild leak Moderate leak

III. Postoperative Evolution

1. Immediate postoperative aftermath:

- Surgery Aftermath: Simple Complications
 - Types of complications: Death AVB Heart Arrhythmia
 - Infectious complications Bleeding Hemodynamic disorders
- Intubation time (hours):
- Intensive care unit stay (days):
- Hospitalization stay (days):

2. Postoperative assessment before discharge:

2.1. Electrocardiogram:

- NSR (normal sinus rhythm): YES NO
- AVB : YES NO
 - If yes, the AVB is: Transient Permanent (Pacemaker placed)
- Right bundle block: YES (Complete/incomplete) NO

2.2. Echocardiography:

- Residual VSD: YES NO
 - If Yes: Small Medium Large, requiring reoperation
- Tricuspid Insufficiency: YES NO
 - If Yes: Trivial Mild Moderate Severe
- Pulmonary hypertension: YES NO
 - If Yes: Mild Moderate Severe

3. Postoperative assessment at 6 months:

3.1. Electrocardiogram:

- NSR (normal sinus rhythm): YES NO
- AVB : YES NO
 - If yes, the AVB is: Transient Permanent (Pacemaker placed)
- Right bundle block: YES (Complete/incomplete) NO

3.2. Echocardiography:

- Residual VSD: YES NO
 - If Yes: Small Medium Large, requiring reoperation
- Tricuspid Regurgitation: YES NO
 - If Yes: Trivial Mild Moderate Severe
- Pulmonary hypertension: YES NO
 - If Yes: Mild Moderate Severe

4. Long term follow-up:

- Time lapse between Surgery and latest follow up (Years):

4.1. Electrocardiogram:

- NSR (normal sinus rhythm): YES NO
- AVB: YES NO
 - If yes, the AVB is: Transient Permanent (Pacemaker placed)
- Right bundle block: YES (Complete/incomplete) NO

4.2. Echocardiography:

- Residual VSD: YES NO
 - If Yes: Small Medium Large, requiring reoperation
- Tricuspid Regurgitation: YES NO
 - If Yes: Trivial Mild Moderate Severe
- Pulmonary hypertension: YES NO
 - If Yes: Mild Moderate Severe



ABSTRACTS



Abstract

Introduction: the ventricular septal defect is a congenital malformation where there is a defect in the interventricular septum of the heart. During the surgical treatment, a right atriotomy approach is the gold standard. However, in some cases the chordae attachments conceal the margins of the VSD or the VSD has an outlet extension in an upper position.

Therefore, a partial TVD is performed to allow both an optimal exposure of the VSD and avoid a distortion of the TV or conduction tissue injury.

The purpose of this endeavour is to assess the long-term outcomes of the patients who underwent surgery for VSD closure of their VSDs with a partial TVD by mainly focusing on the following elements: the frequency of residual VSDs, the frequency and severity of the TR at long-term and the occurrence of complete AVB.

Patients and Methods: we undertook a retrospective, single center and descriptive study of the data of 28 patients who underwent surgery for VSD closure spanning on a period of 10 years from July 2010 to August 2020 in the cardiovascular surgery department at the University hospital Mohammed VI. The patients were followed-up at 1, 3, 6 and 12 months and annually up to 8 years postoperatively. The collected data was recorded using Microsoft Excel 2010 and analysed using SPSS 21.0 version.

Results: the mean age was 5.8 ± 4.88 years with a 1.77 sex ratio. In addition, 21 (75%) patients had a perimembranous VSD and the mean VSD diameter was 11.38 ± 4.83 mm. The VSD was isolated for 12 (42.8%) patients, a component of the Fallot's tetralogy for 8 (28.6%) patients, associated with an ASD for 4 (14.3%) patients and with a pulmonary stenosis for 4 (14.3%) patients. The autologous pericardium patch was used for closing the VSD for 22 (78.6%) patients. There was neither any death nor a complete heart block recorded during ICU or hospital stay after surgery. And no severe TR was recorded before discharge.

At a mean follow-up of 4.4 ± 2.5 years: no AVB was found, 24 (85.7%) patients did not have a residual VSD while 3 (10.7%) had a small, hemodynamically meaningless one and 1(3.6%) patient had a large residual VSD requiring reoperation. In addition, 25 (89.3%) patients did not have a TR, 2 (7.1%) patients had a trivial TR (TR1+) and 1(3.6%) patient had a mild TR (TR2+).

Conclusion: Our results are in accordance with the literature. We recommend this technique for the surgical closure of the VSD as we have seen that it provides good results in regards to the optimal and definitive closure of the VSD without an increased risk of neither severe TR nor damage to the conduction tissue.

Résumé

Introduction : La communication interventriculaire est une malformation congénitale caractérisée par la présence d'un défaut dans le septum interventriculaire du cœur. Lors du traitement chirurgical, l'atriotomie droite est la voie d'abord de référence. Néanmoins, dans certains cas les bords de la CIV sont masqués par l'insertion des cordages ou la CIV a une extension infundibulaire dans la partie supérieure du septum.

D'où le besoin d'avoir recours au détachement partiel de la valve tricuspide afin de garantir une meilleure exposition de la CIV mais aussi pour éviter d'endommager la valve tricuspide ou de léser le tissu de conduction.

Le but de ce travail est d'évaluer les résultats à long terme de la désinsertion de la valve tricuspide chez des patients opérés pour fermeture de CIV avec un détachement partiel de la valve tricuspide en se focalisant surtout sur les éléments suivants : la fréquence des CIV résiduelles, la fréquence de l'insuffisance tricuspide à long terme ainsi que la fréquence des blocs auriculo-ventriculaires.

Matériels et méthodes : il s'agit d'une étude rétrospective, monocentrée, et descriptive des données de 28 patients opérés pour fermeture de CIV sur une période de 10 ans allant de Juillet 2010 à Août 2020 dans le service de chirurgie cardiovasculaire du CHU Mohammed VI. Les patients ont été revus à 1, 3, 6 et 12 mois post-opératoires puis annuellement jusqu'à 8 ans. Les données collectées ont été enregistrées sur Microsoft Excel 2010 puis analysées avec le logiciel SPSS version 21.0.

Résultats : l'âge moyen était de $5,8 \pm 4,88$ ans avec un sex-ratio de 1,77. Aussi, 21 (75%) patients avaient une CIV périmembraneuse avec une taille moyenne de la CIV de $11,38 \pm 4,83$ mm. La CIV était isolée chez 12 (42,8%) patients, était une composante d'une tétralogie de Fallot chez 8 (28.6%) patients, associée à une communication interauriculaire chez 4 (14.3%) patients et à une sténose pulmonaire chez 4 (14.3%) patients. Le patch péricardique autologue a été utilisé

pour fermer la CIV chez 22 (78.6%) patients. Aucun décès ni complications sévères ne sont apparus lors du séjour en soins intensifs ou en hospitalisation postopératoire. Aucun cas d'insuffisance tricuspide avant la sortie n'a été enregistrée non plus.

Avec un suivi moyen de $4,4 \pm 2,5$ as : aucun patient n'a développé un bloc auriculo-ventriculaire, 24 (85,7%) patients n'avaient pas de CIV résiduelle tandis que 3 (10.7%) patients avaient une CIV résiduelle minime n'occasionnant pas de shunt et 1 (3.6%) patient avait une CIV résiduelle large nécessitant une reopération. De plus, 25 (89.3%) patients n'avaient pas d'insuffisance tricuspide, 2 (7.1%) patients avaient une insuffisance tricuspide insignifiante et 1 (3.6%) patient avait une insuffisance tricuspide minime.

Conclusion : Nos résultats sont en accord avec les données de la littérature. Nous recommandons l'utilisation de cette technique puisqu'elle permet une fermeture optimale et définitive de la CIV sans entraîner un risque accru ni d'insuffisance tricuspide ni de lésion du tissu de conduction.

ملخص

المقدمة:الاتصال البطيني هو عيب خلقي يتميز بوجود خلل على شكل ثقب في الحاجز بين البطينين للقلب يؤدي إلى اتصالهما. أثناء العلاج الجراحي ، يعتبر شق الأذين الأيمن هو الأسلوب الأكثر إستعمالاً. ومع ذلك ، في بعض الحالات ، يتم حجب حواف هذا الإتصال بسبب تموقع حبال الصمام ثلاثي الشرف او ان لهذا الصمام امتداد نحو الجزء العلوي من الحاجز .

ومن هنا تأتي الحاجة إلى اللجوء إلى الفصل الجزئي للصمام ثلاثي الشرف من أجل ضمان انكشاف أفضل لهذا الإتصال البطيني ولكن أيضاً لتجنب إتلاف الصمام ثلاثي الشرف أو إتلاف أنسجة التوصيل الكهربائي للقلب. الهدف من هذا العمل هو تقييم النتائج طويلة المدى لدى المرضى الذين خضعوا لجراحة إغلاق الإتصال التشوهي الخلفي بين البطينين بإستعمال الفصل الجزئي للصمام ثلاثي الشرف من خلال التركيز بشكل أساسي على العناصر التالية: عدد حالات الإتصال التشوهي الخلفي بين البطينين، عدد حالات قصور ثلاثي الشرف على المدى البعيد وكذلك تواتر حالات الحصار الأذينية البطينية.

المواد والطرق: هذه دراسة بأثر رجعي ، لمركز واحد ، وصفية لبيانات 28 مريضاً تم إجراء جراحة إغلاق الإتصال التشوهي الخلفي بين البطينين على مدى 10 سنوات من يوليو 2010 إلى أغسطس 2020 في قسم جراحة القلب والأوعية الدموية في المستشفى الجامعي محمد السادس. تمت مراجعة المرضى في الشهر الأول، الثالث، السادس و الثاني عشر بعد الجراحة ثم سنوياً لمدة تصل إلى 8 سنوات. تم تسجيل البيانات التي تم جمعها في نظام إكسيل 2010 المعلوماتي ثم تحليلها باستخدام برنامج SPSS الإصدار 21.0 .

النتائج: كان متوسط العمر 4.88 ± 5.8 سنة بنسبة جنس الذكور/الإناث 1.77. كان لدى 21 (75%) مريضاً إتصال بمتوسط حجم يبلغ 4.83 ± 11.38 ملم. في 12 مريضاً (42.8%) لم يكن لديهم تشوهات إضافية ما عدا الإتصال البطين. كان هذا الإتصال البطيني أحد مكونات رباعية فالو في 8 (28.6%) حالات ، مرتبط بالتواصل بين الأذنين لدى 4 (14.3%) مرضى وتضييق رئوي لدى 4 (14.3%) آخرين. تم استخدام رقعة التامور الذاتية لإغلاق الإتصال لدى 22 مريضاً (78.6%). لم تحدث وفاة أو مضاعفات خطيرة في العناية المركزة أو الاستشفاء بعد الجراحة. لم يتم تسجيل أي حالة قصور لصمام ثلاثي الشرفات قبل مغادرة المرضى للمستشفى.

بمتوسط متابعة 2.5 ± 4.4 : لم يصب أي مريض بإحصار أذيني بطيني ، لم يكن لدى 24 (85.7%) مريض أي إتصال متبق، بينما تبقى لدى 3 (10.7%) مرضى إتصال صغير دون أي تأثير على المريض. ومريض

واحد (3.6%) تبين أن الإتصال المتبقي يحتاج إعادة الجراحة . بالإضافة إلى ذلك ، لم يكن لدى 25 (89.3%) من المرضى قصور للصمام ثلاثي الشرفات ،بينما مريضين (7.1%) يعانون من قصور غير ملحوظ في الصمام ثلاثي الشرف و مريض واحد (3.6%) يعاني من قصور من الحد الأدنى من الصمام ثلاثي الشرف .

الخلاصة: نتائجنا تتفق مع البيانات الموجودة في الأدبيات . نوصي باستخدام هذه التقنية لأنها تتيح الإغلاق الأمثل والنهائي للإتصال التشوهي الخلقي بين البطينين دون التسبب في حدوث خطر إضافي لقصور الصمام ثلاثي الشرفات أو تلف أنسجة التوصيل الكهربائي القلبي .



REFERENCES



1. **Hoffman JI, Kaplan S.**
The incidence of congenital heart disease. *J Am Coll Cardiol.* 2002;39:1890–900.
2. **Hudspeth AS, Cordell AR, Meredith JH, et al.**
An improved trans- atrial approach to the closure of ventricular septal defects. *J Thorac Cardiovasc Surg.* 1962;43:157–65.
3. **Koshy S, Sunil GS, Anil SR, et al.**
Tricuspid valve detachment for transatrial closure of ventricular septal defects. *Asian Cardiovasc Thorac Ann.* 2002;10:314–7.
4. **Russell HM, Forsberg K, Backer CL, et al.**
Outcomes of radial incision of the tricuspid valve for ventricular septal defect closure. *Ann Thorac Surg.* 2011;92:685–90.
5. **Merrick AF, Lal M, Anderson RH, Shore DF.**
Management of ventricular septal defect: a survey of practice in the United Kingdom. *Ann Thorac Surg.* 1999;68:983–8.
6. **Zoghbi WA, Adams D, Bonow RO, et al.**
Recommendations for non-invasive evaluation of native valvular regurgitation: a report from the American Society of Echocardiography developed in collaboration with the Society for Cardiovascular Magnetic Resonance. *J Am Soc Echocardiogr.* 2017;30:303–71.
7. **Gaynor JW, O'Brien JE Jr, Rychik J, et al.**
Outcome following tricuspid valve detachment for ventricular septal defects closure. *Eur J Cardiothorac Surg.* 2001;19:279–82.
8. **Chivers S, Lotto AA.**
Isolated ventricular septal defect. *Cardiac surgery - a complete guide.* Switzerland: Springer nature Edition, 2020:1089. ISBN: 978-3-030-24173-5.
9. **Anderson RH, Wilcox BR.**
The surgical anatomy of ventricular septal defect. *J Card Surg.* 1992;7:17–35.
10. **Chantepie A.**
Communications interventriculaires. *EMC Cardiologie - Angéiologie.* 2005;2:202–30. doi: 10.1016/j.emcaa.2005.03.001.
11. **Mzaalat TO.**
Le traitement chirurgical des communications interventriculaires (à propos de 111 cas). Thèse de Médecine, N°134, 2019. Fès.

12. **Ling Y, Bian X, Wang Y, Qian Y.**
Does tricuspid valve detachment improve outcomes compared with the non-tricuspid valve detachment approach in ventricular septal defect closure? *Interact CardioVasc Thorac Surg.* 2021;32:483–8.
13. **Zhao J, Li J, Wei X, Zhao B, Sun W.**
Tricuspid valve detachment in closure of congenital ventricular septal defect. *Tex Heart Inst J.* 2003;30:38–41.
14. **Sasson L, Katz MG, Ezri T, et al.**
Indications for tricuspid valve detachment in closure of ventricular septal defect in children. *Ann Thorac Surg.* 2006;82:958–63.
15. **Lucchese G, Rossetti L, Faggian G, et al.**
Long-term follow-up study of temporary tricuspid valve detachment as approach to VSD repair without consequent tricuspid dysfunction. *Tex Heart Inst J.* 2016;43:392–96.
16. **Bilen C, Akkaya G, Tuncer ON, and Atal Y.**
Assessment of tricuspid valve detachment efficiency for ventricular septal defect closure: a retrospective comparative study. *Acta Cardiol Sin.* 2020;36:360–66.
17. **Riaz MU, Waqar T, Baig MAR.**
Comparison of postoperative outcomes with and without tricuspid leaflet detachment in patients undergoing ventricular septal defect repairs. *J postgrad Med Inst.* 2017;31(3): 247–50.
18. **Fraser CD, Zhou X, Palepu S, et al.**
Tricuspid valve detachment in ventricular septal defect closure does not impact valve function. *The Annals of Thoracic Surgery.* 2018;106:145–50.
19. **Pourmoghadam KK, Boron A, Ruzmetov M, et al.**
Septal leaflet versus chordal detachment in closure of hard-to-expose ventricular septal defects. *Ann Thorac Surg.* 2018;106:814–21.
20. **Weymann A, Georgiev S, Vogelsang C, et al.**
Temporary tricuspid valve detachment for ventricular septal defect closure: is it worth doing it? *Heart Surg Forum.* 2013;16:99–102.
21. **Giordano R, Cantinotti M, Di Tommaso L, et al.**
The fate of the tricuspid valve after the transatrial closure of the ventricular septal defect. *Ann Thorac Surg.* 2018;106:1229–33.

22. **Bang JH, Park CS, Park JJ, et al.**
Detachment of the tricuspid valve for ventricular septal defect closure in infants younger than 3 months old. *Ann Thorac Surg.* 2016;152:491–6.
23. **Aeba R, Katogi T, Hashizume K, et al.**
Liberal use of tricuspid valve detachment for transatrial ventricular septal defect closure. *Ann Thorac Surg.* 2003;76:1073–7.
24. **Andersen HO, De Leval MR, Tsang VT, et al.**
Is complete heart block after surgical closure of ventricular septum defects still an issue? *Ann Thorac Surg.* 2006;82:948–56.
25. **Bilen C, Akkaya G, Tuncer ON, Atal Y.**
Success of Tricuspid valve detachment for ventricular septal defect closure: an assessment of midterm tricuspid valve function. *J Basic Clin Health Sci.*2019;3:69–72.
<https://doi.org/10.30621/jbachs.2019.586>
26. **Roughneen PT, Conti VR.**
Tricuspid septal leaflet detachment for ventricular septal defect repair in adults. *Ann Thorac Surg.* 2016;102:93–5.
27. **Mahgoub A, Kamel H, Simry W and Hosny H.**
Repair of very severe tricuspid regurgitation following detachment of the tricuspid valve. *Global Cardiology Science and Practice* 2015:14. <http://dx.doi.org/10.539/gcsp.2015.14>
28. **Lin YJ, Chang JP, Chien SJ, et al.**
Novel method for evaluating tricuspid valve function after tricuspid valve detachment in the repair of perimembranous ventricular septal defects. *Tex Heart Inst J.* 2012;39:806–8.
29. **Sahin MA, Güler A, Cingöz F, et al.**
The chordal detachment method in a ventricular septal defect repair. *T G K Damar Cerrahisi Dergisi.* 2012;20(3):636–37.
30. **Tateishi A, Kawada M, Takeuchi M, et al.**
Radial incision for ven- tricular septal defect with membranous septal aneurysm. *Asian Cardio- vasc Thorac Ann.* 2010;18:250–2.

31. **Neeraj K, Sunil D, Rajat A, et al.**
Temporary tricuspid valve leaflet detachment for closure of perimembranous ventricular septal defect: early experiences. *Ind J Thorac Cardiovasc Surg.* 2009;25:49–51.
32. **Maile S, Kadner A, Turina MI, et al.**
Detachment of the anterior leaflet of the tricuspid valve to expose perimembranous ventricular septal defects. *Ann Thorac Surg.* 2003;75:944–6.
33. **Bol–Raap G, Weerheim J, Kappetein AP, Witsenburg M, Bogers AJ.**
Follow–up after surgical closure of congenital ventricular septal defect. *Eur J Cardiothorac Surg.* 2003;24:511–5.
34. **Tatebe S, Miyamura H, Watanabe H, Sugawara M, Eguchi S.**
Closure of isolated ventricular septal defect with detachment of the tricuspid valve. *J Card Surg.* 1995;10:564–8.
35. **Pridjian AK, Pearce FB, Culpepper WS, et al.**
Atrioventricular valve competence after takedown to improve exposure during ventricular septal defect repair. *J Thorac Cardiovasc Surg.* 1993;106:1122–5.
36. **Frenckner BP, Olin CL, Bomfim V, et al.**
Detachment of the septal tricuspid leaflet during transatrial closure of isolated ventricular septal defect. *J Thorac Cardiovasc Surg.* 1981;82:773–8.
37. **Anderson BR, Stevens KN, Nicolson SC, et al.**
Contemporary outcomes of surgical ventricular septal defect closure. *J Thorac Cardiovasc Surg.* 2013;145:641–7.
38. **Kasar T, Cansaran Tanidir I, Ozturk E, et al.**
Cardiac catheterization in the early post–operative period after congenital heart surgery. *Acta Cardiol Sin.* 2018;34:481–7.
39. **Siehr SL, Hanley FL, Reddy VM, et al.**
Incidence and risk factors of complete atrioventricular block after operative ventricular septal defect repair. *Congenit Heart Dis.* 2014;9:211–5.
40. **Scully BB, Morales DL, Zafar F, et al.**
Current expectations for surgical repair of isolated ventricular septal defects. *Ann Thorac Surg.* 2010;89:544–51.

41. **Tucker EM, Pyles LA, Bass JL, Moller JH.**
Permanent pacemaker for atrioventricular conduction block after operative repair of perimembranous ventricular septal defect. *J Am Coll Cardiol.* 2007;50:1196–200.
42. **Dodge–Khatami A, Knirsch W, Tomaske M, et al.**
Spontaneous closure of small residual ventricular septal defects after surgical repair. *Ann Thorac Surg.* 2007;83:902–5.
43. **Tribak M, Marmade L, El Kouache M, et al.**
Résultats de la fermeture chirurgicale des communications interventriculaires à tous les âges. A propos de 30 cas. *Annales de Cardiologie et d'Angéiologie.* 2008;57:48–51.
44. **Bendriss L, Sedrati M, Haddour L, et al.**
Communications interventriculaires : aspects anatomiques, thérapeutiques et évolutifs. *Presse Med.* 2006;35:593–7.
45. **Gabriel HM, Heger M, Innerhofer P, et al.**
Long-term outcome of patients with ventricular septal defect considered not to require surgical closure during childhood. *J Am Coll Cardiol.* 2002;39:1066–71.
46. **Kapoor L, Gan MD, Bandyhopadhyay A, et al.**
Improved exposure of isolated perimembranous ventricular septal defects. *Ann Thorac Surg.* 2000;69:291–2.
47. **McGrath LB.**
Methods for repair of simple isolated ventricular septal defect. *J Card Surg.* 1991;6(1):13–23.

قسم الطبيب

أقسم بالله العظيم

أن أراقب الله في مهنتي.

وأن أصون حياة الإنسان في كافة أطوارها في كل الظروف

والأحوال باذلاً وسعي في انقاذها من الهلاك والمرض

والألم والقلق.

وأن أحفظ للناس كرامتهم، وأستر عورتهم، وأكتم سرهم.

وأن أكون على الدوام من وسائل رحمة الله، باذلاً رعايتي الطبية للقريب والبعيد،

للصالح والطالح، والصديق والعدو.

وأن أثار على طلب العلم، أسخره لنفع الإنسان .. لا لأذاه.

وأن أوقر من علمني، وأعلم من يصغرنني، وأكون أخاً لكل زميل في المهنة الطبية

متعاونين على البر والتقوى.

وأن تكون حياتي مصداق إيماني في سري وعلانيتي، نقيّة مما يشينها تجاه

الله ورسوله والمؤمنين.

والله على ما أقول شهيدا



كلية الطب
والصيدلة - مراكش
FACULTÉ DE MÉDECINE
ET DE PHARMACIE - MARRAKECH

أطروحة رقم 215

سنة 2021

نتائج الفصل الجزئي للصمام ثلاثي الشرف أثناء إغلاق الإتصال الخلقي بين البطينين

الأطروحة

قدمت ونوقشت علانية يوم 2021/12/02

من طرف

السيد أصونصيون إكور رانكوزا

المزداد في 28 ماي 1992 في بوروندي

لنيل شهادة الدكتوراه في الطب

الكلمات الأساسية:

فصل الصمام ثلاثي الشرف - إتصال تشوهي خلقي بين البطينين - نتائج.

اللجنة

الرئيس

ن. الوالي الادريسي سنيطين

السيدة

أستاذة في طب الأطفال

المشرف

د. بومزبرة

السيد

أستاذ في جراحة القلب والشرابين

الحكم

ر. الحواتي

السيد

أستاذ مبرز في جراحة القلب والشرابين