

Year : 2021

Thesis N°: 428

DUNN TECHNIQUE IN TREATMENT OF SLIPPED CAPITAL FEMORAL EPIPHYSIS

THESIS

Publicly submitted and defended on the : / /2021

BY

Mrs. Houda BOUIDIDA

Born on October 26th, 1996 in Casablanca

FOR THE DEGREE OF **Doctor of Medicine**

Key Words : Slipped capital femoral epiphysis; Dunn procedure;
Subcapital realignment; Avascular necrosis

Jury Members:

Mr. Mohammed Anouar DENDANE

Professor of Pediatric Orthopedic Surgery

Mr. Abdelouahed AMRANI

Professor of Pediatric Orthopedic Surgery

Mrs. Naima EL HAFIDI

Professor of Pediatrics

Mr. Rachid ABILKASSEM

Professor of Pediatrics

President

Director

Member

Member

بِسْمِ اللَّهِ الرَّحْمَنِ الرَّحِيمِ



وَفِي أَنْفُسِكُمْ أَفَلَا تُبْصِرُونَ



بِسْمِ اللَّهِ
الرَّحْمَنِ الرَّحِيمِ

سورة الذاريات: الآية: 21



UNIVERSITE MOHAMMED V

FACULTE DE MEDECINE ET DE PHARMACIE

RABAT

DOYENS HONORAIRES :

1962 - 1969: Professeur Abdelmalek FARAJ
1969 - 1974: Professeur Abdellatif BERBICH
1974 - 1981: Professeur Bachir LAZRAK
1981 - 1989: Professeur Taieb CHKILI
1989 - 1997: Professeur Mohamed Tahar ALAOUI
1997 - 2003: Professeur Abdelmajid BELMAHI
2003 - 2013: Professeur Najia HAJJAJ - HASSOUNI

ADMINISTRATION :

Doyen :
Professeur Mohamed ADNAOUI

Vice-Doyen chargé des Affaires Académiques et estudiantines
Professeur Brahim LEKEHAL

Vice-Doyen chargé de la Recherche et de la Coopération
Professeur Taoufiq DAKKA

Vice-Doyen chargé des Affaires Spécifiques à la Pharmacie
Professeur Younes RAHALI

Secrétaire Général
Mr. Mohamed KARRA

*Enseignant militaire

**1 - ENSEIGNANTS-CHERCHEURS MEDECINS ET PHARMACIENS
PROFESSEURS DE L'ENSEIGNEMENT SUPERIEUR :**

Décembre 1984

Pr. MAAOUNI Abdelaziz
Pr. MAAZOUZI Ahmed Wajdi
Pr. SETTAF Abdellatif

Décembre 1989

Pr. ADNAOUI Mohamed
Pr. OUZZANI Taïbi Mohamed Réda

Janvier et Novembre 1990

Pr. KHARBACH Aïcha
Pr. TAZI Saoud Anas

Février Avril Juillet et Décembre 1991

Pr. AZZOUZI Abderrahim
Pr. BAYAHIA Rabéa
Pr. BELKOUCHI Abdelkader
Pr. BENSOUA Yahia
Pr. BERRAHO Amina
Pr. BEZAD Rachid
Pr. CHERRAH Yahia
Pr. CHOKAIRI Omar
Pr. KHATTAB Mohamed
Pr. SOULAYMANI Rachida
Pr. TAOUFIK Jamal

Décembre 1992

Pr. AHALLAT Mohamed
Pr. BENSOUA Adil
Pr. CHAHED OUZZANI Laaziza
Pr. CHRAIBI Chafiq
Pr. EL OUAHABI Abdessamad
Pr. FELLAT Rokaya
Pr. JIDDANE Mohamed
Pr. ZOUHDI Mimoun

Mars 1994

Pr. BENJAAFAR Noureddine
Pr. BEN RAIS Nozha
Pr. CAOUI Malika
Pr. CHRAIBI Abdelmjid
Pr. EL AMRANI Sabah
Pr. ERROUGANI Abdelkader
Pr. ESSAKALI Malika
Pr. ETTAYEBI Fouad
Pr. IFRINE Lahssan
Pr. RHRAB Brahim
Pr. SENOUCI Karima

Mars 1994

Pr. ABBAR Mohamed*
Pr. BENTAHILA Abdelali
Pr. BERRADA Mohamed Saleh
Pr. CHERKAOUI Lalla Ouafae
Pr. LAKHDAR Amina
Pr. MOUANE Nezha

Médecine Interne - [Clinique Royale](#)
Anesthésie - Réanimation
Pathologie Chirurgicale

Médecine Interne - [Doyen de la FMPR](#)
Neurologie

Gynécologie - Obstétrique
Anesthésie Réanimation

Anesthésie Réanimation
Néphrologie
Chirurgie Générale
Pharmacie galénique
Ophtalmologie
Gynécologie Obstétrique Méd. [Chef Maternité des Orangers](#)
Pharmacologie
Histologie Embryologie
Pédiatrie
Pharmacologie- [Dir. du Centre National PV Rabat](#)
Chimie thérapeutique

Chirurgie Générale [Doyen de FMPT](#)
Anesthésie Réanimation
Gastro-Entérologie
Gynécologie Obstétrique
Neurochirurgie
Cardiologie
Anatomie
Microbiologie

Radiothérapie
Biophysique
Biophysique
Endocrinologie et Maladies Métaboliques [Doyen de la FMPA](#)
Gynécologie Obstétrique
Chirurgie Générale - [Directeur du CHIS](#)
Immunologie
Chirurgie Pédiatrique
Chirurgie Générale
Gynécologie - Obstétrique
Dermatologie

Urologie [Inspecteur du SSM](#)
Pédiatrie
Traumatologie - Orthopédie
Ophtalmologie
Gynécologie Obstétrique
Pédiatrie

*Enseignant militaire

Mars 1995

Pr. ABOUQUAL Redouane
Pr. AMRAOUI Mohamed
Pr. BAIDADA Abdelaziz
Pr. BARGACH Samir
Pr. EL MESNAOUI Abbes
Pr. ESSAKALI HOUSSYNI Leila
Pr. IBEN ATTYA ANDALOUSSI Ahmed
Pr. OUZZANI CHAHDI Bahia
Pr. SEFIANI Abdelaziz
Pr. ZEGGWAGH Amine Ali

Décembre 1996

Pr. BELKACEM Rachid
Pr. BOULANOUI Abdelkrim
Pr. EL ALAMI EL FARICHA EL Hassan
Pr. GAOUZI Ahmed
Pr. OUZEDDOUN Naima
Pr. ZBIR EL Mehdi*

Novembre 1997

Pr. ALAMI Mohamed Hassan
Pr. BIROUK Nazha
Pr. FELLAT Nadia
Pr. KADDOURI Nouredine
Pr. KOUTANI Abdellatif
Pr. LAHLOU Mohamed Khalid
Pr. MAHRAOUI CHAFIQ
Pr. TOUFIQ Jallal
Pr. YOUSFI MALKI Mounia

Novembre 1998

Pr. BENOMAR ALI
Pr. BOUGTAB Abdesslam
Pr. ER RIHANI Hassan
Pr. BENKIRANE Majid*

Janvier 2000

Pr. ABID Ahmed*
Pr. AIT OUAMAR Hassan
Pr. BENJELLOUN Dakhama Badr Sououd
Pr. BOURKADI Jamal-Eddine
Pr. CHARIF CHEFCHAOUNI Al Montacer
Pr. ECHARRAB El Mahjoub
Pr. EL FTOUH Mustapha
Pr. EL MOSTARCHID Brahim*
Pr. TACHINANTE Rajae
Pr. TAZI MEZALEK Zoubida

Novembre 2000

Pr. AIDI Saadia
Pr. AJANA Fatima Zohra
Pr. BENAMR Said
Pr. CHERTI Mohammed
Pr. ECH-CHERIF EL KETTANI Selma
Pr. EL HASSANI Amine
Pr. EL KHADER Khalid
Pr. GHARBI Mohamed El Hassan
Pr. MDAGHRI ALAOUI Asmae

Réanimation Médicale
Chirurgie Générale
Gynécologie Obstétrique
Gynécologie Obstétrique
Chirurgie Générale
Oto-Rhino-Laryngologie
Urologie
Ophtalmologie
Génétique
Réanimation Médicale

Chirurgie Pédiatrie
Ophtalmologie
Chirurgie Générale
Pédiatrie
Néphrologie
Cardiologie [Directeur HMI Mohammed V](#)

Gynécologie-Obstétrique
Neurologie
Cardiologie
Chirurgie Pédiatrique
Urologie
Chirurgie Générale
Pédiatrie
Psychiatrie [Directeur Hôp.Ar-razi Salé](#)
Gynécologie Obstétrique

Neurologie Doyen de la FMP Abulcassis
Chirurgie Générale
Oncologie Médicale
Hématologie

Pneumo-phtisiologie
Pédiatrie
Pédiatrie
Pneumo-phtisiologie
Chirurgie Générale
Chirurgie Générale
Pneumo-phtisiologie
Neurochirurgie
Anesthésie-Réanimation
Médecine Interne

Neurologie
Gastro-Entérologie
Chirurgie Générale
Cardiologie
Anesthésie-Réanimation
Pédiatrie - [Directeur Hôp.Cheikh Zaid](#)
Urologie
Endocrinologie et Maladies Métaboliques
Pédiatrie

*Enseignant militaire

Décembre 2001

Pr. BALKHI Hicham*
Pr. BENABDELJLIL Maria
Pr. BENAMAR Loubna
Pr. BENAMOR Jouda
Pr. BENELBARHDADI Imane
Pr. BENNANI Rajae
Pr. BENOUACHANE Thami
Pr. BEZZA Ahmed*
Pr. BOUCHIKHI IDRISSE Med Larbi
Pr. BOUMDIN El Hassane*
Pr. CHAT Latifa
Pr. EL HIJRI Ahmed
Pr. EL MAAQILI Moulay Rachid
Pr. EL MADHI Tarik
Pr. EL OUNANI Mohamed
Pr. ETTAIR Said
Pr. GAZZAZ Miloudi*
Pr. HRORA Abdelmalek
Pr. KABIRI EL Hassane*
Pr. LAMRANI Moulay Omar
Pr. LEKEHAL Brahim
Pr. MEDARHRI Jalil
Pr. MIKDAME Mohammed*
Pr. MOHSINE Raouf
Pr. NOUINI Yassine
Pr. SABBAAH Farid
Pr. SEFIANI Yasser
Pr. TAOUFIQ BENCHEKROUN Soumia

Décembre 2002

Pr. AMEUR Ahmed *
Pr. AMRI Rachida
Pr. AOURARH Aziz*
Pr. BAMOU Youssef *
Pr. BELMEJDOUB Ghizlene*
Pr. BENZEKRI Laila
Pr. BENZZOUBEIR Nadia
Pr. BERNOUSSI Zakiya
Pr. CHOHO Abdelkrim *
Pr. CHKIRATE Bouchra
Pr. EL ALAMI EL Fellous Sidi Zouhair
Pr. FILALI ADIB Abdelhai
Pr. HAJJI Zakia
Pr. KRIOUILE Yamina
Pr. OUJILAL Abdelilah
Pr. RAISS Mohamed
Pr. SIAH Samir *
Pr. THIMOU Amal
Pr. ZENTAR Aziz*

Janvier 2004

Pr. ABDELLAH El Hassan
Pr. AMRANI Mariam
Pr. BENBOUZID Mohammed Anas
Pr. BENKIRANE Ahmed*
Pr. BOULAADAS Malik
Pr. BOURAZZA Ahmed*
Pr. CHAGAR Belkacem*

Anesthésie-Réanimation
Neurologie
Néphrologie
Pneumo-phtisiologie
Gastro-Entérologie
Cardiologie
Pédiatrie
Rhumatologie
Anatomie
Radiologie
Radiologie
Anesthésie-Réanimation
Neuro-Chirurgie
Chirurgie-[Pédiatrique Directeur Hôp. Des Enfants Rabat](#)
Chirurgie Générale
Pédiatrie - [Directeur Hôp. Univ. International \(Cheikh Khalifa\)](#)
Neuro-Chirurgie
Chirurgie Générale [Directeur Hôpital Ibn Sina](#)
Chirurgie Thoracique
Traumatologie Orthopédie
Chirurgie Vasculaire Périphérique [V-D chargé Aff Acad. Est.](#)
Chirurgie Générale
Hématologie Clinique
Chirurgie Générale
Urologie
Chirurgie Générale
Chirurgie Vasculaire Périphérique
Pédiatrie

Urologie
Cardiologie
Gastro-Entérologie
Biochimie-Chimie
Endocrinologie et Maladies Métaboliques
Dermatologie
Gastro-Entérologie
Anatomie Pathologique
Chirurgie Générale
Pédiatrie
Chirurgie Pédiatrique
Gynécologie Obstétrique
Ophtalmologie
Pédiatrie
Oto-Rhino-Laryngologie
Chirurgie Générale
Anesthésie Réanimation
Pédiatrie
Chirurgie Générale

Ophtalmologie
Anatomie Pathologique
Oto-Rhino-Laryngologie
Gastro-Entérologie
Stomatologie et Chirurgie Maxillo-faciale
Neurologie
Traumatologie Orthopédie

*Enseignant militaire

Pr. CHERRADI Nadia
Pr. EL FENNI Jamal*
Pr. EL HANCHI ZAKI
Pr. EL KHORASSANI Mohamed
Pr. HACHI Hafid
Pr. JABOUIRIK Fatima
Pr. KHARMAZ Mohamed
Pr. MOUGHIL Said
Pr. OUBAAZ Abdelbarre *
Pr. TARIB Abdelilah*
Pr. TIJAMI Fouad
Pr. ZARZUR Jamila

Janvier 2005

Pr. ABBASSI Abdellah
Pr. AL KANDRY Sif Eddine*
Pr. ALLALI Fadoua
Pr. AMAZOUZI Abdellah
Pr. BAHIRI Rachid
Pr. BARKAT Amina
Pr. BENYASS Aatif*
Pr. DOUDOUH Abderrahim*
Pr. HAJJI Leila
Pr. HESSISSEN Leila
Pr. JIDAL Mohamed*
Pr. LAAROUSSI Mohamed
Pr. LYAGOUBI Mohammed
Pr. SBIHI Souad
Pr. ZERAIDI Najia

AVRIL 2006

Pr. ACHEMLAL Lahsen*
Pr. BELMEKKI Abdelkader*
Pr. BENCHEIKH Razika
Pr. BOUHAFS Mohamed El Amine
Pr. BOULAHYA Abdellatif*
Pr. CHENGUETI ANSARI Anas
Pr. DOGHMI Nawal
Pr. FELLAT Ibtissam
Pr. FAROUDY Mamoun
Pr. HARMOUCHE Hicham
Pr. IDRIS LAHLOU Amine*
Pr. JROUNDI Laila
Pr. KARMOUNI Tariq
Pr. KILI Amina
Pr. KISRA Hassan
Pr. KISRA Mounir
Pr. LAATIRIS Abdelkader*
Pr. LMIMOUNI Badreddine*
Pr. MANSOURI Hamid*
Pr. OUANASS Abderrazzak
Pr. SAFI Soumaya*
Pr. SOUALHI Mouna
Pr. TELLAL Saida*
Pr. ZAHRAOUI Rachida

Anatomie Pathologique
Radiologie
Gynécologie Obstétrique
Pédiatrie
Chirurgie Générale
Pédiatrie
Traumatologie Orthopédie
Chirurgie Cardio-Vasculaire
Ophtalmologie
Pharmacie Clinique
Chirurgie Générale
Cardiologie

Chirurgie Réparatrice et Plastique
Chirurgie Générale
Rhumatologie
Ophtalmologie
Rhumatologie **Directeur Hôp. Al Ayachi Salé**
Pédiatrie
Cardiologie
Biophysique
Cardiologie (mise en disponibilité)
Pédiatrie
Radiologie
Chirurgie Cardio-vasculaire
Parasitologie
Histo-Embryologie Cytogénétique
Gynécologie Obstétrique

Rhumatologie
Hématologie
O.R.L
Chirurgie - Pédiatrique
Chirurgie Cardio – Vasculaire. **Directeur Hôpital Ibn Sina Marr.**
Gynécologie Obstétrique
Cardiologie
Cardiologie
Anesthésie Réanimation
Médecine Interne
Microbiologie
Radiologie
Urologie
Pédiatrie
Psychiatrie
Chirurgie – Pédiatrique
Pharmacie Galénique
Parasitologie
Radiothérapie
Psychiatrie
Endocrinologie
Pneumo – Phtisiologie
Biochimie
Pneumo – Phtisiologie

*Enseignant militaire

Octobre 2007

Pr. ABIDI Khalid
Pr. ACHACHI Leila
Pr. AMHAJJI Larbi *
Pr. AOUI Sarra
Pr. BAITE Abdelouahed *
Pr. BALOUCH Lhoussaine *
Pr. BENZIANE Hamid *
Pr. BOUTIMZINE Nourdine
Pr. CHERKAOUI Naoual *
Pr. EL BEKKALI Youssef *
Pr. EL ABSI Mohamed
Pr. EL MOUSSAOUI Rachid
Pr. EL OMARI Fatima
Pr. GHARIB Nouredine
Pr. HADADI Khalid *
Pr. ICHOU Mohamed *
Pr. ISMAILI Nadia
Pr. KEBDANI Tayeb
Pr. LOUZI Lhoussain *
Pr. MADANI Naoufel
Pr. MARC Karima
Pr. MASRAR Azlarab
Pr. OUZZIF Ez zohra *
Pr. SEFFAR Myriame
Pr. SEKHSOKH Yessine *
Pr. SIFAT Hassan *
Pr. TACHFOUTI Samira
Pr. TAJDINE Mohammed Tariq*
Pr. TANANE Mansour *
Pr. TLIGUI Houssain
Pr. TOUATI Zakia

Mars 2009

Pr. ABOUZAHIR Ali *
Pr. AGADR Aomar *
Pr. AIT ALI Abdelmounaim *
Pr. AKHADDAR Ali *
Pr. ALLALI Nazik
Pr. AMINE Bouchra
Pr. ARKHA Yassir
Pr. BELYAMANI Lahcen *
Pr. BJIJOU Younes
Pr. BOUHSAIN Sanae *
Pr. BOUI Mohammed *
Pr. BOUNAIM Ahmed *
Pr. BOUSSOUGA Mostapha *
Pr. CHTATA Hassan Toufik *
Pr. DOGHMI Kamal *
Pr. EL MALKI Hadj Omar
Pr. EL OUENNASS Mostapha*
Pr. ENNIBI Khalid *
Pr. FATHI Khalid
Pr. HASSIKOU Hasna *
Pr. KABBAJ Nawal
Pr. KABIRI Meryem
Pr. KARBOUBI Lamyia
Pr. LAMSAOURI Jamal *

Réanimation médicale
Pneumo ptisiologie
Traumatologie orthopédie
Parasitologie
Anesthésie réanimation
Biochimie-chimie
Pharmacie clinique
Ophtalmologie
Pharmacie galénique
Chirurgie cardio-vasculaire
Chirurgie générale
Anesthésie réanimation
Psychiatrie
Chirurgie plastique et réparatrice
Radiothérapie
Oncologie médicale
Dermatologie
Radiothérapie
Microbiologie
Réanimation médicale
Pneumo ptisiologie
Hématologie biologique
Biochimie-chimie
Microbiologie
Microbiologie
Radiothérapie
Ophtalmologie
Chirurgie générale
Traumatologie-orthopédie
Parasitologie
Cardiologie

Médecine interne
Pédiatrie
Chirurgie Générale
Neuro-chirurgie
Radiologie
Rhumatologie
Neuro-chirurgie [Directeur Hôp.des Spécialités](#)
Anesthésie Réanimation
Anatomie
Biochimie-chimie
Dermatologie
Chirurgie Générale
Traumatologie-orthopédie
Chirurgie Vasculaire Périphérique
Hématologie clinique
Chirurgie Générale
Microbiologie
Médecine interne
Gynécologie obstétrique
Rhumatologie
Gastro-entérologie
Pédiatrie
Pédiatrie
Chimie Thérapeutique

*Enseignant militaire

Pr. MARMADE Lahcen
Pr. MESKINI Toufik
Pr. MESSAOUDI Nezhia *
Pr. MSSROURI Rahal
Pr. NASSAR Ittimade
Pr. OUKERRAJ Latifa
Pr. RHORFI Ismail Abderrahmani *

Octobre 2010

Pr. ALILOU Mustapha
Pr. AMEZIANE Taoufiq*
Pr. BELAGUID Abdelaziz
Pr. CHADLI Mariama*
Pr. CHEMSI Mohamed*
Pr. DAMI Abdellah*
Pr. DARBI Abdellatif*
Pr. DENDANE Mohammed Anouar
Pr. EL HAFIDI Naima
Pr. EL KHARRAS Abdennasser*
Pr. EL MAZOUZ Samir
Pr. EL SAYEGH Hachem
Pr. ERRABIH Ikram
Pr. LAMALMI Najat
Pr. MOSADIK Ahlam
Pr. MOUJAHID Mountassir*
Pr. ZOUAIDIA Fouad

Decembre 2010

Pr. ZNATI Kaoutar

Mai 2012

Pr. AMRANI Abdelouahed
Pr. ABOUELALAA Khalil *
Pr. BENCHEBBA Driss *
Pr. DRISSI Mohamed *
Pr. EL ALAOUI MHAMDI Mouna
Pr. EL OUAZZANI Hanane *
Pr. ER-RAJI Mounir
Pr. JAHID Ahmed

Février 2013

Pr. AHID Samir
Pr. AIT EL CADI Mina
Pr. AMRANI HANCI Laila
Pr. AMOR Mourad
Pr. AWAB Almahdi
Pr. BELAYACHI Jihane
Pr. BELKHADIR Zakaria Houssain
Pr. BENCHEKROUN Laila
Pr. BENKIRANE Souad
Pr. BENSGHIR Mustapha *
Pr. BENYAHIA Mohammed *
Pr. BOUATIA Mustapha
Pr. BOUABID Ahmed Salim*
Pr. BOUTARBOUCH Mahjouba
Pr. CHAIB Ali *
Pr. DENDANE Tarek
Pr. DINI Nouzha *
Pr. ECH-CHERIF EL KETTANI Mohamed Ali
Pr. ECH-CHERIF EL KETTANI Najwa
Pr. ELFATEMI NIZARE

Chirurgie Cardio-vasculaire
Pédiatrie
Hématologie biologique
Chirurgie Générale
Radiologie
Cardiologie
Pneumo-Phtisiologie

Anesthésie réanimation
Médecine Interne [Directeur ERSSM](#)
Physiologie
Microbiologie
Médecine Aéronautique
Biochimie- Chimie
Radiologie
Chirurgie Pédiatrique
Pédiatrie
Radiologie
Chirurgie Plastique et Réparatrice
Urologie
Gastro-Entérologie
Anatomie Pathologique
Anesthésie Réanimation
Chirurgie Générale
Anatomie Pathologique

Anatomie Pathologique

Chirurgie pédiatrique
Anesthésie Réanimation
Traumatologie-orthopédie
Anesthésie Réanimation
Chirurgie Générale
Pneumophtisiologie
Chirurgie Pédiatrique
Anatomie Pathologique

Pharmacologie
Toxicologie
Gastro-Entérologie
Anesthésie-Réanimation
Anesthésie-Réanimation
Réanimation Médicale
Anesthésie-Réanimation
Biochimie-Chimie
Hématologie
Anesthésie Réanimation
Néphrologie
Chimie Analytique et Bromatologie
Traumatologie orthopédie
Anatomie
Cardiologie
Réanimation Médicale
Pédiatrie
Anesthésie Réanimation
Radiologie
Neuro-chirurgie

*Enseignant militaire

Pr.EL GUERROUJ Hasnae
 Pr.EL HARTI Jaouad
 Pr.EL JAOUADI Rachid *
 Pr.EL KABABRI Maria
 Pr.EL KHANNOUSSI Basma
 Pr.EL KHLOUFI Samir
 Pr.EL KORAICHI Alae
 Pr.EN-NOUALI Hassane *
 Pr.ERRGUIG Laila
 Pr.FIKRI Meryem
 Pr.GHFIR Imade
 Pr.IMANE Zineb
 Pr.IRAQI Hind
 Pr.KABBAJ Hakima
 Pr.KADIRI Mohamed *
 Pr.LATIB Rachida
 Pr.MAAMAR Mouna Fatima Zahra
 Pr.MEDDAH Bouchra
 Pr.MELHAOUI Adyl
 Pr.MRABTI Hind
 Pr.NEJJARI Rachid
 Pr.OUBEJJA Houda
 Pr.OUKABLI Mohamed *
 Pr.RAHALI Younes
 Pr.RATBI Ilham
 Pr.RAHMANI Mounia
 Pr.REDA Karim *
 Pr.REGRAGUI Wafa
 Pr.RKAIN Hanan
 Pr.ROSTOM Samira
 Pr.ROUAS Lamiaa
 Pr.ROUIBAA Fedoua *
 Pr.SALIHOUN Mouna
 Pr.SAYAH Rochde
 Pr.SEDDIK Hassan *
 Pr.ZERHOUNI Hicham
 Pr.ZINE Ali *

AVRIL 2013

Pr.EL KHATIB MOHAMED KARIM *

MAI 2013

Pr. BOUSLIMAN Yassir*

MARS 2014

Pr. ACHIR Abdellah
 Pr.BENCHAKROUN Mohammed *
 Pr.BOUCHIKH Mohammed
 Pr. EL KABBAJ Driss *
 Pr. EL MACHTANI IDRISSE Samira *
 Pr. HARDIZI Houyam
 Pr. HASSANI Amale *
 Pr. HERRAK Laila
 Pr. JEAIDI Anass *
 Pr. KOUACH Jaouad*
 Pr. MAKRAM Sanaa *
 Pr. RHISSASSI Mohamed Jaafar
 Pr. SEKKACH Youssef*
 Pr. TAZI MOUKHA Zakia

Médecine Nucléaire
 Chimie Thérapeutique
 Toxicologie
 Pédiatrie
 Anatomie Pathologique
 Anatomie
 Anesthésie Réanimation
 Radiologie
 Physiologie
 Radiologie
 Médecine Nucléaire
 Pédiatrie
 Endocrinologie et maladies métaboliques
 Microbiologie
 Psychiatrie
 Radiologie
 Médecine Interne
 Pharmacologie
 Neuro-chirurgie
 Oncologie Médicale
 Pharmacognosie
 Chirurgie Pédiatrique
 Anatomie Pathologique
 Pharmacie Galénique **Vice-Doyen à la Pharmacie**
 Génétique
 Neurologie
 Ophtalmologie
 Neurologie
 Physiologie
 Rhumatologie
 Anatomie Pathologique
 Gastro-Entérologie
 Gastro-Entérologie
 Chirurgie Cardio-Vasculaire
 Gastro-Entérologie
 Chirurgie Pédiatrique
 Traumatologie Orthopédie

 Stomatologie et Chirurgie Maxillo-faciale

 Toxicologie
 Chirurgie Thoracique
 Traumatologie- Orthopédie
 Chirurgie Thoracique
 Néphrologie
 Biochimie-Chimie
 Histologie- Embryologie-Cytogénétique
 Pédiatrie
 Pneumologie
 Hématologie Biologique
 Gynécologie-Obstétrique
 Pharmacologie
 CCV
 Médecine Interne
 Gynécologie-Obstétrique

*Enseignant militaire

DECEMBRE 2014

Pr. ABILKACEM Rachid*
Pr. AIT BOUGHIMA Fadila
Pr. BEKKALI Hicham *
Pr. BENAZZOU Salma
Pr. BOUABDELLAH Mounya
Pr. BOUCHRIK Mourad*
Pr. DERRAJI Soufiane*
Pr. EL AYOUBI EL IDRISSE Ali
Pr. EL GHADBANE Abdedaim Hatim*
Pr. EL MARJANY Mohammed*
Pr. FEJJAL Nawfal
Pr. JAHIDI Mohamed*
Pr. LAKHAL Zouhair*
Pr. OUDGHIRI NEZHA
Pr. RAMI Mohamed
Pr. SABIR Maria
Pr. SBAI IDRISSE Karim*

AOUT 2015

Pr. MEZIANE Meryem
Pr. TAHIRI Latifa

PROFESSEURS AGREGES :**JANVIER 2016**

Pr. BENKABBOU Amine
Pr. EL ASRI Fouad*
Pr. ERRAMI Nouredine*
Pr. NITASSI Sophia

JUIN 2017

Pr. ABI Rachid*
Pr. ASFALOU Ilyasse*
Pr. BOUAITI El Arbi*
Pr. BOUTAYEB Saber
Pr. EL GHISSASSI Ibrahim
Pr. HAFIDI Jawad
Pr. MAJBAR Mohammed Anas
Pr. OURAINI Saloua*
Pr. RAZINE Rachid
Pr. SOUADKA Amine
Pr. ZRARA Abdelhamid*

MAI 2018

Pr. AMMOURI Wafa
Pr. BENTALHA Aziza
Pr. EL AHMADI Brahim
Pr. EL HARRECH Youness*
Pr. EL KACEMI Hanan
Pr. EL MAJJAOUI Sanaa
Pr. FATIHI Jamal*
Pr. GHANNAM Abdel-Ilah
Pr. JROUNDI Imane
Pr. MOATASSIM BILLAH Nabil
Pr. TADILI Sidi Jawad
Pr. TANZ Rachid*

NOVEMBRE 2018

Pr. AMELLAL Mina
Pr. SOULY Karim
Pr. TAHRI Rajae

Pédiatrie
Médecine Légale
Anesthésie-Réanimation
Chirurgie Maxillo-Faciale
Biochimie-Chimie
Parasitologie
Pharmacie Clinique
Anatomie
Anesthésie-Réanimation
Radiothérapie
Chirurgie Réparatrice et Plastique
O.R.L
Cardiologie
Anesthésie-Réanimation
Chirurgie Pédiatrique
Psychiatrie
Médecine préventive, santé publique et Hyg.

Dermatologie
Rhumatologie

Chirurgie Générale
Ophtalmologie
O.R.L
O.R.L

Microbiologie
Cardiologie
Médecine préventive, santé publique et Hyg.
Oncologie Médicale
Oncologie Médicale
Anatomie
Chirurgie Générale
O.R.L
Médecine préventive, santé publique et Hyg.
Chirurgie Générale
Immunologie

Médecine interne
Anesthésie-Réanimation
Anesthésie-Réanimation
Urologie
Radiothérapie
Radiothérapie
Médecine Interne
Anesthésie-Réanimation
Médecine préventive, santé publique et Hyg.
Radiologie
Anesthésie-Réanimation
Oncologie Médicale

Anatomie
Microbiologie
Histologie-Embryologie-Cytogénétique

*Enseignant militaire

NOVEMBRE 2019

Pr. AATIF Taoufiq*	Néphrologie
Pr. ACHBOUK Abdelhafid *	Chirurgie réparatrice et plastique
Pr. ANDALOUSSI SAGHIR Khalid	Radiothérapie
Pr. BABA HABIB Moulay Abdellah*	Gynécologie-Obstétrique
Pr. BASSIR RIDA ALLAH	Anatomie
Pr. BOUATTAR TARIK	Néphrologie
Pr. BOUFETTAL MONSEF	Anatomie
Pr. BOUCHENTOUF Sidi Mohammed *	Chirurgie-Générale
Pr. BOUZELMAT HICHAM *	Cardiologie
Pr. BOUKHRIS JALAL *	Traumatologie-Orthopédie
Pr. CHAFRY BOUCHAIB *	Traumatologie-Orthopédie
Pr. CHAHDI HAFSA*	Anatomie pathologique
Pr. CHERIF EL ASRI ABAD *	Neuro-chirurgie
Pr. DAMIRI AMAL *	Anatomie Pathologique
Pr. DOGHMI NAWFAL*	Anesthésie-Réanimation
Pr. ELALAOUI SIDI-YASSIR	Pharmacie-Galénique
Pr. EL ANNAZ HICHAM*	Virologie
Pr. EL HASSANI MOULAY EL MEHDI*	Gynécologie-Obstétrique
Pr. EL HJOUJI ABDERRAHMAN *	Chirurgie Générale
Pr. EL KAOUI HAKIM *	Chirurgie Générale
Pr. EL WALI ABDERRAHMAN*	Anesthésie-Réanimation
Pr. EN-NAFAA ISSAM *	Radiologie
Pr. HAMAMA JALAL *	Stomatologie et Chirurgie Maxillo-faciale
Pr. HEMMAOUI BOUCHAIB*	O.R.L
Pr. HJIRA NAOUFAL *	Dermatologie
Pr. JIRA MOHAMED *	Médecine interne
Pr. JNIENE ASMAA	Physiologie
Pr. LARAQUI HICHAM *	Chirurgie-Générale
Pr. MAHFOUD TARIK *	Oncologie Médicale
Pr. MEZIANE MOHAMMED *	Anesthésie-Réanimation
Pr. MOUTAKI ALLAH YOUNES *	Chirurgie Cardio-Vasculaire
Pr. MOUZARI YASSINE *	Ophtalmologie
Pr. NAOUI HAFIDA *	Parasitologie-Mycologie
Pr. OBTEL MAJDOULINE	Médecine préventive, santé publique et Hyg.
Pr. OURRAI ABDELHAKIM *	Pédiatrie
Pr. SAOUAB RACHIDA *	Radiologie
Pr. SBITTI YASSIR *	Oncologie Médicale
Pr. ZADDOUG OMAR*	Traumatologie-Orthopédie
Pr. ZIDOUH SAAD *	Anesthésie-Réanimation

*Enseignant militaire

2 - ENSEIGNANTS-CHERCHEURS SCIENTIFIQUE

PROFESSEURS DE L'ENSEIGNEMENT SUPERIEUR :

Pr. ABOUDRAR Saadia	Physiologie
Pr. ALAMI OUHABI Naima	Biochimie-chimie
Pr. ALAOUI KATIM	Pharmacologie
Pr. ALAOUI SLIMANI Lalla Naïma	Histologie-Embryologie
Pr. ANSAR M'hammed	Chimie Organique et Pharmacie Chimique
Pr .BARKIYOU Malika	Histologie-Embryologie
Pr. BOUHOUCHE Ahmed	Génétique Humaine
Pr. BOUKLOUZE Abdelaziz	Applications Pharmaceutiques
Pr. DAKKA Taoufiq	Physiologie <u>Vice-Doyen chargé de la Rech. et de la Coop.</u>
Pr. FAOUZI Moulay El Abbes	Pharmacologie
Pr. IBRAHIMI Azeddine	Biologie moléculaire/Biotechnologie
Pr. OULAD BOUYAHYA IDRISSE Med	Chimie Organique
Pr. RIDHA Ahlam	Chimie
Pr. TOUATI Driss	Pharmacognosie
Pr. ZAHIDI Ahmed	Pharmacologie

PROFESSEURS HABILITES :

Pr .BENZEID Hanane	Chimie
Pr. CHAHED OUZZANI Lalla Chadia	Biochimie-chimie
Pr .DOUKKALI Anass	Chimie Analytique
Pr .EL JASTIMI Jamila	Chimie
Pr. KHANFRI Jamal Eddine	Histologie-Embryologie
Pr.LYAHYAI Jaber	Génétique
Pr. OUADGHIRI Mouna	Microbiologie et Biologie
Pr. RAMLI Youssef	Chimie
Pr. SERRAGUI Samira	Pharmacologie
Pr. TAZI Ahnini	Génétique
Pr. YAGOUBI Maamar	Eau, Environnement

Mise à jour le 09/04/2021

KHALED Abdellah

Chef du Service des Ressources Humaines

FMPR

*Enseignant militaire



Dedications

To my cherished mother

To the woman who brought me into the world

The one who loved me at first sight

Words could never be enough to properly thank you or to express my deep affection and gratitude.

You are in my eyes an example of goodness, patience self-sacrifice and humility. Your patience, encouragement, support, and unwavering sacrifice gave me the strength to study and the courage to achieve my goals. You are my sunshine, my most precious treasure.

You taught me that science without ethics, humanity and principles is worthless. You instilled in me the human values, and you showed me how they will make of me a good doctor.

I am grateful for your unconditional support, your tolerance and your guidance during my difficult times. Thank you for being my backbone.

On this most memorable day, I hope I have lived up to your aspirations.

May God, the Almighty, bless you with health, happiness and long life.

I dedicate to you this work that couldn't have been done without your support.

To my dear father

I dedicate this work to the person who accompanied me on my first day in college to encourage me to pass my entrance exam.

Through the years, you have made a lot of physical and moral sacrifices for us.

It was thanks to your concepts that we had learned to rely on ourselves.

You taught us how to be patient, and to never give up.

I hope, through this work, to have made you proud.

I dedicate this work to you as a symbol of my appreciation and gratitude. It is the fruit of all the sacrifices you have made for my education and learning.

To my dear brother Mohammed Amine

You have always supported me in your unique way.

I dedicate this work to you in memory of our complicity and in recognition of your support, your affection and your generosity.

May God preserve our love and our union.

I love you and I am proud of you.

To my lovely brother Yassine

Endless source of positivity and joy, I could never imagine life without you.

You were always there for me, you witnessed my anxieties, and you always reassured me when my exam stress got the better of me. You helped me overcome these feelings with your humor and your warmth.

I love you so much little brother.

To my beloved Mima

*Your presence in my life during these years has been a real blessing.
I am so grateful for all the love and caring that you never ceased to give
me over the years. No words can express the depth of my feelings and
the high regard, respect and great affection I have for you.
May God protect you, and may you remain a guiding light in our lives.*

In memory of my grandfathers, and my paternal grandmother

*Fate prevented me from enjoying this happiness with you, I would have
liked you to be with us on this day.
I dedicate my success to you today.
May Allah the merciful, welcome you in his eternal paradise.*

To my dearest aunts Lamiaa, Asmaa and Walaa

And my aunt Fatima, uncle Taib and Ibrahim

*I am very appreciative for all you have done for me: advice, affection,
support, comfort, gifts and encouragement.*

Thank you for always being there for me.

You are the best. God bless you and protect you.

***To my paternal aunts Khadija, Saadia, Aziza,
and uncles Mohammed, Khalid, Houssine, Ahmed,
Hassane, Abdeltif,***

*Thank you for all the support, love, companionship since my childhood
and the good times we shared.*

I dedicate this thesis to you as a way of thanks and appreciation.

To my second family, Kaoutar and Saad

It is such a blessing to be your friend for more than a decade now. The friendship, the fidelity, the love that we have for each other, even our differences make our friendship the strongest.

You have one of the biggest and purest hearts in the world.

Thank you for being present for me and taking care of me when I need it the most, for comforting and standing by me when I'm falling apart, for tolerating me when I'm at my lowest, and for simply being a part of my life. I wouldn't have made it through my hardest days without your support and love.

May our friendship be eternal.

To my dear Siham

For all the years together, you have been the best roommate one could wish for. The most difficult moments in the life of each one, turned out to be beautiful memories now, thanks to our presence for each other.

May you have a happy and prosperous life.

To my dear cousins, and large family

I thank you for all the moments of joy and celebration that we have shared.

May this work be a reflection of my deep affection and of my sincere appreciation.

*To all my friends, and colleagues: Sylène, Bouchra,
Chaimae, Akram, Mourad, Hibat Allah, Sarah, Fadwa,
Othmane, Ahmed, Najat,*

*To my colleagues with whom I shared wonderful
moments during these years: Mounia, Youness, Loubna,
Chadia, Wafae, Oussama, Ataa Allah*

*To my dear professors who have become my friends,
To all the people who have marked my life, and that I
have failed to mention*

*In recognition of the friendship that unites us, and the memories of all
the moments we spent together.*

Thank you for embellishing my life with your presence.

May God bless and preserve our friendship.

Last but not least, to myself,

*To the girl in me that has gone through a lot, and still fighting.
I want to thank myself for believing in me, for working hard, for never
quitting. Even though I did it with family's and friends' help,
sometimes it was just too hard to keep going. This work is especially
destined to the little girl that I was, who always dreamt of becoming a
Medical Doctor and finally made it.*



Acknowledgements

To the president of this thesis

Pr Mohammed Anouar Dendane

Professor of pediatric surgery and traumatology

You have honored me by accepting to chair the Jury of this thesis.

*This gesture shows not only your kindness but above all your concern
for your students.*

To the supervisor of the present thesis

Pr Abdelouahed Amrani

*Professor of pediatric traumatology and reconstructive
surgery*

*This is an opportunity to express my deep appreciation for your high
human qualities.*

*More than a thesis supervisor, you have been a guide in daily and
professional life.*

*Your tireless encouragement, your affability, your kindness deserve all
admiration.*

*I would like to be worthy of the trust you have placed in me and I
request of you, dear master, to find here the expression of my sincere
recognition and deep gratitude.*

To our master and thesis judge

Pr Naima Hafidi

Professor of pediatrics

I am deeply moved by your modesty, kindness and the spontaneity of your welcome. You have honored me by being part of our jury.

Please accept, Professor, my deep respect and my sincere gratitude.

To our master and thesis judge

Pr Abilkassem Rachid

Professor of pediatrics

I would like to thank you for the interest you have shown in this work, and for the great honor you have given me by agreeing to be a member of the jury for this thesis.



List of abbreviations

AVN	: Avascular necrosis
CHU	: University hospital center
CT	: Computed tomography
FAI	: Femoro-acetabular impingement
HHS	: Harris Hip Score
ICP	: Intracranial pressure
IR	: Internal rotation
K-wire	: Kirschner wire
LDF	: Laser doppler flowmetry
LLL	: Left leg length
MRI	: Magnetic resonance imaging
OA	: Osteoarthritis
ON	: Osteonecrosis
RLL	: Right leg length
ROM	: Range of motion
SCFE	: Slipped capital femoral epiphysis
SSA	: Southwick slip angle
SUFE	: Slipped upper femoral epiphysis
THA	: Total hip arthroplasty



List of illustrations

List of figures:

Figure 1 : A and B: X-ray and CT-scan showing the SCFE of the left hip.	7
Figure 2 : Immediate postoperative radiological control.....	8
Figure 3 : X-ray and CT-scan of the pelvis objectifying a severe SCFE of the left hip.....	9
Figure 4 : Intra operative image showing the femoral head before reduction.	10
Figure 5 : Radiological control 6 months after the surgery, objectifying a good evolution and absence of complications.	11
Figure 6 : Clinical evolution of the patient with improvement of motion and disappearance of pain.	11
Figure 7 : Radiological images showing the severe SCFE and the measurement of the Southwick angle of the left hip.	12
Figure 8 : Immediate post-operative control X-ray.....	13
Figure 9 : post-operative images showing a normal ROM and the disappearance of Drehmann sign	14
Figure 10 : X-ray and CT-scan showing the severe SCFE in the left hip.	15
Figure 11 : Cross-section showing the angle of the slippage and the posterior tilt.	16
Figure 12 : Cross section, indicating the site of the femoral osteotomy.	17
Figure 13 : Intra-operative images of the femoral head before and after capsulotomy.	17
Figure 14 : front and profile X-rays showing a SCFE of the right hip.....	18
Figure 15 : Radiological control on 9 months follow-up	19
Figure 16 : Radiography showing collapse of the femoral head due to AVN.....	19
Figure 17 : The arrow indicates a positive bleeding sign during the operation of modified Dunn procedure using K-wire drilling of the femoral head.....	20
Figure 18 : Graph showing the distribution of patients by age.....	23
Figure 19 : Graph showing the distribution of patients by gender.....	23
Figure 20 : Graph showing the distribution of patients based on the affected side	24
Figure 21 : Preoperative photo of a patient positioned for a left hip arthroscopy showing the portal placement [40].....	34
Figure 22 : X-ray image of AVN.	40
Figure 23 : Radiological image 12 months after surgery of case 5 in our study that developed AVN.....	43
Figure 24 : Radiological images of chondrolysis.....	45
Figure 25 : Radiological image of leg length discrepancy in a case from our series, one year after surgery.	47

List of tables

Table 1 : Overview table of clinical symptoms of the patients included in the study.....	21
Table 2 : table gathering clinical and radiological results, as well as complications	26
Table 3 : Table: Comparison of patient criteria in different studies.....	32
Table 4 : Table: comparison of results in studies of different surgical methods	37
Table 5 : Table: comparison of post-operative AVN with the literature series.	42



Summary

Introduction	1
Materials	5
and methods	5
1. Type of study :	6
2. Population :	6
3. Medical observations :	6
4. Summary chart :	21
Results	22
1. Demographic data	23
1.1. Distribution according to age	23
1.2. Distribution by gender	23
1.3. Distribution depending on the affected side	24
2. Clinical data.....	24
2.1. Reason for consultation	24
2.2. Physical examination	24
3. Radiological data	25
4. Conduct of the operation.....	25
5. Post-operative results	25
5.1. Assessment criteria	25
5.2. Global results	26
6. Summay of results:	26
Discussion	27
1. Introdution:	28
2. Indications of Dunn’s subcapital osteotomy:.....	29
3. Surgical technique:.....	33
3.1. Open vs arthroscopic surgery:	33
3.2. Classical vs modified Dunn procedure:.....	35
3.3. Monitoring of the femoral head perfusion:.....	38
4. Post-operative complications:	39
4.1. Avascular necrosis:	39

4.2. Chondrolysis:	44
4.3. Leg length discrepancy:	46
4.4. Other complications related to surgical treatment of SCFE:	48
<i>Conclusion</i>	50
<i>Abstract</i>	52
<i>Appendices</i>	56
<i>Bibliography</i>	60

Introduction

Slipped capital femoral epiphysis (SCFE) is defined by a sliding of the upper femoral epiphysis on the metaphysis. It is typically a posterior and inferior displacement of the epiphysial nucleus through the growth plate. This condition occurs during the rapid growth phase of puberty and affects older children and adolescents. The slippage of the epiphysis can occur in an acute mode, chronic, or acute on a chronic form[1, 2].

Among all hip disorders in adolescents, SCFE is the foremost common one, which occurs in 10.8 per 100,000 children, and is one of the most frequently missed diagnoses in children of 8 to 15 years of age. Patients with SCFE typically present with limping and pain poorly located in the hip, groin, knee, or thigh. On physical examination, the patient may have an antalgic attitude or be unable to bear his or her own weight with a severe slip. The limitation of the internal rotation of the hip is the most revealing sign. A mandatory external rotation is observed in the involved hip of patients with SCFE when the hip is flexed to 90 degrees (Drehmann's sign) [3].

Different classification systems describe the severity of SCFE and the risk for AVN. Three classification systems are widely accepted, based on the stability of the slip, the duration of symptoms, and the extension of the slip [4].

SCFE is classified according to the severity of slippage using the Southwick angle, defining 3 stages: stage 1 if the angle is under 30°, stage 2 if it is between 30° and 60°, stage 3 if it is over 60°. The less the displacement, the better the prognosis: grade 1 and 2 SCFEs have an excellent long-term prognosis when treated with in-place fixation, whereas grade 3 are associated with early functional deterioration[1, 5, 6].

The spontaneous evolution is dominated by the increase of the displacement, the occurrence of an "acute" slippage which is associated with early complications, in addition to the long term complications [1]. Severe SCFE inevitably results into femoroacetabular impingement, damage to the acetabular cartilage and the early onset of osteoarthritis, hence the need for a realignment treatment.

The treatment aims to stop the progression of the slippage and avoid complications, whose frequency increases with the extent of the displacement. Different surgical procedures have been reported including closed reduction with in situ fixation, arthroscopic offset correction, and open osteotomies with correction of the deformity of the physeal junction[7].

Some specialists recommend treatment with the more conventional procedure of in situ pinning and fixation, whereas others suggest, for high-grade SCFE, that more aggressive surgery is required to properly reduce the epiphysis and restrain the incidence of upcoming complications , femoroacetabular impingement (FAI) and osteoarthritis.

Current progress in the surgical treatment of severe SCFE aims to protect epiphyseal blood supply while correcting the proximal femoral deformity. The modified Dunn procedure was described to reach both of these goals while being a secure and effective process to treat acute and chronic severe SCFE [8].

Dunn's original technique for open reduction of the femoral head consists of a lateral approach to the hip, with careful elevation of the vessels in the periosteal fold. A trapezoid osteotomy is then performed at the proximal portion of the femoral neck to prevent the retinacular vessels from being stretched.


Later, an attempt has been made to improve the safety of Dunn's subcapital realignment by associating it with the surgical hip dislocation procedure [9]. The technique involves a surgical dislocation of the hip through trochanteric osteotomy, with creation of an extended retinacular flap. With careful handling of the vessels and the epiphysis, the posterior and medial callus is excised, and a very minimal shortening of the femoral neck is performed to avoid stretching on the vessels once the epiphysis is reduced. The physis is excised to promote a faster bony union, and the epiphysis is reduced on the metaphysis, correcting the slippage at the site of the deformity. With this approach, perfusion of the femoral head can be monitored intraoperatively by laser Doppler flowmetry or using a sterile arterial blood flow catheter [10].

This study aims to report on the experience of the pediatric trauma and orthopedics department at the pediatric hospital, CHU Ibn Sina of Rabat, in the treatment of severe slipped capital femoral epiphysis using the DUNN technique; about 05 cases.

There is conflicting evidence in the literature regarding the management of unstable SCFE. Several questions arise:

- What are the indications for Dunn's technique according to the Southwick classification?
- As the field of hip preservation surgery develops, what are the roles of arthroscopy and surgical dislocation?
- Given that the correction is to be made where the deformity is –at the growth plate– how could vascular risk be limited?

Through this thesis, we will try to answer these questions by taking into account recent works in the literature.



***Materials
and
methods***

1. Type of study :

This is a retrospective, qualitative and descriptive study that has been conducted in the paediatric orthopaedics and trauma department of the paediatric hospital, CHU Ibn Sina of Rabat; over a period of 4 years (october 2017 to october 2021).

2. Population :

Our study is based on the analysis of the records of 05 patients followed up for severe slipped capital femoral epiphysis and treated by the Dunn technique.

The objective of this work is to describe the principles of this surgical technique and to compare the results obtained in our series with those of the literature.

2.1. Inclusion criteria:

All children followed for severe SCFE and operated by the DUNN technique between October 2017 and October 2021.

2.2. Exclusion criteria:

All children followed for SCFE during this period and treated by any other technique.

3. Medical observations :

➤ Observation N° 1:

Mr Aymane is a 14 year old boy living in Temara, who was admitted to the hospital with a chief concern of limping and localized pain in the hip area of 1 month duration.

The clinical examination on admission revealed that the child was in good general condition, with limited abduction and internal rotation (IR) of the left hip, and a positive Drehmann sign.

An X-ray of the pelvis and a CT scan completed the examination, objectifying a SCFE of the left hip (Fig 11).

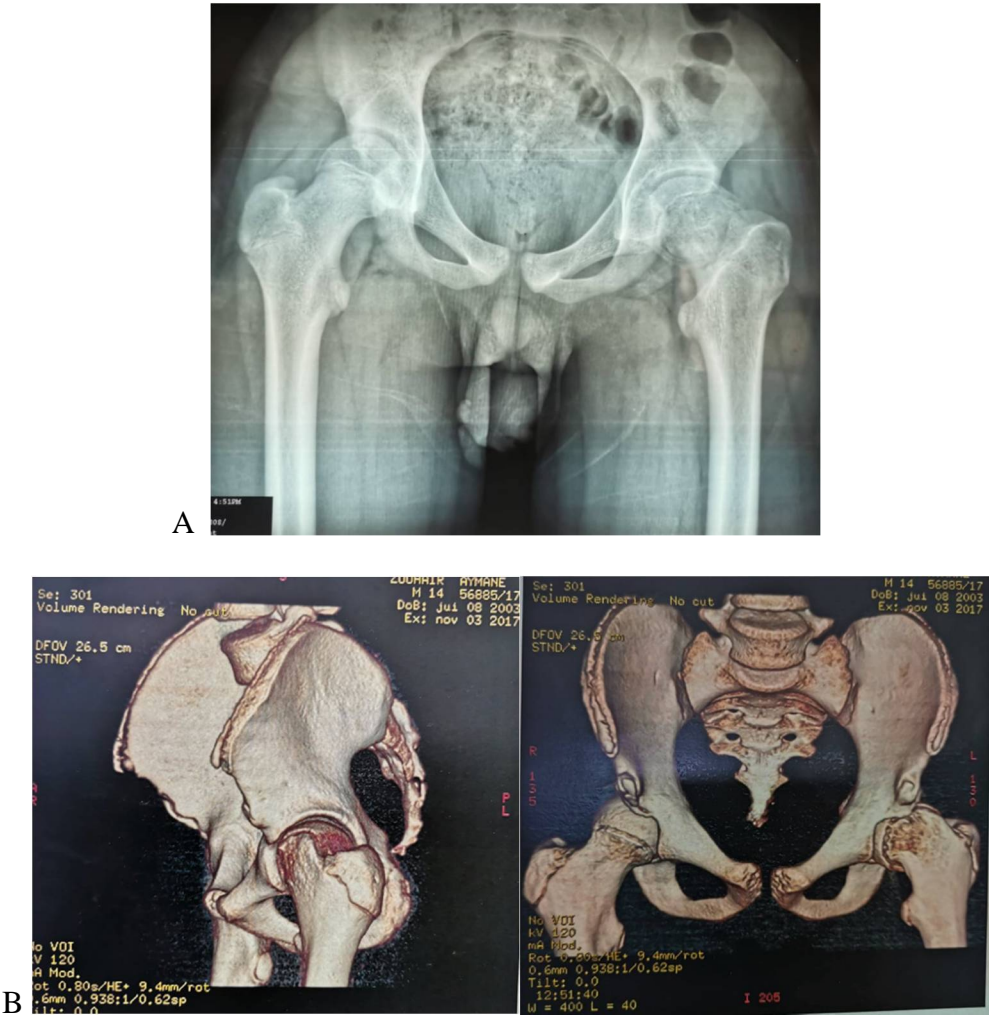


Figure 1 : A and B: X-ray and CT-scan showing the SCFE of the left hip.

The child has undergone surgery using the Dunn technique on 11/21/2017, under general anesthesia. After a Hueter incision, he underwent an opening of the joint capsule, an incision of the periosteum along the femoral neck; then an ablation of the callus formed between the epiphysis and the metaphysis using a surgical rongeur, without reaching the posterior face, creating a triangle with an anterior base. The epiphysis was then reduced on the metaphysis and a percutaneous trans cervical fixation was performed.

The immediate postoperative radiological control was satisfactory. The patient was put under antibiotic prophylaxis and anti-inflammatory treatment before his discharge.

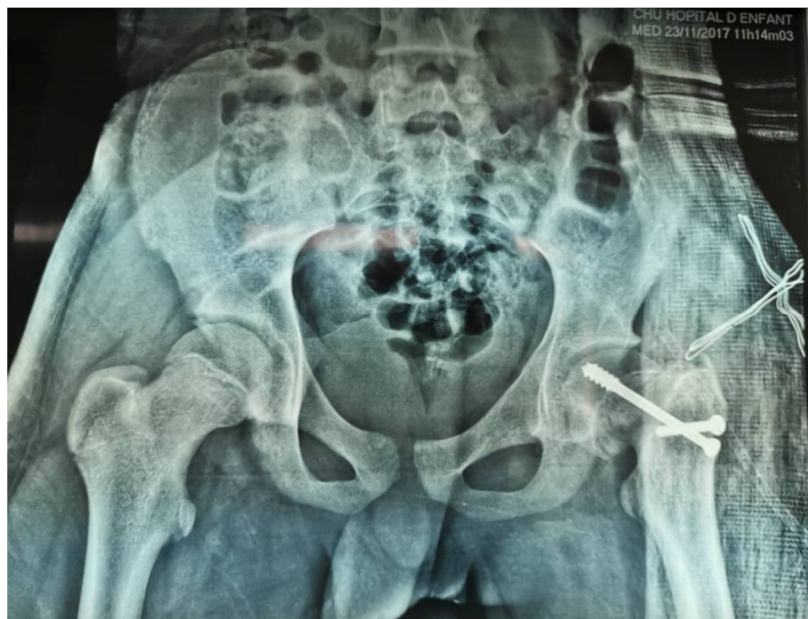

Figure 2 : Immediate postoperative radiological control.

➤ **Observation N° 2**

Mr Amine, 14 year old boy living in Kenitra with no medical history. He was referred from Kenitra's hospital for a chronic and neglected SCFE of the left hip, with postero inferior tilt of the femoral head in the x-ray performed.

Physical examination showed a limited range of motion and painful active and passive movement of the left lower limb.

The radiological examinations showed a severe SCFE of the left hip, with a Southwick angle measuring 73° , as well as a femoroacetabular impingement (FAI) (Fig 13).

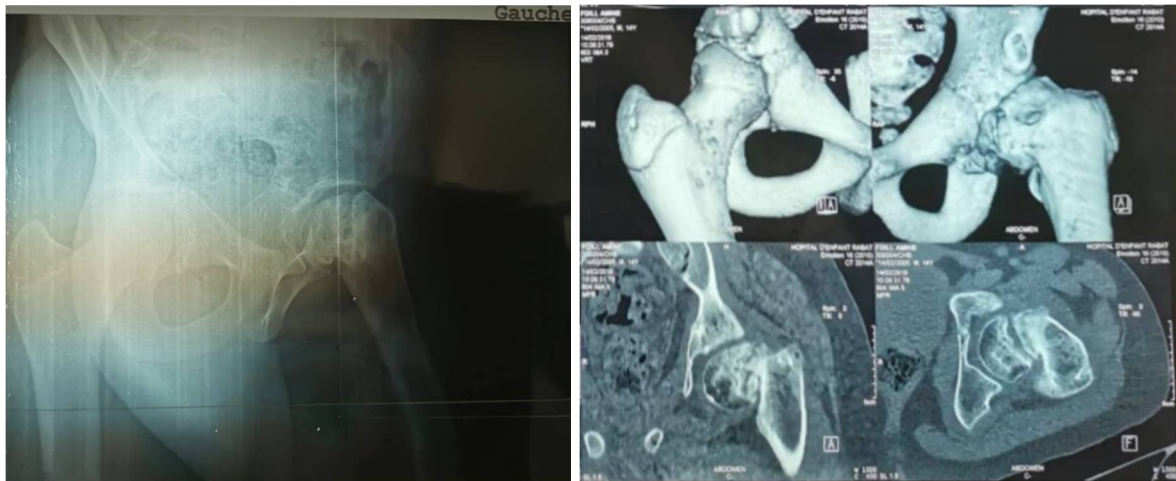

Figure 3 : X-ray and CT-scan of the pelvis objectifying a severe SCFE of the left hip.

The patient was operated on according to the Dunn procedure on 03/05/2019. He was put under antibiotic prophylaxis and anti-inflammatory treatment.

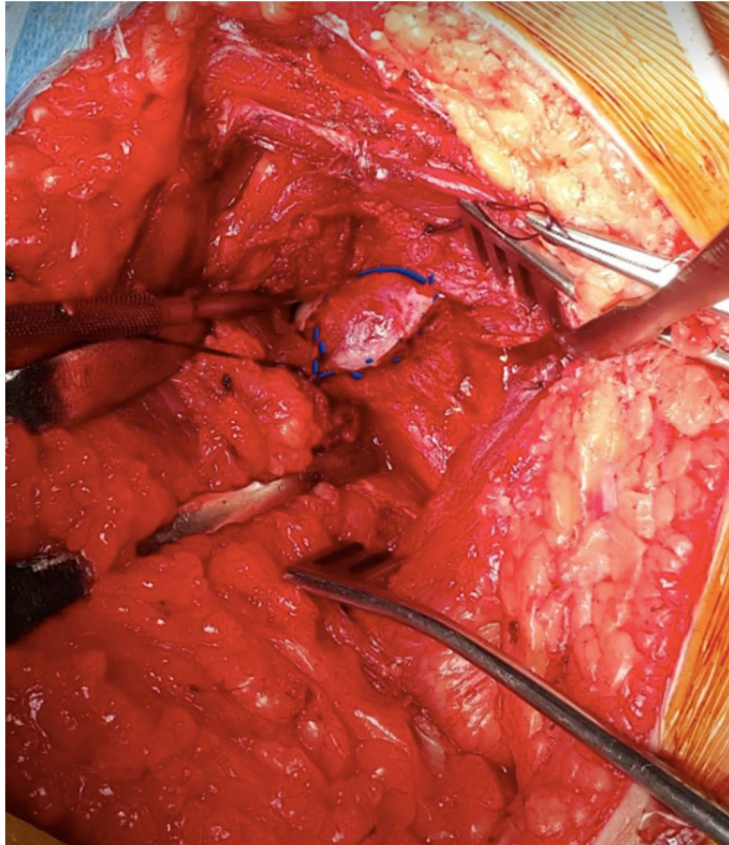


Figure 4 : Intra operative image showing the femoral head before reduction.

The clinical evolution in post-operative was very good, with gain of near to normal ROM and absence of major complications.

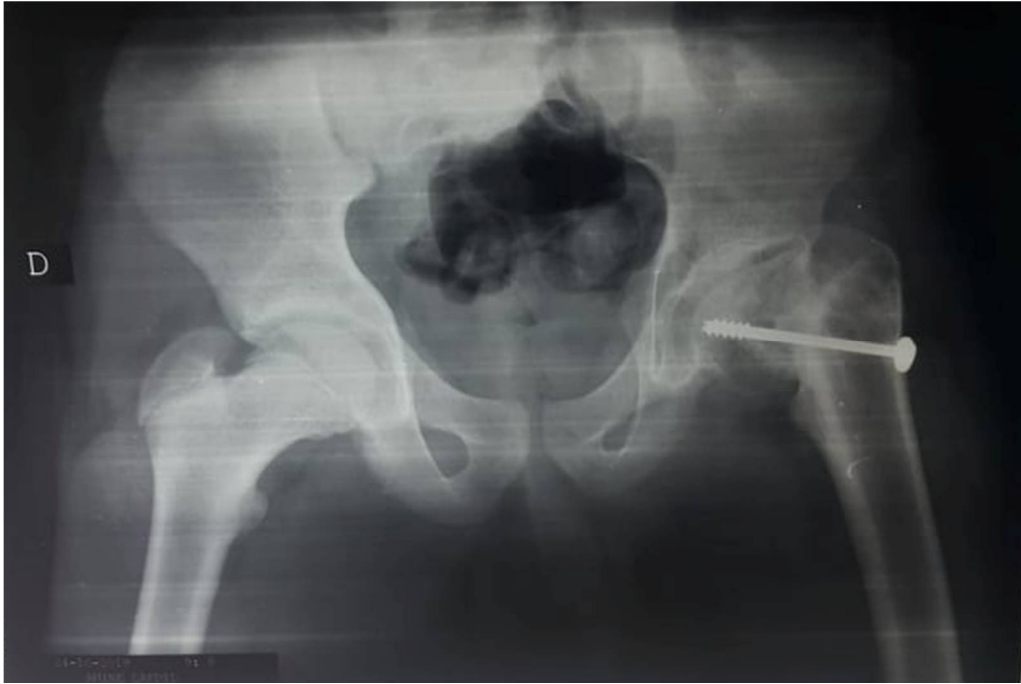

Figure 5 : Radiological control 6 months after the surgery, objectifying a good evolution and absence of complications.



Figure 6 : Clinical evolution of the patient with improvement of motion and disappearance of pain.

➤ **Observation N° 3:**

Ms Keltoum is a 10 year old girl living in Rabat who has no past medical history.

She presented with a chronic limp evolving for several months, as well as a left hip pain; the clinical exam noted a positive Drehmann sign.

The examination was completed by an X-ray and a CT scan which showed a left SCFE with a slip of more than 1/3 of the metaphysis and a Southwick angle of 62°, classifying it as a severe SCFE .

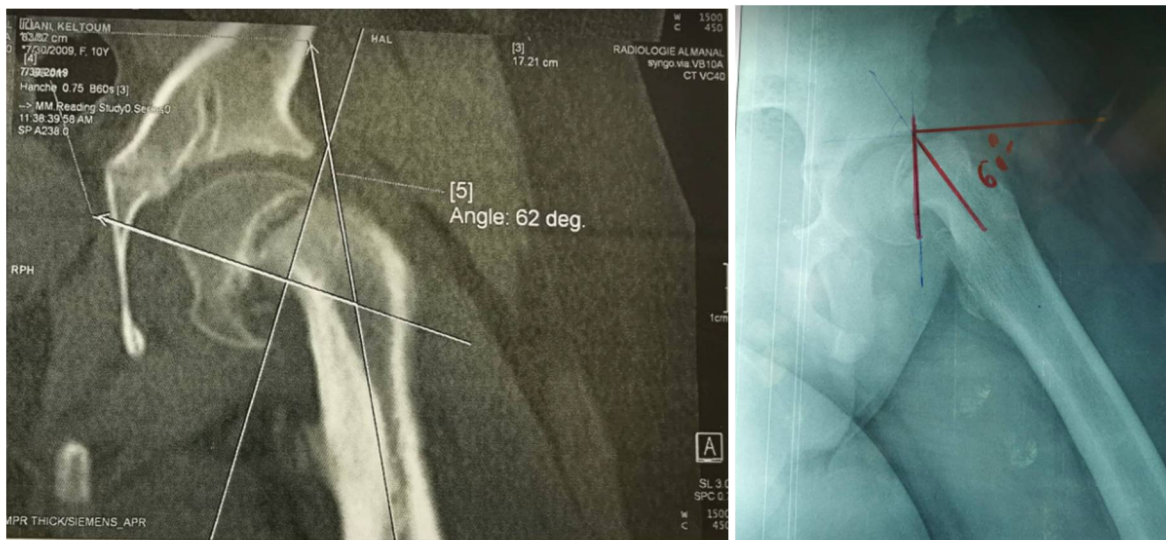


Figure 7 : Radiological images showing the severe SCFE and the measurement of the Southwick angle of the left hip.

This patient underwent a surgery using the classical Dunn technique on the 08/08/2019, and was given antibioprophyllactic and antalgic treatment.

The immediate postoperative radiological control was satisfactory.

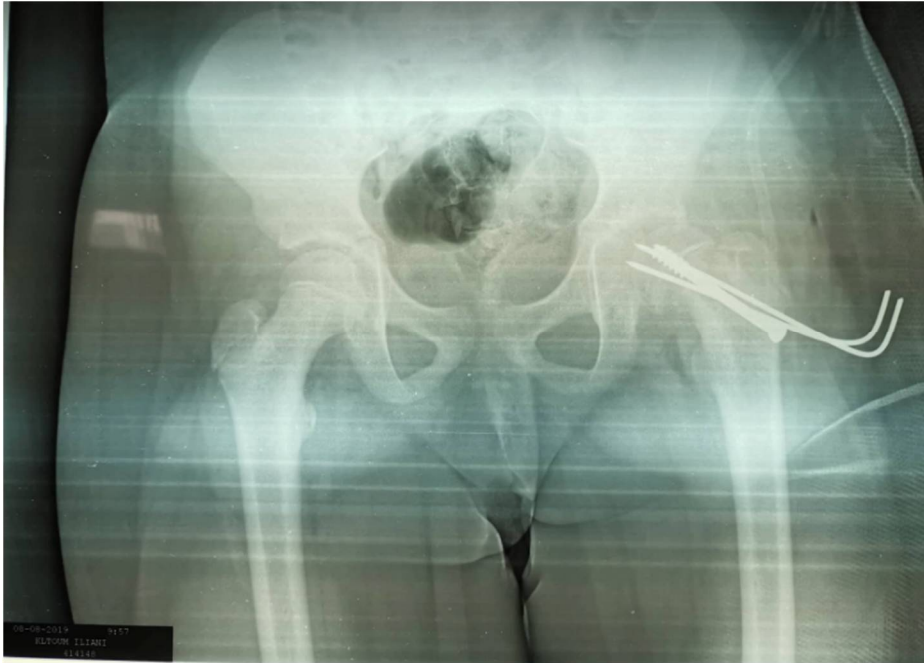

Figure 8 : Immediate post-operative control X-ray.

Image showing anatomical reduction, and pins and screws in place.

The evolution was satisfactory with the gain of normal ROM a few months after the surgery.

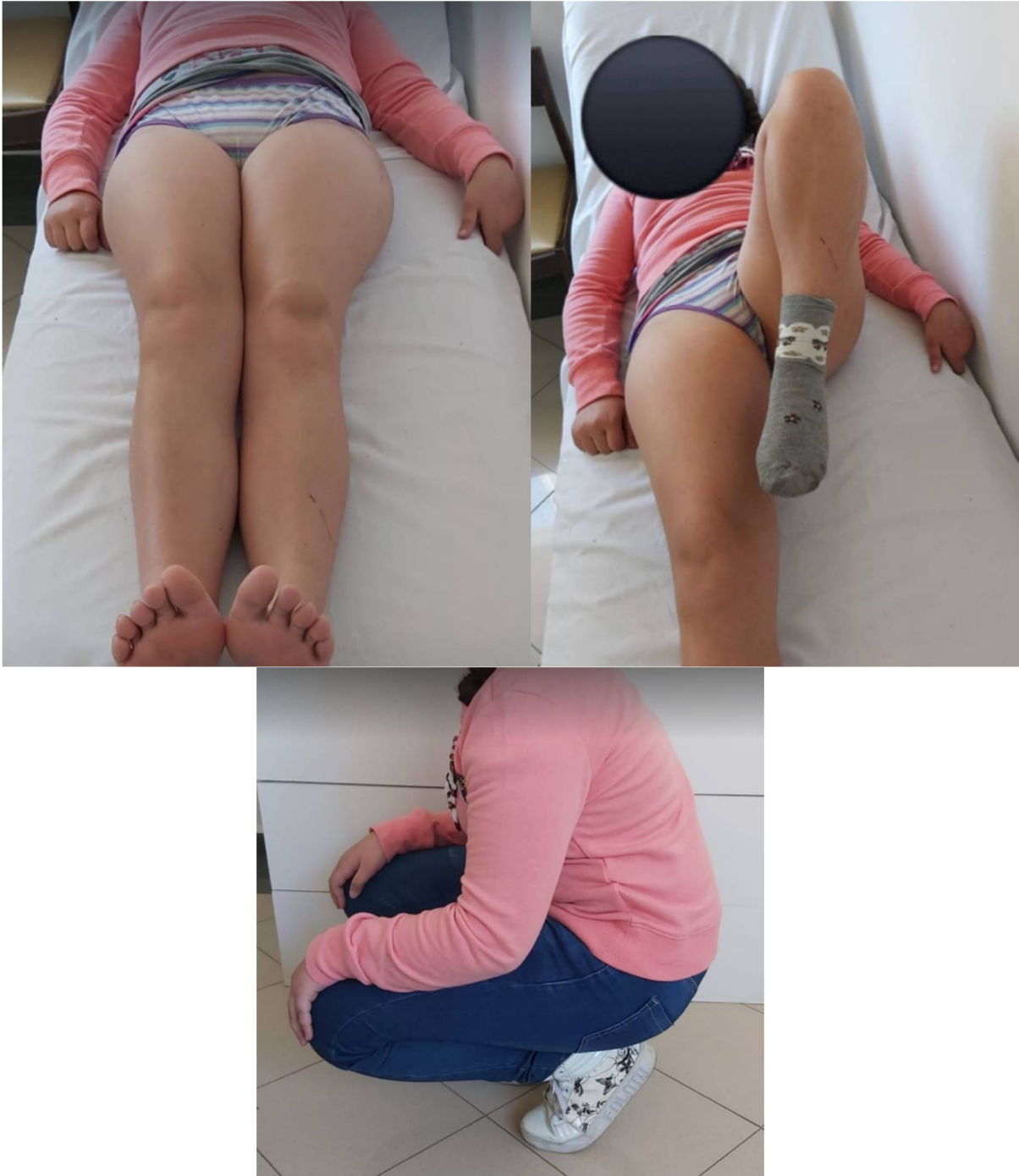

Figure 9 : post-operative images showing a normal ROM and the disappearance of Drehmann sign

➤ **Observation N° 4:**

Youssef is an 11 year-old boy living in Moulay Bouselham, who was admitted in the hospital with a chief complaint of left hip limping, that has been increasing for last 10 days, without any notion of trauma.

The clinical examination revealed that the child was in good general condition, suffering from a limp of the left shoulder. His left lower limb (LLL) was shortened, in a position of adduction and external rotation.

The frontal radiography showed the slippage of more than ½ of the femoral head through the neck, and the presence of a bony bridge (fig 16).

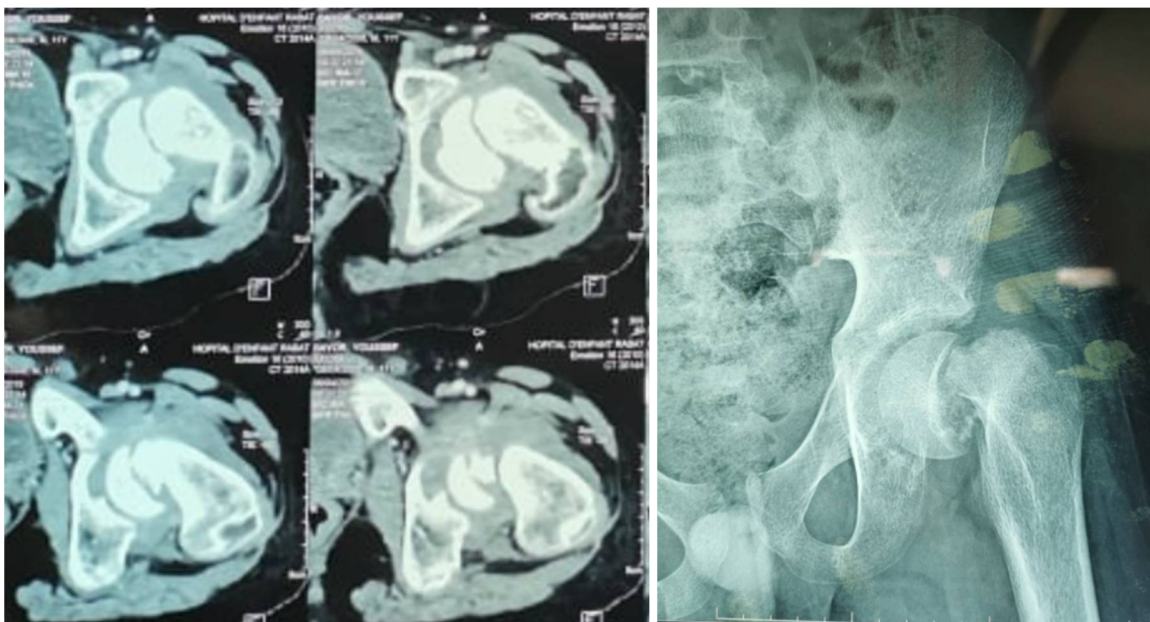


Figure 10 : X-ray and CT-scan showing the severe SCFE in the left hip.

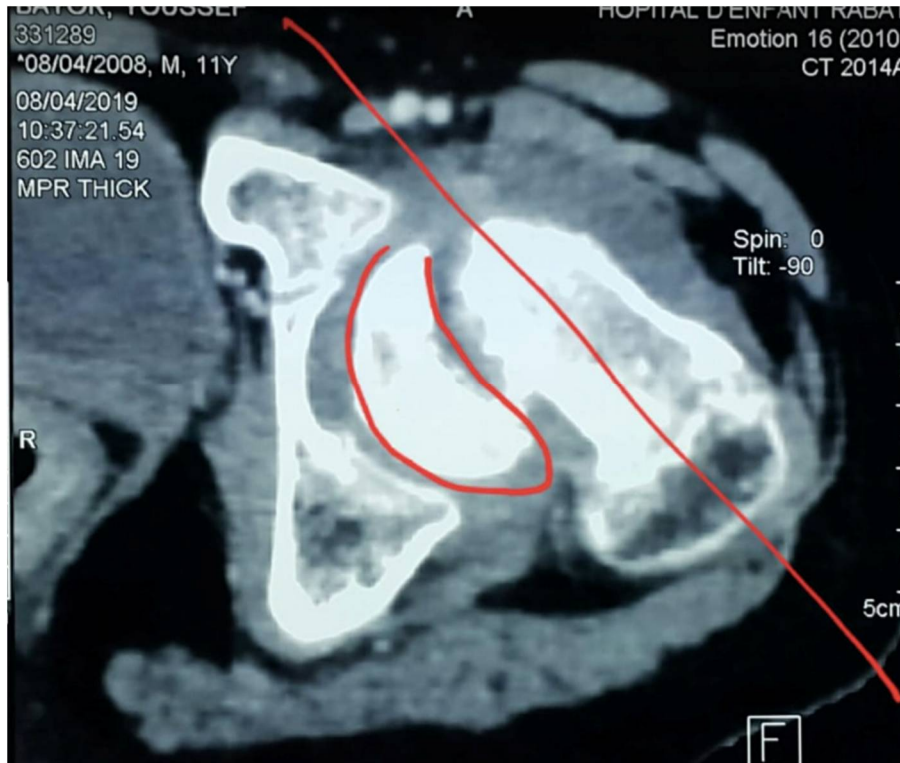

Figure 11 : Cross-section showing the angle of the slippage and the posterior tilt.

The ultrasound performed showed the absence of joint effusion and no soft tissue collection.

The patient was operated on using the classical Dunn approach on the 09/04/2019.

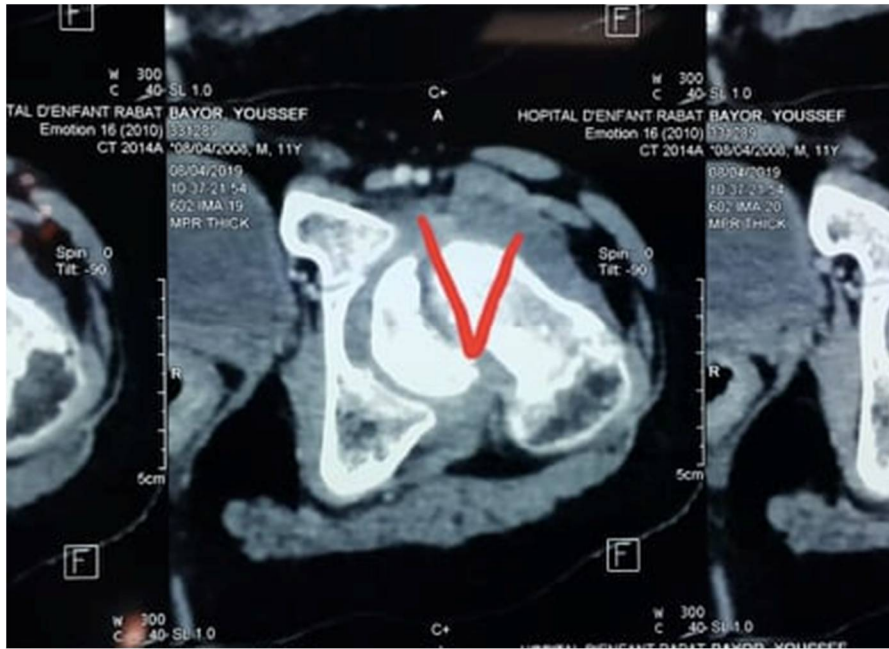


Figure 12 : Cross section, indicating the site of the femoral osteotomy.

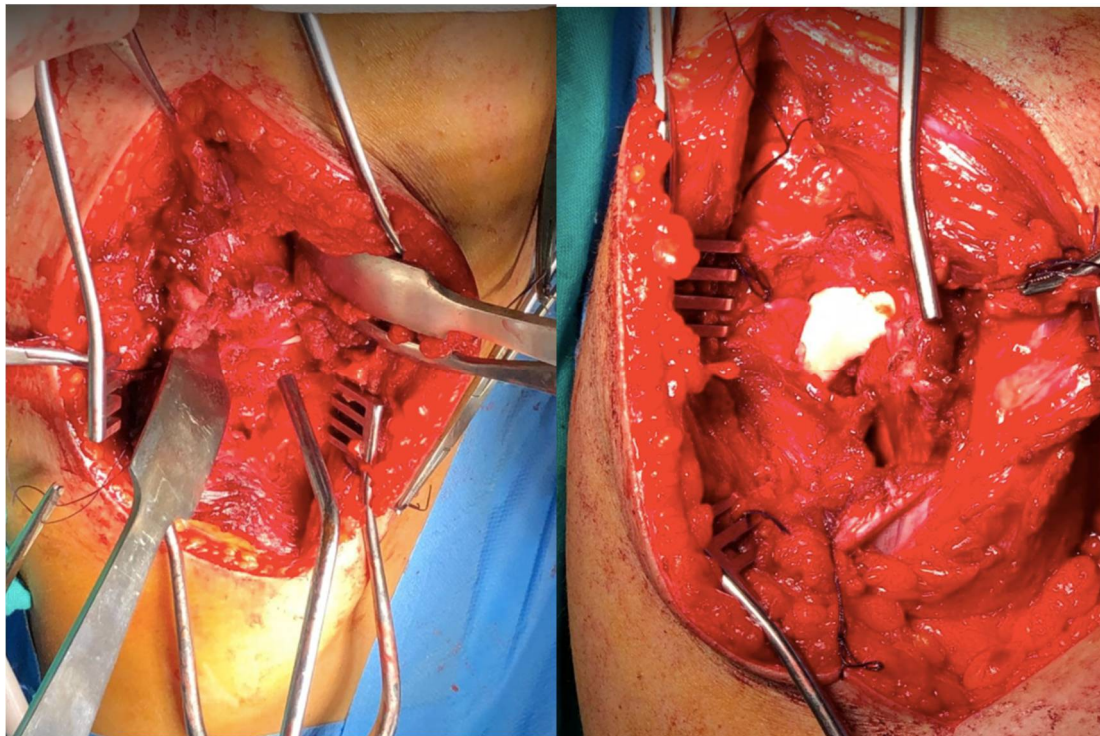


Figure 13 : Intra-operative images of the femoral head before and after capsulotomy.

➤ **Observation N° 5:**

Sara is an 11 year old girl who lives in sale, with no medical history. She was admitted in the hospital with a chief concern of limping and a right hip pain that have been evolving for 2 months.

The clinical examination on admission revealed a stiffness on mobilization of the hip, a positive Drehmann sign, as well as shortening of the right lower limb (RLL).

The front and profile X-rays showed a stage 3 SCFE (Fig 17).

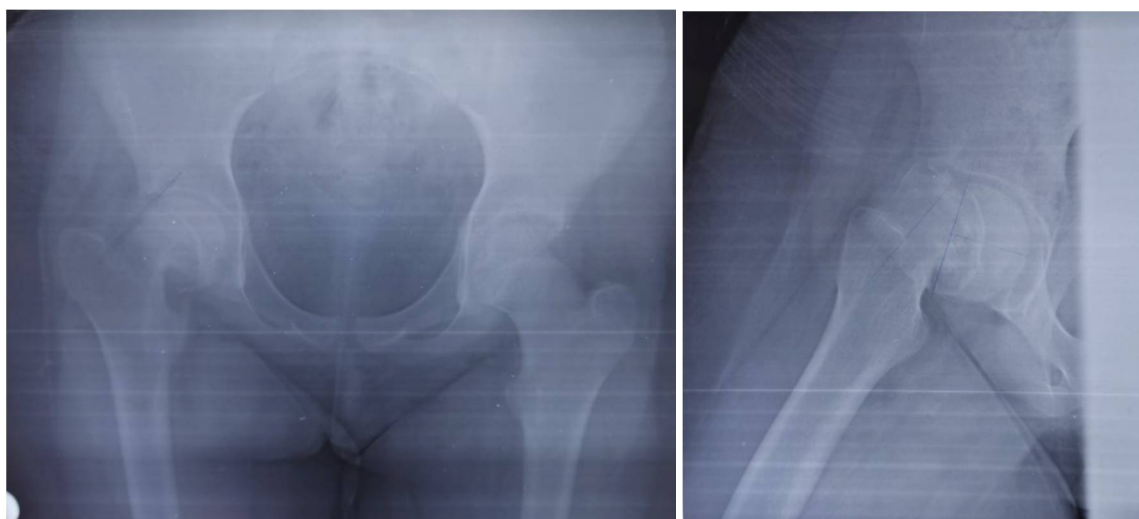


Figure 14 : front and profile X-rays showing a SCFE of the right hip.

The patient has undergone surgery using the classical Dunn technique. Monitoring of the femoral head perfusion during the surgery showed no blood flow both before and after reduction.

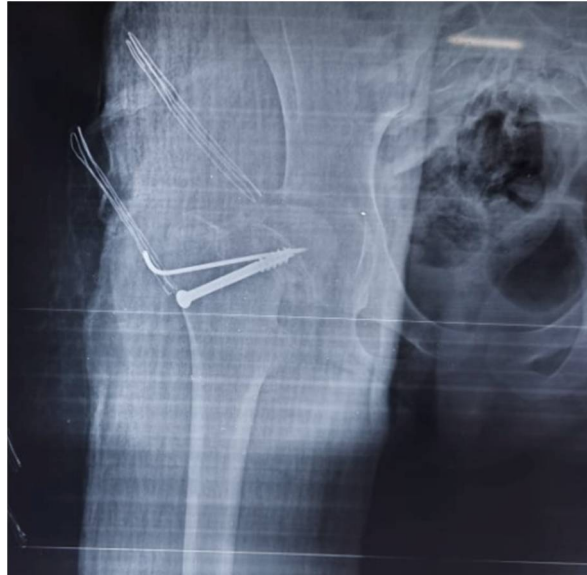

Figure 15 : Radiological control on 9 months follow-up

On her 12 months check-up, the patient showed clinical signs of deterioration, with hip pain and stiffness of the joint. The X-ray performed showed signs of AVN (fig 16). She will be scheduled for total hip arthroplasty.

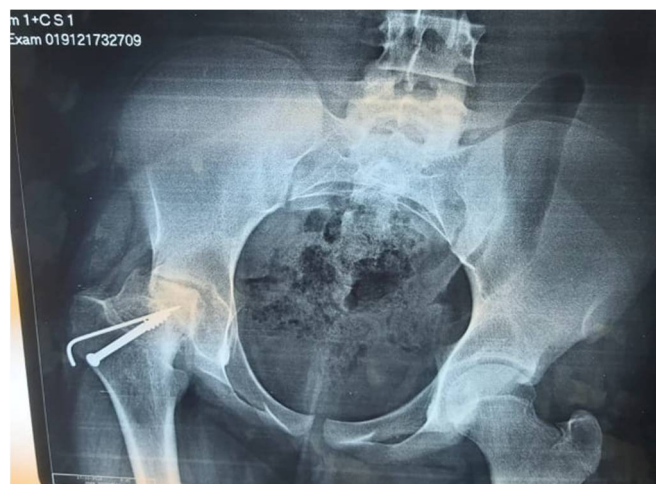

Figure 16 : Radiography showing collapse of the femoral head due to AVN.

All of the operations were performed by the same surgeon, using the same surgical technique, ensuring a certain homogeneity in the series. Epiphyseal perfusion was evaluated intraoperatively using a 2-mm drill hole to note bleeding from the femoral head.

The duration of postoperative follow-up ranged from a minimum of 25 months to a maximum of 48 months. The study reviewed data regarding the type of slip, the degree of correction obtained, clinical and functional outcomes, and complications.

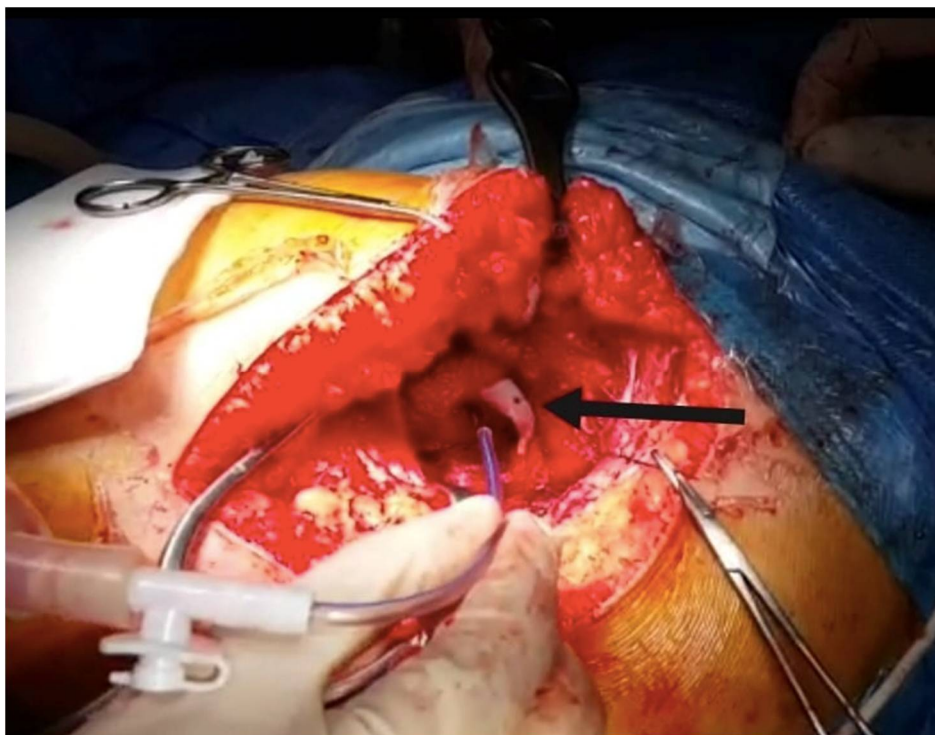


Figure 17 : The arrow indicates a positive bleeding sign during the operation of modified Dunn procedure using K-wire drilling of the femoral head.

4. Summary chart :

Table 1 : Overview table of clinical symptoms of the patients included in the study.

Patient	Sex	Age	Side	chronicity	Presence of trauma	Clinic	Stage of slip	Epiphyseal stability	Surgical technique	Hindsight
Ayman	M	14	L	Chronic	Absence	-Limping -Pain in L hip -Drehmann+ -Limited IR and abduction	Stage III	Stable	Classical Dunn	4 years
Amine	M	14	L	Chronic	Absence	-Limping -Pain - Leg length difference	Stage III + FAI	Stable	Classical Dunn	30 months
Keltoum	F	10	L	Chronic	Absence	-Pain & shortening of L lower limb -Lipming -Drehmann+	Stage III	Stable	Classical Dunn	25 months
Youssef	M	14	L	Chronic	Absence	-Left hip limping =Shortening of LLL -Drehmann+	Stage III	Stable	Classical Dunn	29 months
Sara	F	11	R	Chronic	Absence	-Limping -Stiffness -Leg length discrepancy - Drehmann+	Stage III	Stable	Classical Dunn	31 months

M=male ; F=female ; L=left; R=right; IR= internal rotation; LLL= left leg length

Results

1. Demographic data

1.1. Distribution according to age

The mean age in this study at time of operation was 12 years old, ranging from 10 to 14 years old.

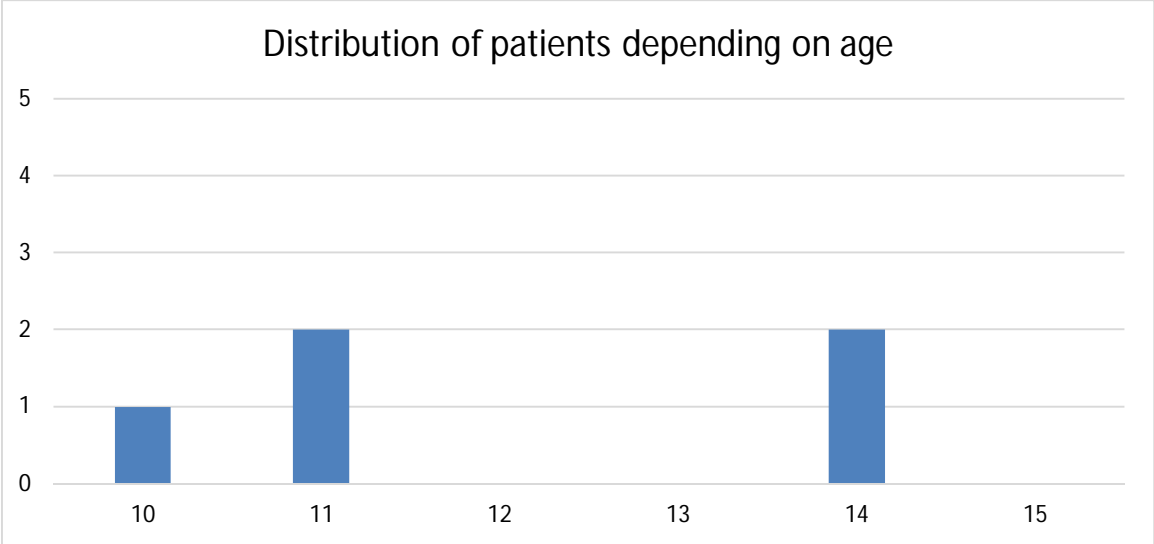


Figure 18 : Graph showing the distribution of patients by age

1.2. Distribution by gender

The study included 3 boys and 2 girls

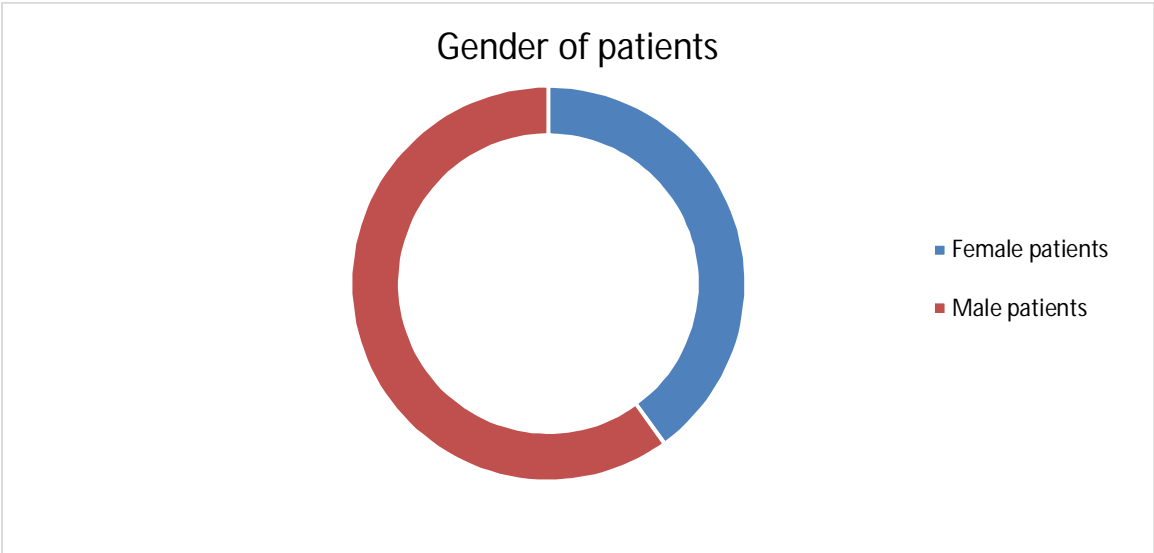


Figure 19 : Graph showing the distribution of patients by gender

1.3. Distribution depending on the affected side

The left hip was mainly affected in our cases, with 4 left hips compared to only one right hip.

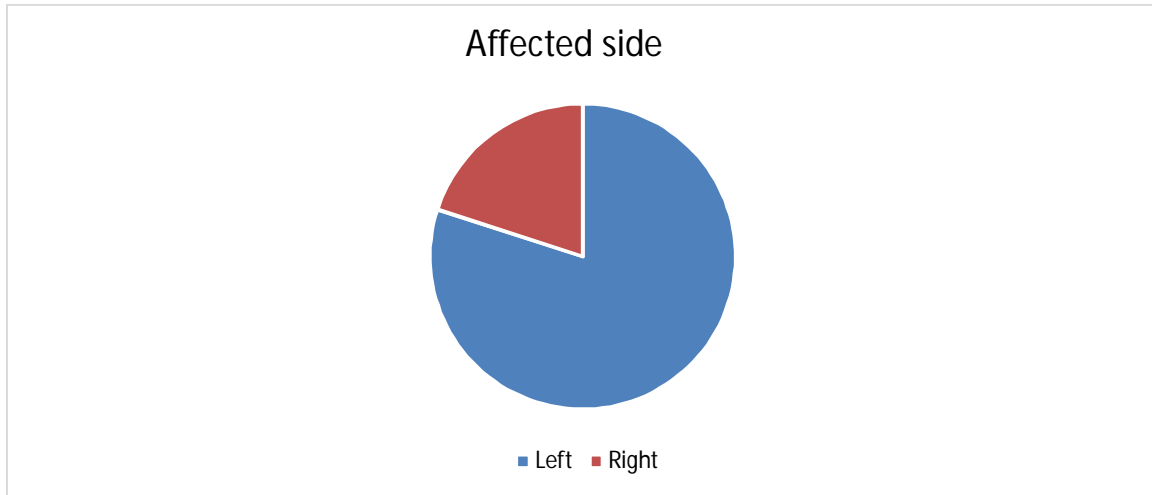


Figure 20 : Graph showing the distribution of patients based on the affected side

2. Clinical data

2.1. Reason for consultation

For all our patients, the main signs that motivate the consultation are the limping and pain that is spontaneous or appears while walking, localized essentially in the affected hip area.

The symptomatology is chronic in all the cases included.

2.2. Physical examination

All patients were in good general health condition. The clinical exam noted a positive Drehmann sign in all our patients, as well as a limited ROM that couldn't be calculated due to the pain when mobilizing the lower limb. One patient presented with shortening of the left lower limb.

3. Radiological data

The radiological assessment performed on all our patients consists of an X-ray of the pelvis and a CT-scan, allowing us to make a positive diagnosis of SCFE, to specify the direction of the displacement and to calculate its degree.

All slips were classified as severe according to the Southwick angle calculation. The mean slip angle was 68°, with extremes of 60° and 80°. The antero-posterior X-rays and the CT-scans also showed signs of chronicity of the SCFE (bony beak).

4. Conduct of the operation

All patients were operated according to the classical Dunn technique.

Intraoperative monitoring of blood perfusion of the femoral epiphysis was achieved by peripheral drilling of a 2-mm hole with a Kirschner wire in the anterior region of the femoral head to assess the presence of active bleeding. 4 femoral heads were positive bleeding. However, 1 patient (case 5) had showed no blood flow either before or after reduction.

No patient received prophylactic pinning with an intact contralateral hip.

5. Post-operative results

5.1. Assessment criteria

Clinical outcome was evaluated using the range of motion, the Harris Hip Score (HHS) and the Merle d'Aubigné Score. Radiological results were assessed mainly by the presence or absence of radiologically detectable complications.

5.2. Global results

In 80% of patients, the radiographic result was satisfactory. However, the clinical condition was even better than the radiographs suggested. The patients' quality of life was less affected even though the radiographic and functional results were not perfect. The HHS at time of follow up for these patients was an average of 95, and the mean Merle d'Aubigné score was 17,5. The hip function was good in post-operative, with near normal ROM.

However, the patient whose femoral head showed negative bleeding sign during the operation, developed AVN after a few months after the operation. Her clinical outcome was also considered bad.

All patients developed a leg length discrepancy in post-operative.

No patient has developed SCFE in the contralateral hip during the time of follow up. There was no re-operations, no loss of fixation, no breakage of osteosynthesis material and no delayed union.

6. Summay of results:

Table 2 : table gathering clinical and radiological results, as well as complications

Hip	Stability	Pre-operative angle	Harris hip score	Merle d'Aubigne score	Complications	Re-operations
1	Stable	60°	97	18	Leg length discrepancy Of 15 mm	None
2	Stable	73°	93	17	Leg length discrepancy	None
3	Stable	62°	97	18	Leg length discrepancy	None
4	Stable	80°	93	17	Leg length discrepancy	None
5	Stable	65°	28	4	Avascular necrosis	None



Discussion

1. Introduction:

Slipped capital femoral epiphyses (SCFE) have traditionally been morphologically classified into mild, moderate, and severe using the Southwick method. Higher grade slips are usually associated with poorer outcomes.

The goals of the treatment are to prevent further slippage and the occurrence of complications, and to correct very significant displacements. Up to date, there is still no consensus on how to treat SCFE.

The ideal treatment of moderate and severe slips has been debatable with two main schools of thought: For years, in situ fixation had been advocated as the treatment of choice for all types of slips [11, 12]. However, some authors have noted a more guarded long-term prognosis after in situ pinning, and a number of osteotomies have been described to restore the anatomy of the proximal femoral anatomy; including the sub-capital [13], cervical [14] and inter-trochanteric osteotomies [15, 16]. It was noted that osteotomies that were closer to the site of the deformity produced the best anatomic correction but were associated with the highest risk of avascular necrosis [17].

Dunn [13] described a technique for performing a subcapital osteotomy that shortened the femoral neck to preserve the blood supply to the femoral head. However, other authors have been unable to reproduce Dunn's results and have reported high complication rates with this technique [17-19]. On the other hand, extracapsular osteotomies, such as the intertrochanteric osteotomy, have a lower risk of avascular necrosis, but are limited by the severity of the deformity that can be corrected, as the deformity is treated indirectly [20].

Thus, Dunn's osteotomy remains the only procedure that allows the restoration of a normal or sub-normal anatomy of the upper extremity of the femur. It is used in the treatment of chronic epiphysiolysis with major displacement before closure of the growth plate, verified at the slightest doubt by a CT scan. This procedure is performed meticulously. It consists of several steps that are: exposure, osteotomy, reduction and fixation [21].

2. Indications of Dunn's subcapital osteotomy:

SCFE is associated with very variable degree of posterior translation of the epiphysis and simultaneous anterior displacement of the metaphysis.

The classic treatment of mild slipped capital femoral epiphysis has been in situ fixation with a single screw in the center-center position of the epiphysis [22]. It is recommended by most authors [11, 12, 23-25], who report that it provides the best long-term function and delay of degenerative arthritis, with a low risk of complications. Although there were many studies that involved large numbers of patients who underwent in situ pinning (Ponsetti [11] with 83 hips, Accadbled [25] with 222 patients) in the 20th and 21st centuries with very good outcomes, there are also some rare studies that report the use of the Dunn technique in the realignment of slipped epiphyses of less than 30°. In fact, Slongo et al. [26] included six mild slips treated with modified Dunn technique, while Ziebarth et al. [9] treated six hips of Southwick angle $\leq 30^\circ$ using the classical Dunn operation. Huber et al. [27] also had a few mild slips among the thirty hips they treated according to the modified Dunn procedure.

All authors agree that in situ pinning alone can't be sufficient to allow complete resolution of symptoms and improve function and hip motion in patients with severe stable SCFE. Thus, for severe slips, surgeons should attempt to decrease the degree of deformity or correct the deformity to minimize the long-term risk of cartilage damage [5, 13, 28].

However, if there's a consensus regarding the use of Dunn's procedure for slips over 60°, opinions differ when it comes to moderate SCFE.

In a study including 15 patients, all of them having chronic or acute on chronic slips with a slip angle $\geq 60^\circ$ and treated by the modified Dunn procedure, Ebert et al. [4] report a complication rate of 36%. Therefore, they believe that the modified Dunn procedure should only be considered if there is no other possibility to restore proximal femur geometry, as is the case in severe chronic or acute on chronic slipped capital femoral epiphysis. Otherwise, they recommend using other surgical procedures, such as Imhäuser osteotomy, for moderate stable slips ($< 50^\circ$), to limit the rate of complications [4].

Novais et al. conducted a study on 2014 [29] to compare 15 patients treated with the modified Dunn procedure and 15 others who underwent in situ pinning for severe stable SCFE, with a Southwick slip angle (SSA) ranging from 54° to 81°. They stated that the modified Dunn subcapital realignment procedure using a surgical hip dislocation approach results in better radiographic correction of the femoral head and neck deformity, superior clinical outcome, and lower reoperation rate compared with in situ pinning for the treatment of severe stable SCFE at an average of 2 years of follow up [29].

Carlioz and colleagues [30] carried out a study including 27 hips of SSA comprised between 58° and 90° treated using the Dunn's operation, with an outcome of 20 good results, 3 fair and 4 bad ones. Considering that 4 bad results for 27 Dunn's operations is a high failure rate, they recommend the use of Dunn's technique only for cases of SCFE with major displacements (60° to 90°) and open growth plate, because, if untreated, these will lead spontaneously to arthritis and a disturbance of hip function [30].

Authors who support the treatment of moderate SCFE following the Dunn procedure believe that it is the treatment of choice for the surgeon properly experienced with this method. Huber et al.[27] report excellent outcome in 28 hips out of 30 treated by the modified Dunn technique and only one case of AVN, in a series of SCFE with a mean pre-operative slip angle of 44,9°. In a study of 30 Indian patients, with 19 having stable and 11 unstable slips with $SSA \geq 30^\circ$, Agashe and co. stated that there were only two cases of osteonecrosis, both of them occurred in unstable slips [17]. Therefore, they concluded that the modified Dunn osteotomy should be the first choice for management for moderate and severe slipped capital femoral epiphysis.

The Bernese experience [26] described in 2010 emphasizes the importance of early treatment of moderate and severe SCFE using the modified Dunn technique. Slongo et al. reported that the present technique resulted in a low complication rate in his series of 23 SCFE with average slip angle of 47,6°, while allowing the restoration of a more normal anatomical relationship of the proximal part of the femur. They also stated that the mean range of motion of the treated hips was not notably different from that of the normal and contralateral hips [26]. The study conducted by Abdelazeem et al. add to the

current literature that suggests that the modified Dunn osteotomy carried out through Ganz approach is a safe and effective method of treating moderate and severe stable SCFE [31].

In the present study, we only considered patients with severe SCFE and open growth plate, who require anatomical reduction. Our results demonstrate that anatomic reconstruction is possible even in the most severe chronic forms of SCFE if treated according to the Dunn's osteotomy.

Table 3 : Comparison of patient criteria in different studies.

		Ziebarth et al [9] (2009)	Slongo et al.[26] (2010)	Dunn et al.[32] (1978)	Zuo et al.[33] (2020)	Elmarghan y et al.[34] (2017)	Current study
Mean age at operation	(Years)	12,5	11,9	13,8	13,2	14	12
Gender	Male	17	14	52	14	24	3
	Female	23	9	21	6	8	2
Affected hip	Left	28	14	—	5	11	4
	Right	12	9		14	17	1
					1 bilat.	2 bilat	
Chronicity	Acute	13	0	0	1	0	0
	Acute on chronic	0	14	25	0	0	0
	Chronic	27	9	48	20	32	5
Southwick classification	Mild	5	6		0	2	0
	Moderate	23	8	All	0	18	
	Severe	12	9	>30°	21	12	5
Mean follow-up	(Months)	42	29,3	8Y+10 M	31,2	14,5	32,6

3. Surgical technique:

3.1. Open vs arthroscopic surgery:

The surgical capital realignment technique, as initially described by Dunn [32], as well as the modified one using a surgical dislocation approach are originally described as open surgeries. This approach allows the realignment and offset of the head at the head-neck junction to be directly visualized. It also allows direct exploration and preservation of physeal blood supply.

All authors agree that it permits to control the vessels, decrease the tension on the vessels with an exact callus takedown and mild shortening, reduce the epiphysis to a near anatomic reduction, and assess blood flow, providing the greatest opportunity to achieve a successful result in the short and long term [13, 27, 33, 35, 36]. Slongo et al.[26] state that the open procedure allowed them to identify the reasons for the poor postoperative evolution in two patients and to provide an early specific treatment. Ziebarth et al. believe that the modified Dunn procedure using an open surgical approach can facilitate capital realignment by allowing full exposure of the proximal femur and allows subperiosteal dissection of the entire femoral neck [9].

Fish et al. emphasize the necessity for the surgical approach to provide sufficient exposure to allow complete visualization of the femoral head and neck. They reports that the surgeon must appreciate the pathologic anatomy of the involved hip and must know precisely the locations of the physis and femoral head [37]. Carlioz et al. [30] recommend the open postero external approach for it gives a very good view of the epiphyseal vascular pedicle and allows the femoral neck to be shortened as required and the slipping to be reduced anatomically.

On the other hand, the most published studies on arthroscopic treatment of SCFE focus primarily on the treatment of complications of the disease [38]. It consists mainly of arthroscopic osteoplasty to correct the consequent FAI [39].

However, although open surgery is considered by its proponents to be the gold standard in the treatment of SCFE since it offers almost 360° access to the hip joint, a recent study conducted by Dutra Roos et al. described an arthroscopic technique of subcapital realignment for the treatment of moderate and severe chronic and stable SCFE in patients with open physis [40]. This author affirms that direct arthroscopic visualization of the reduction is unreliable and may be difficult due to bleeding. Therefore, fluoroscopic prechecking in the anterior-posterior view may be necessary to check the amount of neck shortening and the reduction. Another study reports a case of a 12 year old boy treated by an arthroscopic Dunn technique, obtaining a significant improvement of the clinical picture and a partial correction of the slippage (from 70° to 30°) [41].

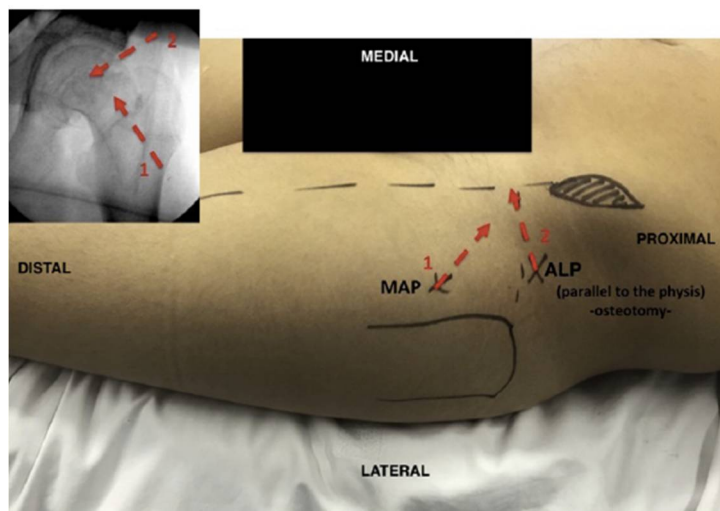


Figure 21 : Preoperative photo of a patient positioned for a left hip arthroscopy showing the portal placement [40].

MAP= mid-anterior portal= camera portal ; ALP= antero-lateral portal= working portal

The fluoroscopic image shows the projection of the MAP (1) and ALP (2).

For patients, this closed approach offers a potentially "less" invasive method to treatment, with less muscle dissection and faster recovery. Shorter hospitalization, minor bleeding and low rate of infection, as well as the aesthetic result that is superior to that of the open method, are also to be considered [42]. Hip arthroscopy has the advantage over open surgery in terms of decreased morbidity, reduced recovery time, and an earlier return to activity [28].

3.2. Classical vs modified Dunn procedure:

Conventional treatment of slipped capital femoral epiphysis consisted of in situ fixation with wires or screws. Although clinical studies may have reported good results, radiological evidence showed significant alterations in the proximal femur [43]. And in long term follow up, in unreduced epiphysis, FAI leads to mechanical derangement of the hip and development of secondary osteoarthritis. Thus, in 1964, Dunn developed a subcapital realignment procedure to allow for correction at the level of the deformity.

The classical procedure defined by Dunn consists in a capsule incision in the axis of the neck, followed by a careful dissection of the periosteum. The posterior part is removed to the edge of the head and to the base of the neck, for the base of the posterior flap provides the blood supply to the femoral head. The head is then detached, preserving its blood supply. Then the neck is shortened by a cut just distal to the epiphyseal line. The segment of bone removed is trapezoidal and includes the posterior bony beak. Removal of the remaining growth plate is an additional surgical step to accelerate consolidation and promote revascularization of the epiphysis [13, 32].

Dunn et al. conducted a study in 1988 that included 70 hips with chronic slip, treated with this technique, in which the incidence of complications was low, namely two AVN and five chondrolysis, and one patient that developed both. On the other hand, results in hips with acute on chronic slips were less satisfactory, with 26% of early complications, grown to 29% of late ones. Carlouz et al. also used the classical Dunn technique to treat 27 cases. Their study reported an outcome of 14% of complications, one of them was a postoperative infection, not specific to this type of operation. A study carried out by Fron et al. in 50 cases of severe slips treated by Dunn's osteotomy found that clinical results were good and very good in 90% of the cases, and fair or poor in 10% [44].

In 2009, Ziebarth et al [9] proposed a procedure that combined Dunn's subcapital osteotomy with the safe Ganz surgical hip dislocation. In a series of 40 moderate to severe slips, they were successfully able to restore proximal femoral alignment while preserving blood supply to the capital femoral epiphysis in all cases. In recent years, the modified Dunn osteotomy has gained popularity to treat SCFE, with various complication rates. Most studies included patients with different severities.

Table 4 : Table: comparison of results in studies of different surgical methods [9, 26, 30, 32-34, 45, 46]

	Ziebarth et al. (Switzerland)	Slongo et al. (USA)	Dunn, Angel (UK)	Carlioz et al. (USA)	Javier et al. (Argentina)	Lawane et al. (France)	Zuo et al. (China)	Elmarghany & al. (Egypt-Italy)	Current study
Number of hips	40	23	73	27	21	25	21	32	5
Surgical technique	Modif. Dunn	Modif. Dunn	Classical Dunn	Classical Dunn	Modif. Dunn	Classical Dunn	Modif. Dunn	Modif. Dunn	Classical Dunn
Characteristics of the hips	—	20 stable 3 unstab.	—	All > 55°	71% unstable	100% severe	100% severe	100% chronic	100% severe
Clinical outcome	100% good	21 good 2 bad	55 good 6 fair 12 bad	23 good 4 bad	15 good 6 bad	19 good 6 bad	20 good	29 good 3 poor	4 good 1 poor
Rx outcome (total complication rate)	0% long-term or major complic.	13% complic.	G: 56% F: 16,4% B: 27,4%	25,9% complic.	51% complic.	40% complic.	5% complic.	15,7% complic.	20% complic.

3.3. Monitoring of the femoral head perfusion:

Monitoring the perfusion of the femoral head is believed to be important in surgery that preserves the hip joint. To prevent the development of epiphyseal necrosis in SCFE and to optimize treatment outcomes, it is important to study the epiphyseal hemodynamics both preoperatively and intraoperatively [47, 48].

It is possible to assess the hemodynamics before the surgery by performing a simple [49] MRI or with contrast, a femoral head angiography, or bone scintigraphy [48].

In intra-operative, a first step is inspection of the continuity of the retinaculum that carries the main blood flow to the femoral head. One of the advantages of subcapital realignment using the Dunn procedure is the visualisation and preservation of the vascular retinaculum, and the direct evaluation of femoral head perfusion during surgery. Femoral head perfusion can be assessed either by bleeding assessment after creation of a 2-mm drill hole [48, 49], by using laser-Doppler flowmetry (LDF) [27] and/or by means of intracranial pressure probe (ICP) monitoring [50].

In this study, femoral perfusion was assessed intra operatively using a drill hole, and bleeding sign was checked before and after reduction. The patient who developed AVN had no blood flow either before or after osteotomy and reduction of the epiphysis. With a sensitivity and specificity of 100% in our series, these outcomes supports the previous findings of Madan et al. [49].

A study conducted by Novais et al.[51] that compares different methods of perfusion monitoring used in the same patients, concluded that both assessment of active bleeding of the femoral head and ICP monitoring are effective in detecting patients who are at high risk of developing AVN. Although, it showed that ICP monitoring before dissection had good sensitivity, while bleeding after final fixation was a highly (100%) specific test.

4. Post-operative complications:

Although the goal of treatment is to minimize complications, the reported overall complication rate of SCFE remains high. Historically, surgical methods of realignment have been associated with a high number of complications with the risk of avascular necrosis reportedly ranging up to 53,8% [52]. The modified Dunn procedure with realignment of the epiphysis offers the possibility of restoring proximal femoral anatomy and a ROM without impingement. In addition, this procedure allows for control of epiphyseal vascularization and restoration of epiphyseal perfusion. Some studies showed promising results, notably those of Ziebarth et al. and Slongo [9, 26]. Furthermore, long term follow up showed that hip function was improved and pain was decreased at 10 year follow up in hips treated using the modified Dunn procedure for SCFE, meanwhile more hips showed signs of progression of OA [53].

Commonly reported complications include osteonecrosis (ON) of the femoral head, chondrolysis, femoroacetabular impingement associated with articular cartilage and labral damage, fixation failure and progression of deformity, growth arrest, and development of bilateral disease.

4.1. Avascular necrosis:

Avascular necrosis of the femoral head is probably the most feared complication related to SCFE, for it is associated with the poorer outcome. The etiology of AVN is not completely elucidated, but is likely multifactorial. Potential causes are a tear or anatomic disruption of the retinacular vessels to the epiphysis, kinking of the retinacular vessels, or an intracapsular tamponade caused by hemorrhage.

Clinically it is revealed by joint pain and decreased mobility. Radiographically, AVN is characterized by areas of radiolucency and segmental sclerosis that ultimately result in femoral head collapse. These changes usually occur in a subchondral location [54]. However, the development of AVN after treatment for SCFE develops usually within the first months and is rarely seen on plain radiographs beyond two years [55].

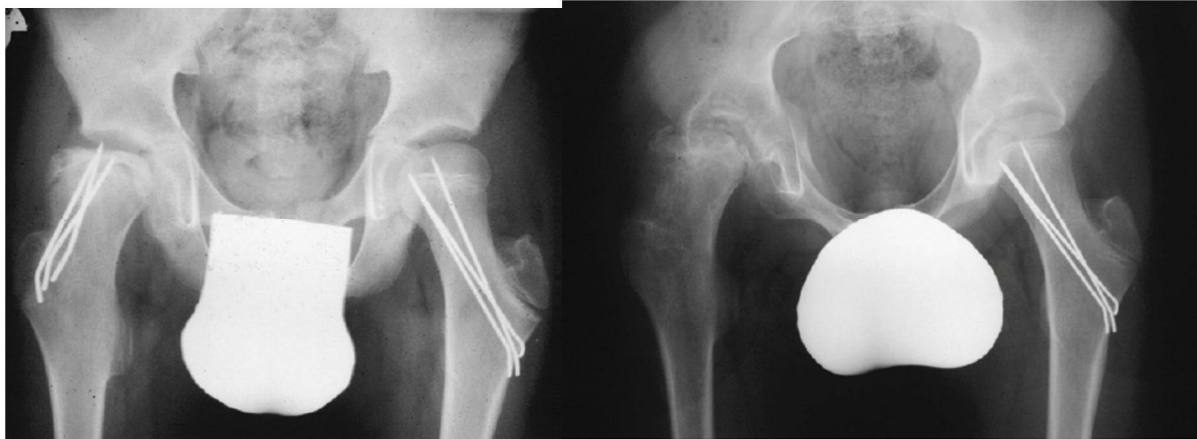

Figure 22 : X-ray image of AVN.

A male patient aged 10 years 2 months with right-sided SUFE who underwent pinning of both sides. In post-operative, two pins were projecting beyond the bony femoral epiphysis on the right. Hip pain persisted and a radiograph 4 month later shows avascular necrosis of the right femoral head with marked collapse (left). A further 13 months later, the right femoral head has virtually disappeared (right) [54].

The use of Dunn osteotomy for SCFE reduction was first reported in 1978 for the treatment of 73 hips (48 chronic and 25 acute cases). Among the 25 acute SCFEs, 9 hips developed AVN: 2 had complete AVN, 3 had segmental AVN, and 4 had mottling [32]. Another study that included 28 patients with SCFE treated by the modified Dunn procedure reports that two patients had proven pre-existing AVN and two developed the condition postoperatively [49].

A careful analysis of the risks of AVN following the 2 main types of treatment (in situ pinning and open reduction through a surgical hip dislocation and modified Dunn osteotomy) for an unstable SCFE demonstrate a very wide range of results. Both techniques have studies reporting a 0% AVN rate [9], whereas the highest AVN rate for in situ pinning is 47% [56] and Dunn osteotomy is 26%, reported by Sankar et al. in a large multicenter study [57]. A long-term follow-up series by Velasco et al. demonstrated that of 60 hips treated with the classical Dunn procedure for SCFE, the majority of the cases had good and moderate outcomes and only 7 cases (11.7%) had evidence of AVN [18]. The authors noted that compared with the natural disease course, the long-term outcome seems to be improved by open reduction of the femoral head.

Table 5 : Table: comparison of post-operative AVN with the literature series.

	Total N° of SCFE	N° of AVN	% of AVN
Velasco et al. [18] (1998)	60	7	11.7%
Lawane et al. [46] (2009)	25	4	16%
Ziebarth et al.[9] (2009)	40	0	0
Slongo et al. [26] (2010)	23	1	4,34%
Sucato et al. [58] (2010)	15	1	6,67%
Huber et al. [27] (2011)	30	1	3,33%
Davis et al. [59] (2017)	31 unstable 17 stable	2 5	6% 29,5%
Elmarghany et al. [34] (2017)	31	3	9,4%
Ebert et al. [4] (2019)	15	4	26,67%
Passaplan et al. [7] (2020)	18	2	11,11%
Current series (2021)	5	1	20%

One case in our series developed AVN, and had no sign of blood flow during the intra-operative monitoring.

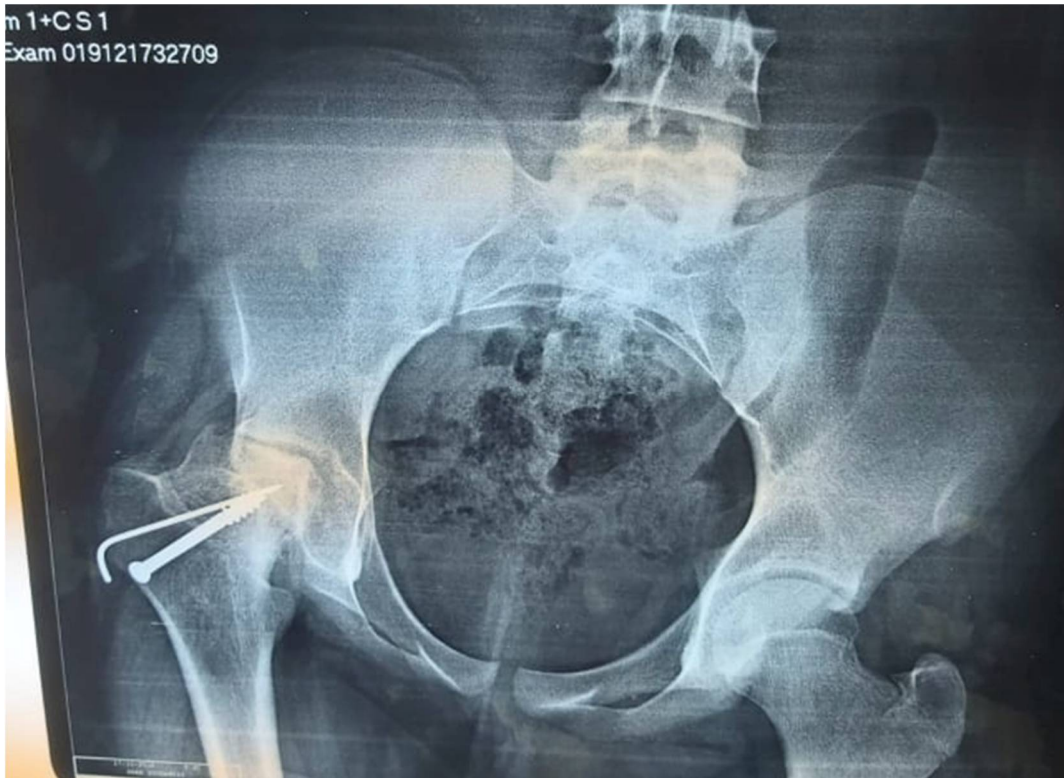

Figure 23 : Radiological image 12 months after surgery of case 5 in our study that developed AVN

Necrosis leads very quickly to a deformation of the head due to the sinking of the necrotic area of bone. It results in hip pain and joint stiffness.

There is a wide range of surgical treatments available for the management of femoral head necrosis, from hip joint preserving therapy to hip arthroplasty. The only treatment for AVN may be a prolonged period of traction, which may be appropriate provided that the epiphysis has not lost too much of its sphericity and that the patient still has some remodeling potential. If the necrotic femoral head is too deformed, and the hip is stiff and painful, then hip replacement by arthroplasty is required [1, 60].

4.2. Chondrolysis:

Chondrolysis is the second serious complication of SCFE, that can occur in treated and untreated cases. Its exact etiology has not yet been conclusively identified. Although a number of risk factors seem to favor the occurrence of chondrolysis, the most important of which are the severity of slip and the intra-articular protrusion of the osteosynthesis material, in addition to intra-articular or trochanteric realignment osteotomies [1, 61].

Chondrolysis is essentially revealed by a stiffness of the hip associated with a vicious attitude. Pain is not the primary complaint in most patients. Articular limitation mainly affects extension, internal rotation and adduction.

Radiologically, chondrolysis is defined by a joint space reduction of more than 50% of the affected hip, or a joint space measuring less than 3 mm in case of bilaterally abnormal hip joints. Normal hip joints should have a cartilage thickness of 4 to 5 mm for the age group affected by SCFE, measured on anteroposterior radiographs of the hips. Other characteristic lesions of chondrolysis can also be noted in X-ray images, namely: an overall demineralized aspect of the joint affecting the femoral head and the acetabulum; the disappearance of the subchondral osseous line on both the acetabular and femoral surfaces; and the fusion of the articular cartilage [1, 54].

The overall incidence of chondrolysis is believed to be 7%, depending on the series, but has been reported to vary from 0 to 55% [61, 62]. In our series, we did not record any complication of this kind during the follow-up period.

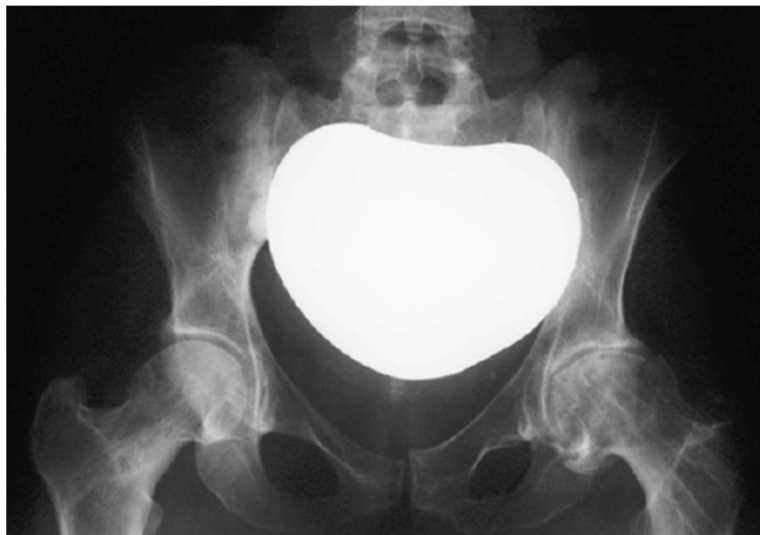
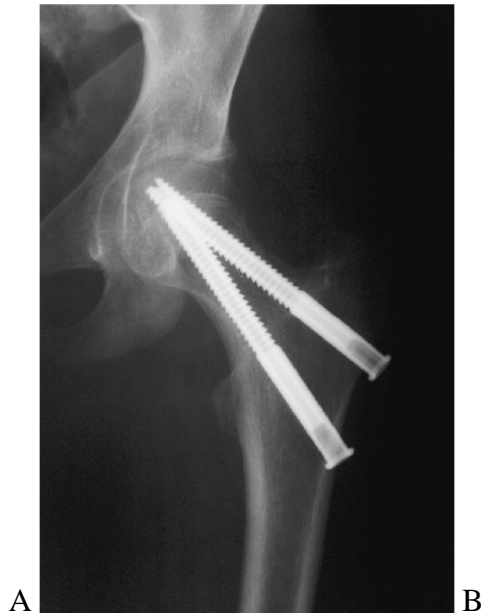
Figure 24 : Radiological images of chondrolysis.

A girl aged 16 years and 6 months who was already treated for a right-sided SCFE 1 year before, presented a relapse on her left hip, that was also treated. The patient complained of persistent pain, when an x-ray realized 4 weeks after the operation (A) showed loss of hip joint space, indicating a chondrolysis. 6 years later, the head started to collapse due to impingement (B) [54].

The evolution of chondrolysis is not predictable. The initial acute stage of chondrolysis, associated to an initial decreased motion, lasts around 6 months. In 50 to 60% of cases there is a reconstitution of the joint space and improvement of ROM after the acute stage. In the other cases, the chronic stage would last several years, with progressive joint destruction resulting in a painful or painless ankylosis [54, 61].

4.3. Leg length discrepancy:

Epiphysiodesis prevents further slipping of the epiphysis onto the metaphysis and has therefore become a step in most surgical treatments for SCFE, including the Dunn realignment procedure. The average age of most patients treated for SCFE is 12 years, and with the goal of epiphysiodesis, one is expected to lose 3 mm per year of limb growth from the proximal femoral shaft. Physeal closure usually occurs after 5 to 6 months.

In this study, we encountered this complication in most cases during the observation period. Although one case had already presented with leg length discrepancy in pre-operative.

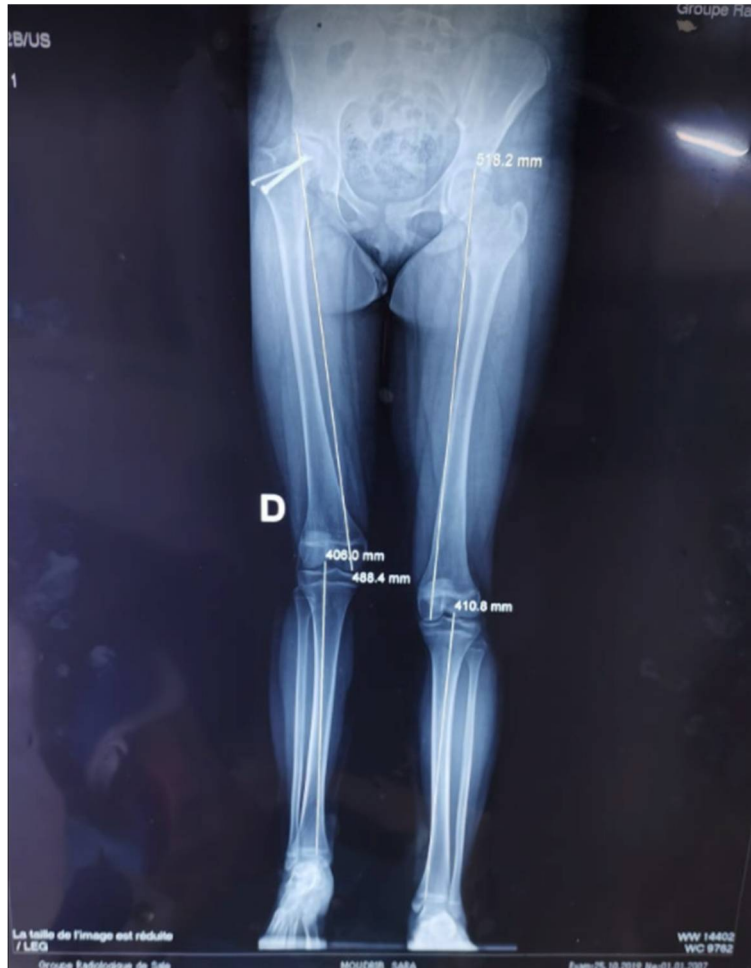

Figure 25 : Radiological image of leg length discrepancy in a case from our series, one year after surgery.

Growth arrest of the proximal femoral physis has several potential consequences, especially in young patients. It creates uneven leg lengths and alters growth parameters of the femur, and these include femoral neck shortening and relative trochanteric overgrowth, extra-articular impingement, coxa vara, and a consequent change in gait patterns.

There is evidence that the type of implant used for fixation can affect growth continuity, including early closure of the physis and shortening of the femoral neck.

Hansson [63] developed a hook-pin that has proven effective in different surgical techniques for the treatment of SCFE. He reported that 28 asymptomatic hips (prophylactic pinning) and 27 of 37 hips (73%) with slipped epiphyses showed no tendency towards premature closure during a postoperative follow-up period of 1 to 6 years.

Further development of techniques and implants that allow stable fixation and ongoing growth could be beneficial for patients with significant growth remaining.

4.4. Other complications related to surgical treatment of SCFE:

A number of other complications may also occur after this operation, including: progression of postoperative slippage; loosening, rupture, or migration of metal implants; rotation of the femoral head; subtrochanteric fractures; and local infection.

Postoperatively, there may be a spontaneous reduction or increase in the slip angle. This indicates insufficient stability of the surgical fixation and must be corrected [54].

Joint infection is a potential complication after all kinds of surgery. The radiological signs are identical to any other joint infection; an early sign being a joint collection. If there's a clinical suspicion, a drainage of the joint should be performed, as in all other cases of suspected septic arthritis. The infection may also be limited to the metal implant without affecting the hip joint.

In this series, no patient has developed any of the latter complications, even if some of them are quite common, namely fracture of osteosynthesis material and postoperative infections. Carlioz [30] reported one case of severe infection among 28 hips treated with Dunn's operation. Ziebarth [9] recorded 3 patients out of 40 who were reoperated due to breakage of a screw or wire fixation.

There are some limitations related to the nature of our study: first, the retrospective approach; second, the absence of a control group, such as one with in-situ pinning, for comparison. Besides, we did not report the preoperative ROM, as it was difficult, if not impossible to have a measurement in a child with a painful hip. The limitations also include the non-use of the doppler ultrasound flowmetry to detect perfusion in intra-operative. In addition, the small number of patients and short-term follow-up can have a significant impact on the information we can interpret. Most of these limitations are shared with other studies of such a complex and uncommon lesion.



Conclusion

Despite its limitations, this study represents a series of severe cases of SCFE treated with the classic Dunn procedure.

Dunn's procedure for osteotomy and realignment of the femoral head is an ideal treatment strategy for SCFE as it aims to restore the original anatomy in order to prevent further early degeneration of the hip, reduce pain, and avoid the need for total hip arthroplasty (THA) in young and active SCFE patients.

This procedure is undoubtedly demanding and requires extensive training based on a precise knowledge of anatomy. However, we believe that the investment in effort and skill is well worth it for this condition that can have lifelong consequences for the young and active population affected.

However, osteotomies should be reserved for very complex forms, i.e. severe displacements. Besides, certain conditions should be met, including avoiding forced reduction of the femoral head, and ensuring that the osteosynthesis material does not protrude into the hip joint.

All of Dunn's interventional series report a risk of necrotic complications with variable percentages. Avascular necrosis may be encountered primarily if there is no evidence of intraoperative perfusion of the femoral head before and after epiphyseal realignment. This was the case for our patient who developed AVN.

Nevertheless, when the surgical approach to hip dislocation and femoral neck osteotomy described by Dunn go well, both challenges of this pathology are optimally handled, allowing to reduce the epiphysis to a normal position, while avoiding FAI and AVN, and the patient is left with a basically normal hip. If this is achieved between 75% and 100% of the time and more probably between 85% and 90% of the time, then these results are superior to the outcome achieved with in situ pinning (simple fixation or partial reduction) and the patient's hip is destined to develop FAI and early OA.



Abstract

Abstract

Title: Dunn technique in treatment of severe slipped capital femoral epiphysis.

Author: Houda Boudida

Supervisor: Pr. Amrani Abdelouahed

Key-words: slipped capital femoral epiphysis, Dunn procedure, subcapital realignment, avascular necrosis.

Introduction: Slipped capital femoral epiphysis (SCFE) is a slippage of the proximal femoral epiphysis through the femoral neck. It is the most common hip disorder in adolescents.

SCFEs with severe displacement inevitably progress into arthritis, making surgical recovery of normal anatomy an interesting objective. This can be achieved using the technique described by Dunn, which is an osteotomy at the level of the physis that can correct the anatomy and allows the alignment at the head/neck junction. However, all published studies about this technique report a risk of avascular necrosis.

Objectives: The aim of this study is to present the results of the Dunn technique, to analyse and compare them with literature data.

Material and methods: We retrospectively studied 5 patients (2 females and 3 males) who underwent a Dunn procedure for a SCFE over a 4 year period. They were all treated by a single senior pediatric orthopaedic surgeon. The mean age in our study was 12 years (10-14 years), and all patients had severe SCFE according to the Southwick classification.

Clinical and radiographic records were reviewed to obtain demographic data, to classify severity and physeal stability; and to measure the outcomes using clinical scores, radiological results and rate of complications.

Results: The average duration of follow up was 30 months. Surgical reduction was attained in all cases. One femoral head had no bleeding after drilling during surgery, and developed later an avascular necrosis. The other patients had good clinical and radiographic outcomes, with a range of motion not different of that of the normal contralateral hip.

Conclusion: the Dunn osteotomy has been shown to be effective in the treatment of severe stable SCFEs. However, it is a technically demanding surgery with highly variable results and rate of complications, notably AVN.

Résumé

Titre : la technique de Dunn dans le traitement de l'épiphysiolyse fémorale supérieure.

Auteur : Houda Boudida

Rapporteur : Pr. Amrani Abdelouahed

Mots-clés : épiphysiolyse fémorale supérieure – technique de Dunn – réalignement de la tête fémorale – nécrose avasculaire.

Introduction : L'épiphysiolyse fémorale supérieure (EFS) est un glissement de l'épiphyse fémorale proximale à travers le col du fémur. Les EFS à grand déplacement évoluent inévitablement vers l'arthrose, ce qui fait du rétablissement chirurgical de l'anatomie normale un objectif intéressant. Ceci peut être atteint en utilisant la technique décrite par Dunn, qui est une ostéotomie au niveau de la physe pour corriger l'anatomie à la jonction tête/col. Cependant, toutes les études publiées sur cette technique rapportent un risque de nécrose avasculaire.

Objectifs : La présente étude a pour but de décrire les résultats de la technique de Dunn, les analyser et les comparer aux données de la littérature.

Matériel et méthodes : Nous avons étudié rétrospectivement 5 patients qui ont bénéficié de procédure de Dunn pour EFS sur une période de 4 ans. Ils ont tous été traités par un seul chirurgien orthopédique pédiatrique senior. L'âge moyen dans notre étude était de 12 ans, tous les patients présentaient une EFS sévère selon la classification de Southwick.

Les dossiers cliniques et radiographiques ont été examinés afin de recueillir les données démographiques, de classer la gravité et la stabilité, et de mesurer les résultats cliniques, radiologiques et le taux de complications.

Résultats : La durée moyenne du suivi était de 30 mois. Une réduction chirurgicale a été obtenue dans tous les cas. Une tête fémorale n'a pas présenté de saignement après le forage pendant l'opération, et a développé ultérieurement une nécrose avasculaire. Les autres patients ont eu de bons résultats cliniques et radiographiques, avec une amplitude de mouvement comparable à celle de la hanche controlatérale normale.

Conclusion : L'ostéotomie de Dunn s'est avérée efficace dans le traitement des SCFE sévères et stables. Cependant, il s'agit d'une chirurgie techniquement exigeante dont les résultats et le taux de complications, notamment la NAV, sont très variables.

ملخص

العنوان : تقنية دان في علاج انفصال مشاش عظم الفخذ العلوي

المؤلف : هدى بوبيدي

المشرف : الأستاذ عمراني عبد الواحد

الكلمات الأساسية : انزلاق مشاش عظم الفخذ العلوي - تقنية دان - تنخر رأس الفخذ

مقدمة : انفصال مشاش عظم الفخذ العلوي هو انزلاق المشاش عظم الفخذ عبر عنق العظم .

انفصال المشاش ذو إزاحة كبيرة يتطور حتمًا إلى هشاشة العظام ، مما يجعل الاستعادة الجراحية للتشريح الطبيعي هدفًا مثيرًا للاهتمام .يمكن تحقيق ذلك باستخدام التقنية التي وصفها دان، وهي قطع جزء من العظم على المستوى العنق والتي تمكن من تصحيح تركيبه البنيوي .مع ذلك، فإن جميع الدراسات المنشورة على هذه التقنية تشير إلى إمكانية الإصابة بنخر رأس عظم الفخذ.

المواد و الطرق : درسنا بأثر رجعي 5مرضى (فتاتان و 3فتيان (خضعوا لعملية دان لعلاج

انفصال مشاش عظم الفخذ العلوي على مدى 4سنوات .كان متوسط العمر في دراستنا 12سنة (10-14) سنة (، وكان جميع المرضى يعانون من انفصال متقدم لمشاش عظم الفخذ العلوي .تمت مراجعة السجلات لجمع البيانات الديموغرافية ، وتصنيف الشدة، وقياس النتائج السريرية والإشعاعية، ومعدل المضاعفات .

النتائج : كان متوسط مدة المتابعة 30 شهرًا .تم الحصول على التركيب البنيوي الطبيعي في جميع

الحالات .في حالة واحدة لم يُظهر رأس عظمة الفخذ نزيقًا بعد الحفر أثناء العملية ، وبالتالي أصيب بنخر . كان لدى المرضى الباقيين نتائج سريرية وشعاعية جيدة ، مع استعادة حركة العضو مماثلة لتلك الموجودة في الورك المقابل الطبيعي

الخلاصة : لقد ثبت أن تقنية دان فعالة في علاج انزلاق مشاش عظم الفخذ العلوي الشديد .غير أن

جميع سلسلات عملية دان تؤكد على خطر المضاعفات، خصوصًا منها التنخرية.



Appendices

Annex 1: Harris Hip Score

Pain

<input type="checkbox"/> None or ignores it	+44
<input type="checkbox"/> Slight, occasional, no compromise in activities	+40
<input type="checkbox"/> Mild pain, no effect on average activities, rarely moderate pain with unusual activity; may take aspirin	+30
<input type="checkbox"/> Moderate pain, tolerable but makes concession to pain. Some limitation of ordinary activity or work. May require occasional pain medication stronger than aspirin	+20
<input type="checkbox"/> Marked pain, serious limitation of activities	+10
<input type="checkbox"/> Totally disabled, crippled, pain in bed, bedridden	+0

Limp

<input type="checkbox"/> None	+11
<input type="checkbox"/> Slight	+8
<input type="checkbox"/> Moderate	+5
<input type="checkbox"/> Severe	+0

Support

<input type="checkbox"/> None	+11
<input type="checkbox"/> Cane for long walks	+7
<input type="checkbox"/> Cane most of the time	+5
<input type="checkbox"/> One crutch	+3
<input type="checkbox"/> Two canes	+2
<input type="checkbox"/> Two crutches or not able to walk	+0

Distance Walked

<input type="checkbox"/> Unlimited	+11
<input type="checkbox"/> Six blocks	+8
<input type="checkbox"/> Two or three blocks	+5
<input type="checkbox"/> Indoors only	+2
<input type="checkbox"/> Bed and chair only	+0

Sitting

<input type="checkbox"/> Comfortably in ordinary chair for one hour	+5
<input type="checkbox"/> On a high chair for 30 minutes	+3
<input type="checkbox"/> Unable to sit comfortably in any chair	+0

Enter public transportation

<input type="checkbox"/> Yes	+1
<input type="checkbox"/> No	+0

Stairs

<input type="checkbox"/> Normally without using a railing	+4
<input type="checkbox"/> Normally using a railing	+2
<input type="checkbox"/> In any manner	+1
<input type="checkbox"/> Unable to do stairs	+0

Put on Socks and Shoes

<input type="checkbox"/> With ease	+4
<input type="checkbox"/> With difficulty	+2
<input type="checkbox"/> Unable	+0

Absence of Deformity (All yes = 4, Less than 4 = 0)

<input type="checkbox"/> Less than 30° fixed flexion contracture	-
<input type="checkbox"/> Less than 10° fixed abduction	-
<input type="checkbox"/> Less than 10° fixed internal rotation in extension	-
<input type="checkbox"/> Limb length discrepancy less than 3.2cm	-

Range of motion (* indicates normal)

Flexion (*140°): _____
 Abduction (*40°): _____
 Adduction (*40°): _____
 External Rotation (*40°): _____
 Internal Rotation (*40°): _____

Scoring Guide:

Range of Motion:

Total range of motion:

$211^{\circ} - 300^{\circ} = 5$ points

$161^{\circ} - 210^{\circ} = 4$ points

$101^{\circ} - 160^{\circ} = 3$ points

$61^{\circ} - 100^{\circ} = 2$ points

$31^{\circ} - 60^{\circ} = 1$ point

$0^{\circ} - 30^{\circ} = 0$ points

Range of motion score: _____

Total Harris Hip Score:

Harris Hip Score: Summation of points

Harris Hip Score: _____ Points

Score <70 : Poor results

Score 70 – 79: Fair

Score 80 – 89: Good

Score 90 – 100: Excellent

Annex 2 : Merle d'Aubigné score

Criteria*	Assessment	Score (Points)
Pain	Intense and permanent	0
	Severe even at night	1
	Severe when walking, prevents any activity	2
	Tolerable with limited activity	3
	Mild when walking, disappearing at rest	4
	Mild and inconsistent; normal activity	5
	No pain	6
Mobility	Ankylosis with bad position of hip	0
	No movement, pain or slight deformity	1
	Flexion <40°	2
	Flexion 40°-59°	3
	Flexion 60°-79°, foot can be reached	4
	Flexion 80°-90°, abduction of at least 15°	5
	Flexion exceeds 90°, abduction of 30°	6
Ability to walk	None	0
	Only with crutches	1
	Only with canes	2
	With one cane, less than an hour, very difficult without cane	3
	A long time with a cane, short time without cane and limping	4
	Without cane, slight limp	5
	Normal	6
Absolute results for hip function†	Very good	11-12
	Good	10
	Medium	9
	Fair	8
	Poor	≤7
Relative results‡	Very great improvement	≥12
	Great improvement	7-11
	Fair improvement	3-6
	Failure	≤2

*The Merle d'Aubigné hip score⁷ includes the parameters pain, mobility, and ability to walk, with each rated from 0 points (worst condition) to 6 points (best condition). †Addition of the scores for pain and mobility results in an absolute estimation of hip function. ‡Difference between preoperative and postoperative status (all three categories, with pain and walking ability multiplied by two before being added).



Bibliography

1. Odent, T., Pannier, S., & Glorion, C., *Épiphysiolyse fémorale supérieure*. EMC - *Appareil Locomoteur*, 1(1), 1–9. 2006.
2. Novais, E.N. and M.B. Millis, *Slipped capital femoral epiphysis: prevalence, pathogenesis, and natural history*. (1528-1132 (Electronic)).
3. Peck, D.M., L.M. Voss, and T.T. Voss, *Slipped Capital Femoral Epiphysis: Diagnosis and Management*. (1532-0650 (Electronic)).
4. Ebert, N., et al., *Outcome of the modified Dunn procedure in severe chronic or acute on chronic slipped capital femoral epiphysis*. *Journal of orthopaedic surgery and research*, 2019. **14**(1): p. 349-349.
5. Georgiadis, A.G. and I. Zaltz, *Slipped capital femoral epiphysis: how to evaluate with a review and update of treatment*. (1557-8240 (Electronic)).
6. Gautier, E.A.-O., C.A.-O. Passaplan, and L.A.-O. Gautier, *Epiphyseal Angulation and Related Spatial Orientation in Slipped Capital Femoral Epiphysis: Theoretical Model and Biomechanical Explanation of Varus and Valgus Slip*. *LID - 10.2106/JBJS.OA.20.00099 [doi] LID - e20.00099*. (2472-7245 (Electronic)).
7. Passaplan, C., L. Gautier, and E. Gautier, *Long-term follow-up of patients undergoing the modified Dunn procedure for slipped capital femoral epiphysis*. (2633-1462 (Electronic)).
8. Davis, R.L.I., et al., *Treatment of Unstable Versus Stable Slipped Capital Femoral Epiphysis Using the Modified Dunn Procedure*. *Journal of Pediatric Orthopaedics*, 2019. **39**(8): p. 411-415.
9. Ziebarth, K., et al., *Capital realignment for moderate and severe SCFE using a modified Dunn procedure*. (1528-1132 (Electronic)).
10. Tibor, L.M. and E.L. Sink, *Risks and benefits of the modified Dunn approach for treatment of moderate or severe slipped capital femoral epiphysis*. (1539-2570 (Electronic)).

11. Boyer Dw Fau - Mickelson, M.R., I.V. Mickelson Mr Fau - Ponseti, and I.V. Ponseti, *Slipped capital femoral epiphysis. Long-term follow-up study of one hundred and twenty-one patients.* (0021-9355 (Print)).
12. Carney, B.T., J. Weinstein Sl Fau - Noble, and J. Noble, *Long-term follow-up of slipped capital femoral epiphysis.* (0021-9355 (Print)).
13. Dunn, D.M., *THE TREATMENT OF ADOLESCENT SLIPPING OF THE UPPER FEMORAL EPIPHYSIS.* The Journal of Bone and Joint Surgery. British volume, 1964. **46-B**(4): p. 621-629.
14. Kramer Wg Fau - Craig, W.A., S. Craig Wa Fau - Noel, and S. Noel, *Compensating osteotomy at the base of the femoral neck for slipped capital femoral epiphysis.* (0021-9355 (Print)).
15. Southwick, W.O., *Osteotomy through the lesser trochanter for slipped capital femoral epiphysis.* (0021-9355 (Print)).
16. Ballmer, P.M., et al., *[Results following sub-capital and Imhäuser-Weber osteotomy in femur head epiphyseolysis].* (0044-3220 (Print)).
17. Agashe, M.V., D.A. Pinto, and S. Vaidya, *Modified Dunn Osteotomy for Moderate and Severe Slipped Capital Femoral Epiphysis - A retrospective study of thirty hips.* (0019-5413 (Print)).
18. Velasco, R., G.U. Schai Pa Fau - Exner, and G.U. Exner, *Slipped capital femoral epiphysis: a long-term follow-up study after open reduction of the femoral head combined with subcapital wedge resection.* (1060-152X (Print)).
19. Jerne, R., et al., *Long-term results after realignment operations for slipped upper femoral epiphysis.* (0301-620X (Print)).
20. Lykissas, M.G. and J.J. McCarthy, *Should all unstable slipped capital femoral epiphysis be treated open?* (1539-2570 (Electronic)).

21. Abu Amara, S., *Traitement chirurgical de l'épiphysiolyse fémorale supérieure de l'adolescent: Surgery of slipped capital femoral epiphysis in adolescents*, in *Conférences D'enseignement 2013*, D. Hutten, Editor. 2013, Elsevier Masson: Paris. p. 207-219.
22. Peck, K. and J. Herrera-Soto, *Slipped capital femoral epiphysis: what's new?* (1558-1373 (Electronic)).
23. Rahm, S., et al., *Mid-term results after in situ pinning and hip arthroscopy for mild slipped capital femoral epiphysis: a minimum five-year follow-up*. *Journal of children's orthopaedics*, 2020. **14**(6): p. 521-528.
24. Bond, E.C., et al., *Long-term hip function in slipped capital femoral epiphysis treated with in situ pinning*. (2309-4990 (Electronic)).
25. Accadbled, F., et al., *In situ pinning in slipped capital femoral epiphysis: long-term follow-up studies*. (1863-2521 (Print)).
26. Slongo, T., et al., *Treatment of slipped capital femoral epiphysis with a modified Dunn procedure*. (1535-1386 (Electronic)).
27. Huber, H., et al., *Adolescent slipped capital femoral epiphysis treated by a modified Dunn osteotomy with surgical hip dislocation*. (2044-5377 (Electronic)).
28. Azegami, S., M. Kosuge D Fau - Ramachandran, and M. Ramachandran, *Surgical treatment of femoroacetabular impingement in patients with slipped capital femoral epiphysis: A review of current surgical techniques*. (2049-4408 (Electronic)).
29. Novais, E.N., et al., *Modified Dunn Procedure is Superior to In Situ Pinning for Short-term Clinical and Radiographic Improvement in Severe Stable SCFE*. (1528-1132 (Electronic)).
30. Carlouz, H., et al., *Treatment of Slipped Upper Femoral Epiphysis: 80 Cases Operated on over 10 Years (1968–1978)*. *Journal of Pediatric Orthopaedics*, 1984. **4**(2).

31. Abdelazeem, A.H., et al., *The anatomical reduction of a moderate or severe stable slipped capital femoral epiphysis by modified Dunn subcapital osteotomy using the Ganz approach: functional and radiological outcomes*. Bone Joint J 2018(2049-4408 (Electronic)).
32. Dunn Dm Fau - Angel, J.C. and J.C. Angel, *Replacement of the femoral head by open operation in severe adolescent slipping of the upper femoral epiphysis*. (0301-620X (Print)).
33. Zuo, B., et al., *Outcome of the modified Dunn procedure in severe slipped capital femoral epiphysis*. Journal of orthopaedic surgery and research, 2020. **15**(1): p. 506-506.
34. Elmarghany, M., et al., *Surgical hip dislocation in treatment of slipped capital femoral epiphysis*. (2426-8887 (Print)).
35. Sucato, D.J. and A. De La Rocha, *High-grade SCFE: The Role of Surgical Hip Dislocation and Reduction*. Journal of Pediatric Orthopaedics, 2014. **34**.
36. Tannast, M., et al., *The modified Dunn procedure for slipped capital femoral epiphysis: the Bernese experience*. Journal of Children's Orthopaedics, 2017. **11**(2): p. 138-146.
37. Fish, J.B., *Cuneiform osteotomy of the femoral neck in the treatment of slipped capital femoral epiphysis*. (0021-9355 (Print)).
38. Zaltz, I., et al., *Surgical treatment of femoroacetabular impingement: what are the limits of hip arthroscopy?* (1526-3231 (Electronic)).
39. Accadbled, F., et al., *Slipped capital femoral epiphysis management and the arthroscope*. Journal of children's orthopaedics, 2017. **11**(2): p. 128-130.
40. Dutra Roos, B., et al., *Arthroscopic Subcapital Realignment in Chronic and Stable Slipped Capital Femoral Epiphysis*. Arthroscopy Techniques, 2017. **6**(3): p. e667-e672.

41. Dobashi, E.T.e.a., *Artroscopia do quadril na epifisiólise grave. Revista Brasileira de Ortopedia [online]. v. 45, n. suppl [Acessado 22 Outubro 2021] , pp. 59-62. <https://doi.org/10.1590/S0102-36162010000700011>. 2010.*
42. Akkari, M., et al., *Trapezoidal Bony Correction of the Femoral Neck in the Treatment of Severe Acute-on-Chronic Slipped Capital Femoral Epiphysis. Arthroscopy: The Journal of Arthroscopic & Related Surgery, 2010. 26(11): p. 1489-1495.*
43. Fraitzl, C.R., et al., *Radiological evidence of femoroacetabular impingement in mild slipped capital femoral epiphysis: a mean follow-up of 14.4 years after pinning in situ. (0301-620X (Print)).*
44. Ziebarth, K., S.D. Steppacher, and K.A. Siebenrock, *[The modified Dunn procedure to treat severe slipped capital femoral epiphysis]. (1433-0431 (Electronic)).*
45. Masquijo, J.J., et al., *Treatment of Slipped Capital Femoral Epiphysis With the Modified Dunn Procedure: A Multicenter Study. Journal of Pediatric Orthopaedics, 2017. 39(2).*
46. Lawane, M., M. Belouadah, and G. Lefort, *Résultats du traitement de l'épiphysiolyse fémorale supérieure à grand déplacement selon la technique de Dunn, à propos de 25 cas. Revue de Chirurgie Orthopédique et Traumatologique, 2009. 95(8): p. 721-724.*
47. Ziebarth, K., et al., *Slipped capital femoral epiphysis: relevant pathophysiological findings with open surgery. (1528-1132 (Electronic)).*
48. Otani, T., et al., *Treatment for unstable slipped capital femoral epiphysis: Current status and future challenge in Japan. (1436-2023 (Electronic)).*
49. Madan, S.S., et al., *The treatment of severe slipped capital femoral epiphysis via the Ganz surgical dislocation and anatomical reduction: a prospective study. (2049-4408 (Electronic)).*

50. Jackson, J.B., 3rd, et al., *Restoration of Blood Flow to the Proximal Femoral Epiphysis in Unstable Slipped Capital Femoral Epiphysis by Modified Dunn Procedure: A Preliminary Angiographic and Intracranial Pressure Monitoring Study.* (1539-2570 (Electronic)).
51. Novais, E.N., et al., *Is Assessment of Femoral Head Perfusion During Modified Dunn for Unstable Slipped Capital Femoral Epiphysis an Accurate Indicator of Osteonecrosis?* (1528-1132 (Electronic)).
52. Hall, J.E., *The results of treatment of slipped femoral epiphysis.* (0301-620X (Print)).
53. Ziebarth, K., et al., *High Survivorship and Little Osteoarthritis at 10-year Followup in SCFE Patients Treated With a Modified Dunn Procedure.* (1528-1132 (Electronic)).
54. Tins, B., I. Cassar-Pullicino V Fau - McCall, and I. McCall, *Slipped upper femoral epiphysis: imaging of complications after treatment.* (0009-9260 (Print)).
55. Lerch, T.D., et al., *Patients with severe slipped capital femoral epiphysis treated by the modified Dunn procedure have low rates of avascular necrosis, good outcomes, and little osteoarthritis at long-term follow-up.* (2049-4408 (Electronic)).
56. Loder, R.T., et al., *Acute slipped capital femoral epiphysis: the importance of physeal stability.* (0021-9355 (Print)).
57. Sankar, W.N., et al., *The modified Dunn procedure for unstable slipped capital femoral epiphysis: a multicenter perspective.* (1535-1386 (Electronic)).
58. J., S.D. and P.D. A., *PAPER 047: SURGICAL DISLOCATION WITH OPEN REDUCTION AND INTERNAL FIXATION FOR UNSTABLE SLIPPED CAPITAL FEMORAL EPIPHYSIS: EARLY PROMISING RESULTS.* Orthopaedic Proceedings, 2010. **92-B**(SUPP_I): p. 10-10.
59. Davis, R.L.I., et al., *Treatment of Unstable Versus Stable Slipped Capital Femoral Epiphysis Using the Modified Dunn Procedure.* Journal of Pediatric Orthopaedics, 2017. **39**(8): p. 411-415.

60. Fernandez, F.F., O. Eberhardt, and T. Wirth, *Früh- und Spät komplikationen sowie deren Management bei der ECF*. *Der Orthopäde*, 2019(1433-0431 (Electronic)).
61. Lubicky, J.P., *Chondrolysis and avascular necrosis: complications of slipped capital femoral epiphysis*. (1060-152X (Print)).
62. Roaten, J. and D.D. Spence, *Complications Related to the Treatment of Slipped Capital Femoral Epiphysis*. (1558-1373 (Electronic)).
63. Hansson, L.I., *Osteosynthesis with the hook-pin in slipped capital femoral epiphysis*. (0001-6470 (Print)).

Serment d'Hippocrate

Au moment d'être admis à devenir membre de la profession médicale, je m'engage solennellement à consacrer ma vie au service de l'humanité.

- *Je traiterai mes maîtres avec le respect et la reconnaissance qui leur sont dus.*
- *Je pratiquerai ma profession avec conscience et dignité. La santé de mes malades sera mon premier but.*
- *Je ne trahirai pas les secrets qui me seront confiés.*
- *Je maintiendrai par tous les moyens en mon pouvoir l'honneur et les nobles traditions de la profession médicale.*
- *Les médecins seront mes frères.*
- *Aucune considération de religion, de nationalité, de race, aucune considération politique et sociale ne s'interposera entre mon devoir et mon patient.*
- *Je maintiendrai le respect de la vie humaine dès la conception.*
- *Même sous la menace, je n'userai pas de mes connaissances médicales d'une façon contraire aux lois de l'humanité.*
- *Je m'y engage librement et sur mon honneur.*

قسم أبقراط

بسم الله الرحمن الرحيم

أقسم بالله العظيم

في هذه اللحظة التي يتم فيها قبولي عضواً في المهنة الطبية أتعهد علانية:

- أنا أكرس حياتي لخدمة الإنسانية.
 - وأنا أحترم أسانذتي وأعترف لهم بالجهد العظيم الذي يستحقونه.
 - وأنا أمارس مهنتي بواجب من ضميري وشرعية في جاعلا صحة مريض هدي في الأول.
 - وأنا لا أفشي الأسرار المعهودة إلي.
 - وأنا أحافظ بكل ما لدي من وسائل على الشرف والتقاليد النبيلة لمهنة الطب.
 - وأنا أعتبر سائر الأطباء إخوة لي.
 - وأنا أقوم بواجبي نحو مرضاي بدون أي اعتبار ديني أو وطني أو عرقي أو سياسي أو اجتماعي.
 - وأنا أحافظ بكل حزم على احترام الحياة الإنسانية منذ نشأتها.
 - وأنا لا أستعمل معلوماتي الطبية بطرق يضر بحقوق الإنسان مهما لاقيت من تهديد.
 - بكل هذا أتعهد عن كامل اختيار ومقسما بشري في.
- والله على ما أقول شهيد .



المملكة المغربية
جامعة محمد الخامس بالرباط
كلية الطب والصيدلة
الرباط



جامعة محمد الخامس بالرباط
Université Mohammed V de Rabat

أطروحة رقم: 428

سنة : 2021

تقنية دان في علاج انفصال مشاش عظم الفخذ العلوي

أطروحة

قدمت ونوقشت علانية يوم : / / 2021

من طرفه

السيدة هدى بوبيدي

المزادة في 26 أكتوبر 1996 بالدار البيضاء

لنيل شهادة

دكتور في الطب

الكلمات الأساسية : انزلاق مشاش عظم الفخذ العلوي؛ تقنية دان؛ تنخر رأس الفخذ

أعضاء لجنة التحكيم:

رئيس

السيد محمد أنور دندان

أستاذ في جراحة الأطفال

مشرف

السيد عبد الواحد عمراني

أستاذ في جراحة العظام والمفاصل عند الأطفال

عضو

السيدة نعيمة الحافظي

أستاذة في طب الأطفال

عضو

السيد رشيد أبيلقاسم

أستاذ في طب الأطفال